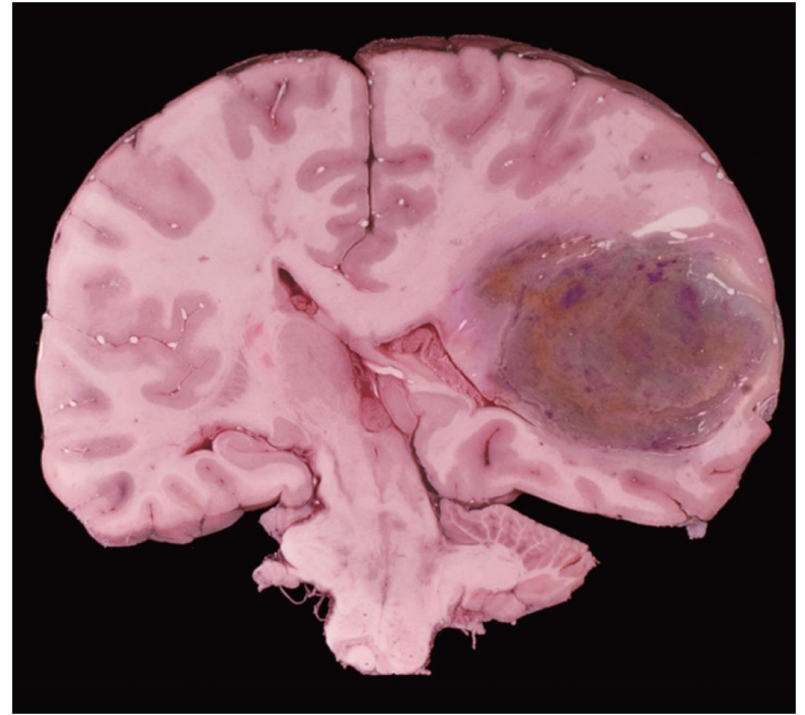


Brain II



The Hindbrain and Midbrain

Learning outcomes

By the end of this section, you will be able to:

- list the components of the hindbrain and midbrain and their functions; and
- describe the location and function of the reticular formation.

Hindbrain - Medulla Oblongata

- embryonic **myelencephalon** becomes **medulla oblongata**
- begins at **foramen magnum** of the skull
- extends for about 3 cm rostrally and ends at a groove between the medulla and pons
- slightly wider than spinal cord
- **pyramids** – pair of external ridges on anterior surface
 - resembles side-by-side baseball bats
- **olive** – a prominent bulge lateral to each pyramid
- posteriorly, **gracile** and **cuneate fasciculi** of the spinal cord continue as two pair of ridges on the medulla
- all nerve fibers connecting the brain to the spinal cord pass through the medulla
- **four pairs of cranial nerves** begin or end in medulla - IX, X, XI, XII

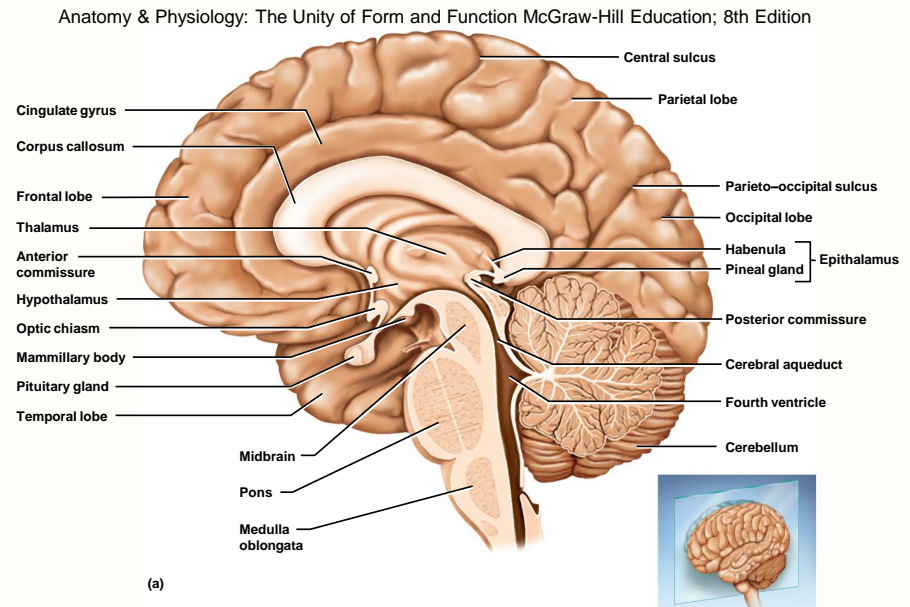


Figure 14.2a

Hindbrain - Medulla Oblongata

- **cardiac center**
 - adjusts rate and force of heart
- **vasomotor center**
 - adjusts blood vessel diameter
- **respiratory centers**
 - control rate and depth of breathing
- **reflex centers**
 - for coughing, sneezing, gagging, swallowing, vomiting, salivation, sweating, movements of tongue and head

Medulla Oblongata

Anatomy & Physiology: The Unity of Form and Function McGraw-Hill Education; 8th Edition

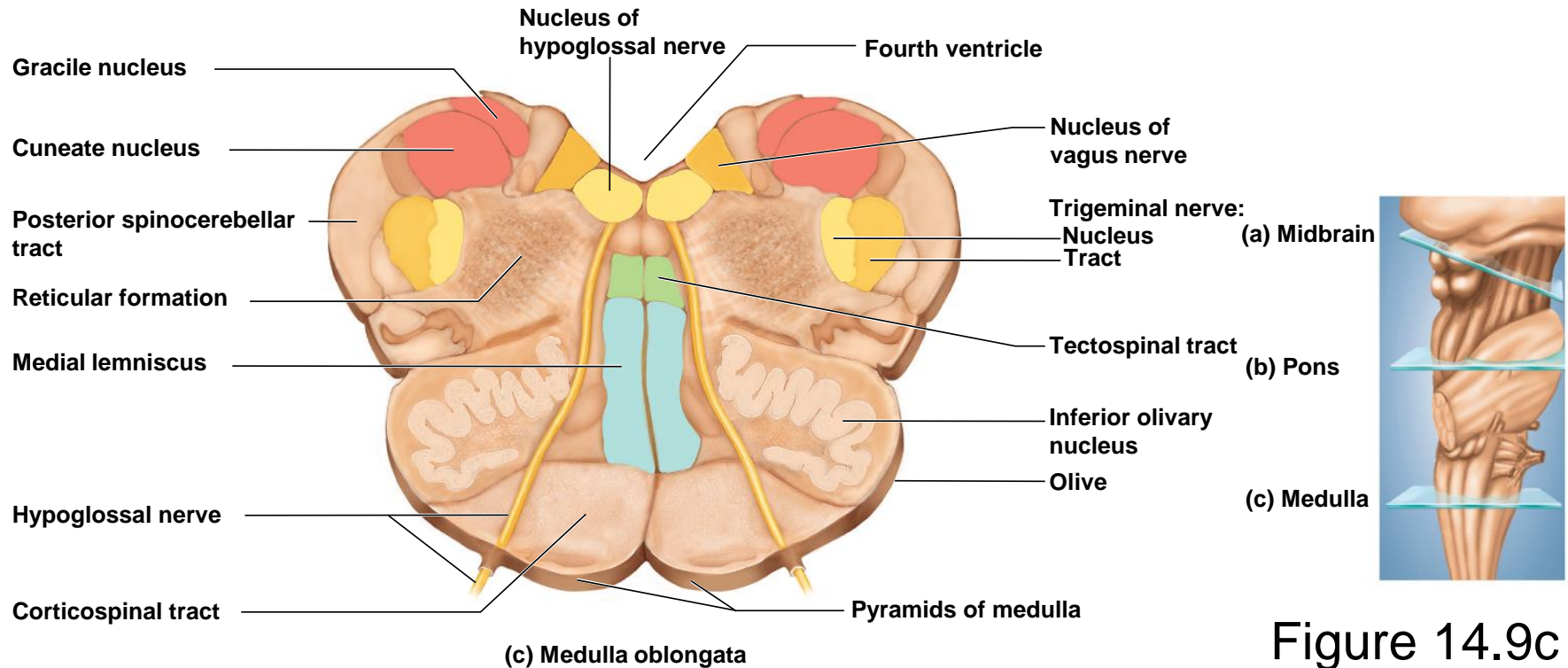
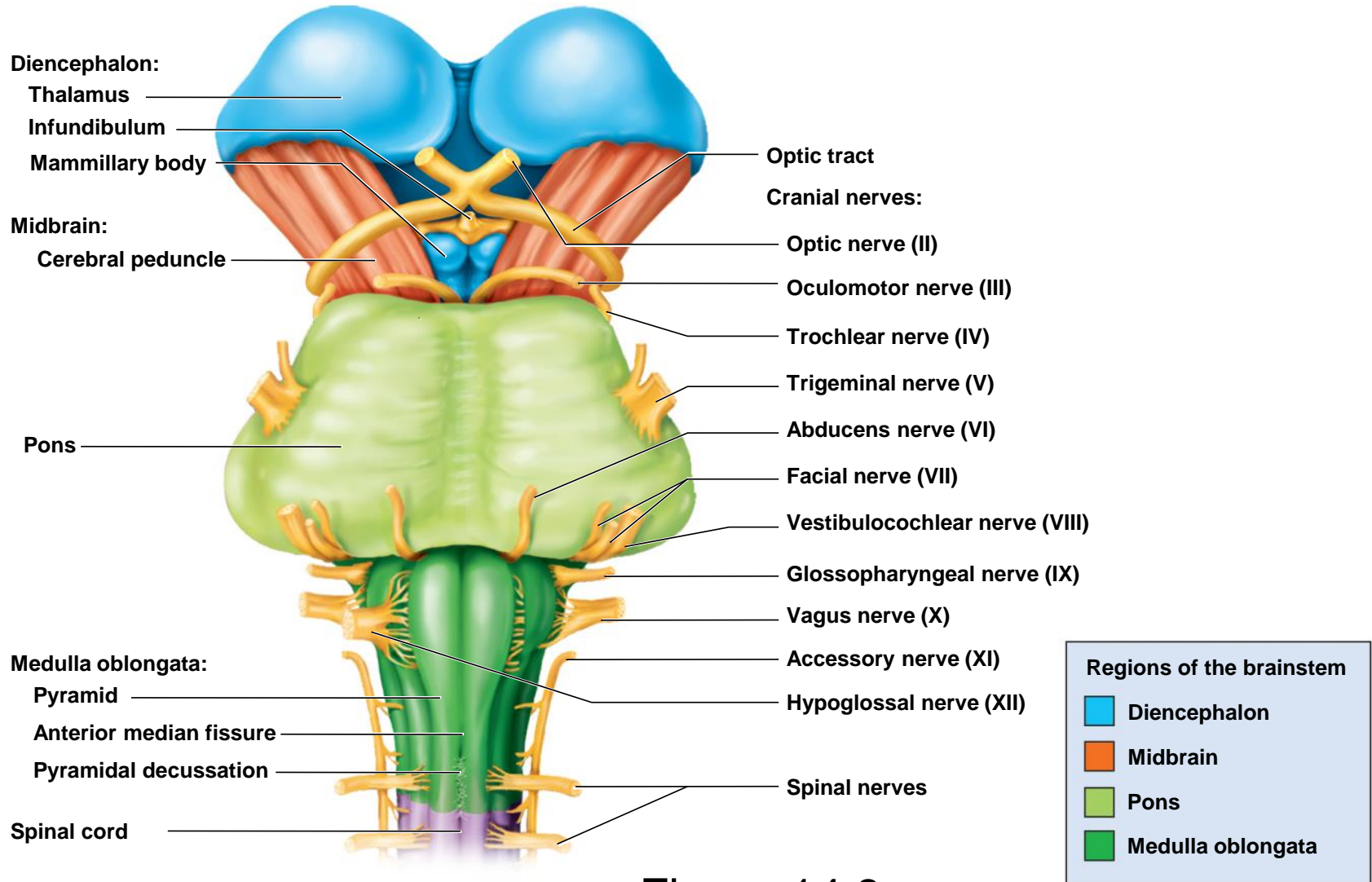


Figure 14.9c

- **pyramids** contain descending fibers called corticospinal tracts
 - carry motor signals to skeletal muscles
- **inferior olivary nucleus** – relay center for signals to cerebellum
- **reticular formation** - loose network of nuclei extending throughout the medulla, pons and midbrain
 - contains cardiac, vasomotor & respiratory centers

Medulla and Pons

Anatomy & Physiology: The Unity of Form and Function McGraw-Hill Education; 8th Edition

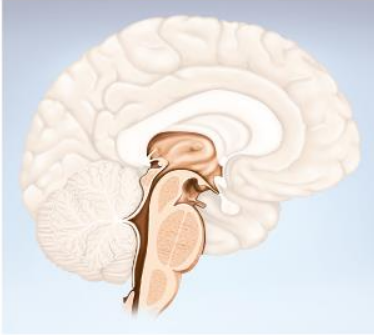

(a) Anterior view

Figure 14.8a

Posterolateral View of Brainstem

Anatomy & Physiology: The Unity of Form and Function McGraw-Hill Education; 8th Edition



Diencephalon:

Thalamus

Lateral geniculate body

Pineal gland

Medial geniculate body

Midbrain:

Superior colliculus

Inferior colliculus

Cerebral peduncle

Pons

Fourth ventricle

Medulla oblongata

Optic tract

Superior cerebellar peduncle

Middle cerebellar peduncle

Inferior cerebellar peduncle

Olive

Cuneate fasciculus

Gracile fasciculus

Spinal cord

Regions of the brainstem

Diencephalon

Midbrain

Pons

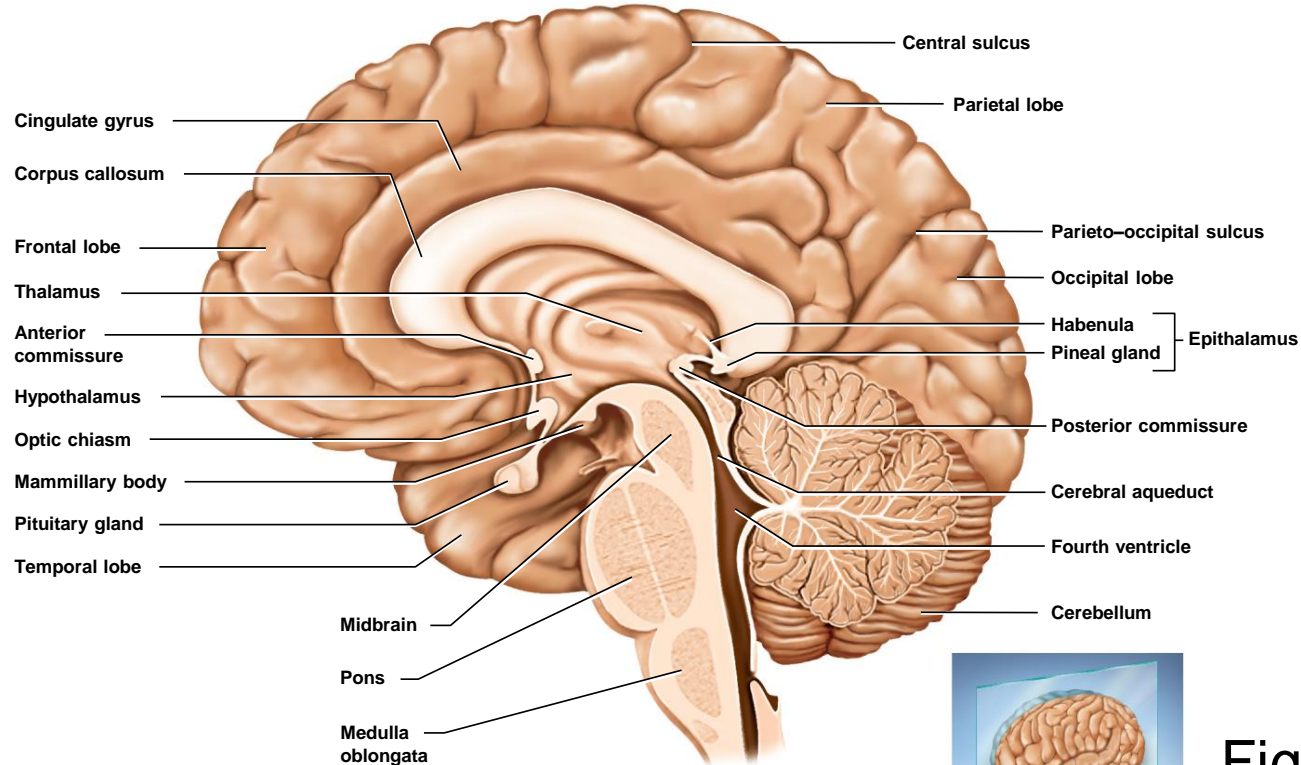
Medulla oblongata

(b) Posterolateral view

Figure 14.8b

Pons

Anatomy & Physiology: The Unity of Form and Function McGraw-Hill Education; 8th Edition



(a)

Figure 14.2a

- **metencephalon** - develops into the pons and cerebellum
- **pons** – anterior bulge in brainstem, rostral to medulla
- **cerebral peduncles** – connect cerebellum to pons and midbrain

Pons

- ascending sensory tracts
- descending motor tracts
- pathways in and out of cerebellum
- **cranial nerves V, VI, VII, and VIII**
 - **sensory roles** – hearing, equilibrium, taste, facial sensations
 - **motor roles** – eye movement, facial expressions, chewing, swallowing, urination, and secretion of saliva and tears
- **reticular formation** in pons contains additional nuclei concerned with:
 - sleep, respiration, and posture

Cross-section of Pons

Anatomy & Physiology: The Unity of Form and Function McGraw-Hill Education; 8th Edition

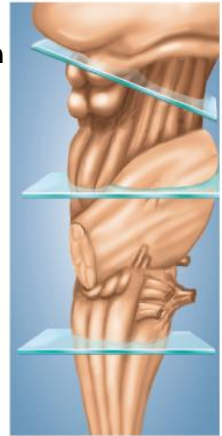
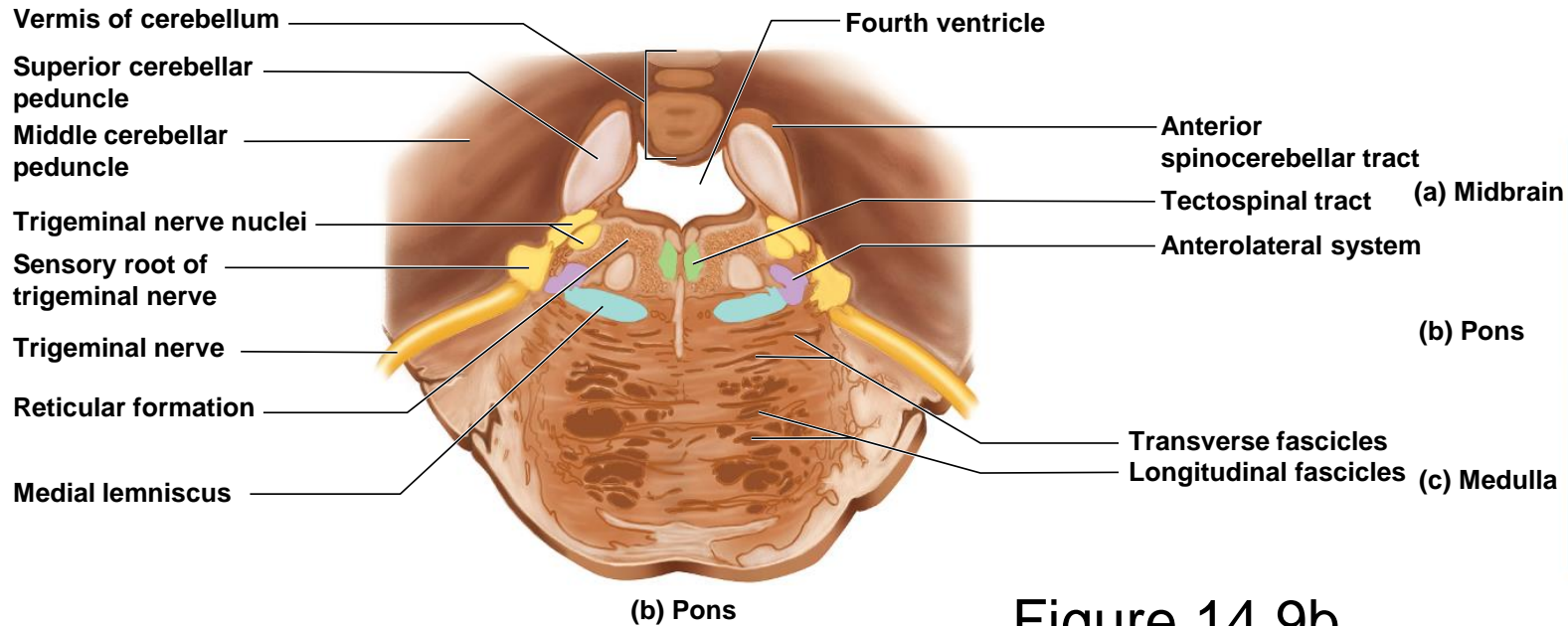


Figure 14.9b

Midbrain

- mesencephalon becomes one mature brain structure, the **midbrain**
 - short segment of brainstem that connects the hindbrain to the forebrain
 - contains **cerebral aqueduct**
 - contains continuations of the **medial lemniscus** and **reticular formation**
 - contains the motor nuclei of **two cranial nerves** that control eye movements – CN III (oculomotor) and CN IV (trochlear)
 - **tectum** – roof-like part of the midbrain posterior to cerebral aqueduct
 - exhibits four bulges, the **corpora quadrigemina**
 - upper pair, the **superior colliculi** function in visual attention, tracking moving objects, and some reflexes
 - lower pair, the **inferior colliculi** receives signals from the inner ear
 - relays them to other parts of the brain, especially the thalamus
 - **cerebral peduncles** – two stalks that anchor the cerebrum to the brainstem anterior to the cerebral aqueduct

Midbrain

- cerebral peduncles
 - each consists of **three main components**
 - tegmentum, substantia nigra, and cerebral crus
 - **tegmentum**
 - dominated by the **red nucleus**
 - pink color due to high density of blood vessels
 - connections go to and from cerebellum
 - collaborates with cerebellum for fine motor control
 - **substantia nigra**
 - **dark gray to black nucleus** pigmented with melanin
 - motor center that relays inhibitory signals to thalamus & basal nuclei preventing unwanted body movement
 - degeneration of neurons leads to tremors of Parkinson disease
 - **cerebral crus**
 - bundle of nerve fibers that connect the cerebrum to the pons
 - carries **corticospinal tracts**

Midbrain -- Cross Section

Anatomy & Physiology: The Unity of Form and Function McGraw-Hill Education; 8th Edition

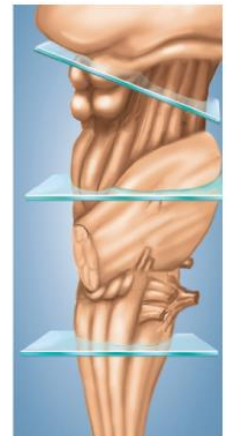
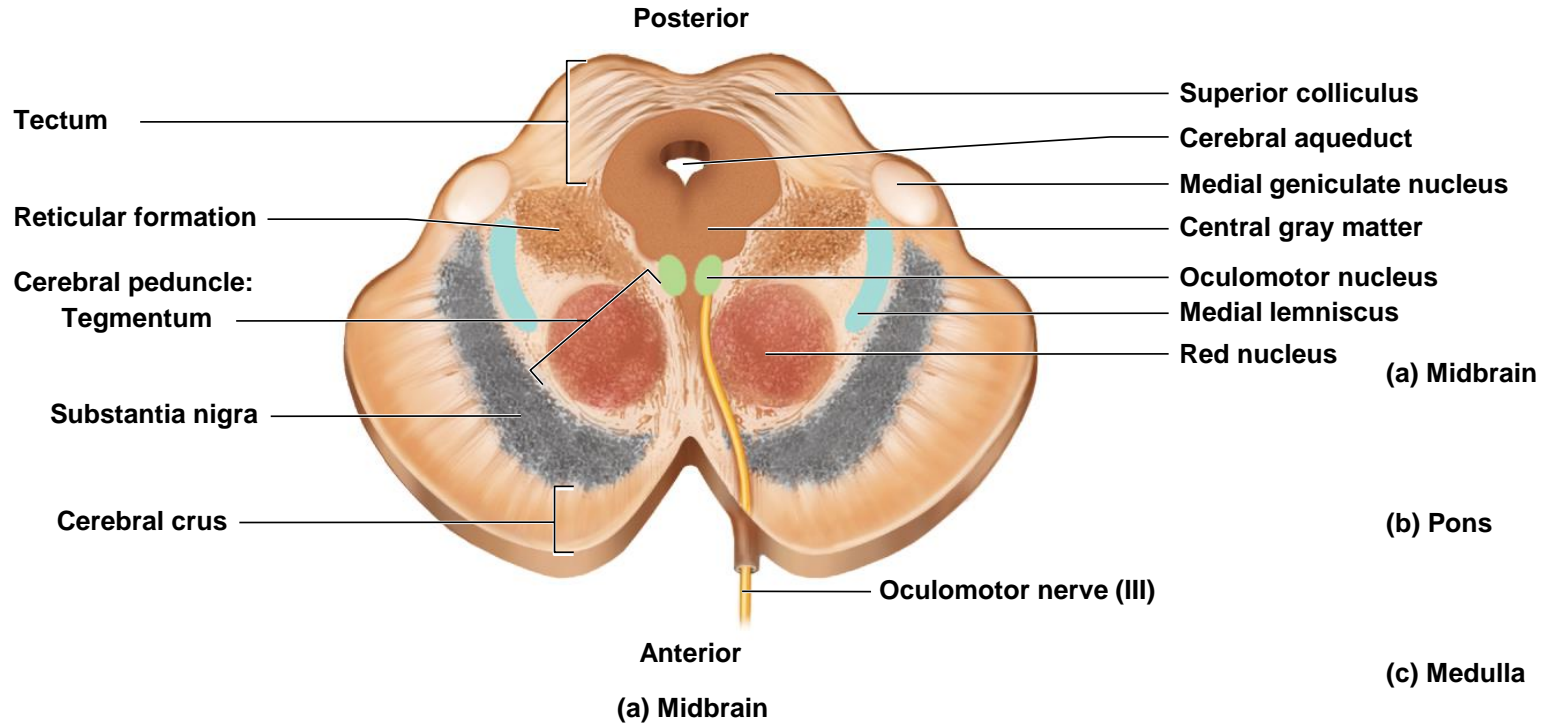


Figure 14.9a

Reticular Formation

Anatomy & Physiology: The Unity of Form and Function McGraw-Hill Education; 8th Edition

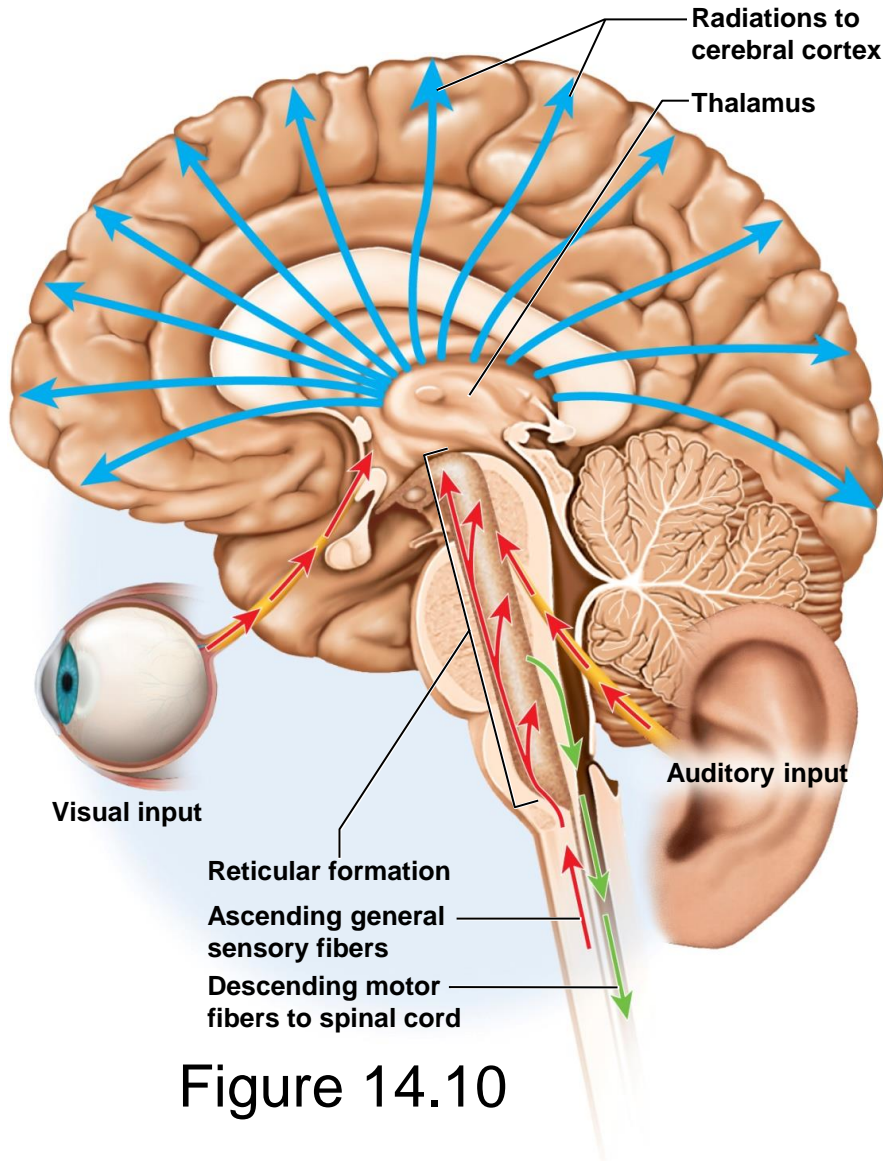


Figure 14.10

- **reticular formation** – loosely organized web of gray matter that runs vertically through all levels of the brainstem
- clusters of gray matter scattered throughout pons, midbrain and medulla
- occupies space between white fiber tracts and brainstem nuclei
- has connections with many areas of cerebrum
- more than 100 small neural networks without distinct boundaries

Functions of Reticular Formation Networks

- **somatic motor control**
 - adjust muscle tension to maintain tone, balance, and posture
 - especially during body movements
 - relays signals from eyes and ears to the cerebellum
 - integrates visual, auditory, and balance and motion stimuli into motor coordination
 - **gaze center** – allow eyes to track and fixate on objects
 - **central pattern generators** – neural pools that produce rhythmic signals to the muscles of breathing and swallowing
- **cardiovascular control**
 - includes cardiac and vasomotor centers of medulla oblongata
- **pain modulation**
 - one route by which pain signals from the lower body reach the cerebral cortex
 - origin of descending analgesic pathways – fibers act in the spinal cord to block transmission of pain signals to the brain
- **sleep and consciousness**
 - plays central role in states of consciousness, such as alertness and sleep
 - injury to reticular formation can result in irreversible coma
- **habituation**
 - process in which the brain learns to ignore repetitive, inconsequential stimuli while remaining sensitive to others

Cerebellum

Anatomy & Physiology: The Unity of Form and Function McGraw-Hill Education; 8th Edition

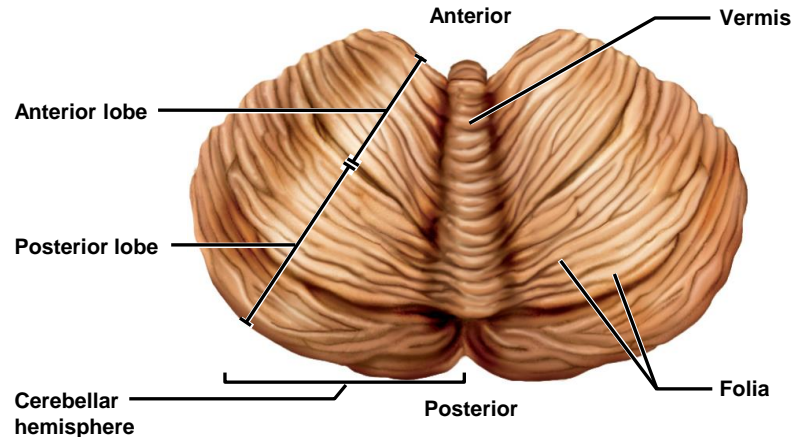


Figure 14.11b

(b) Superior view

- the largest part of the hindbrain and the second largest part of the brain as a whole
- consists of right and left cerebellar hemispheres connected by **vermis**
- cortex of gray matter with folds (**folia**) and four deep nuclei in each hemisphere
- contains more than half of all brain neurons, about 100 billion
 - **granule cells** and **Purkinje cells** synapse on deep nuclei
- white matter branching pattern is called **arbor vitae**

Cerebellum

Copyright © The McGraw-Hill Companies, Inc. Permission required for reproduction or display.

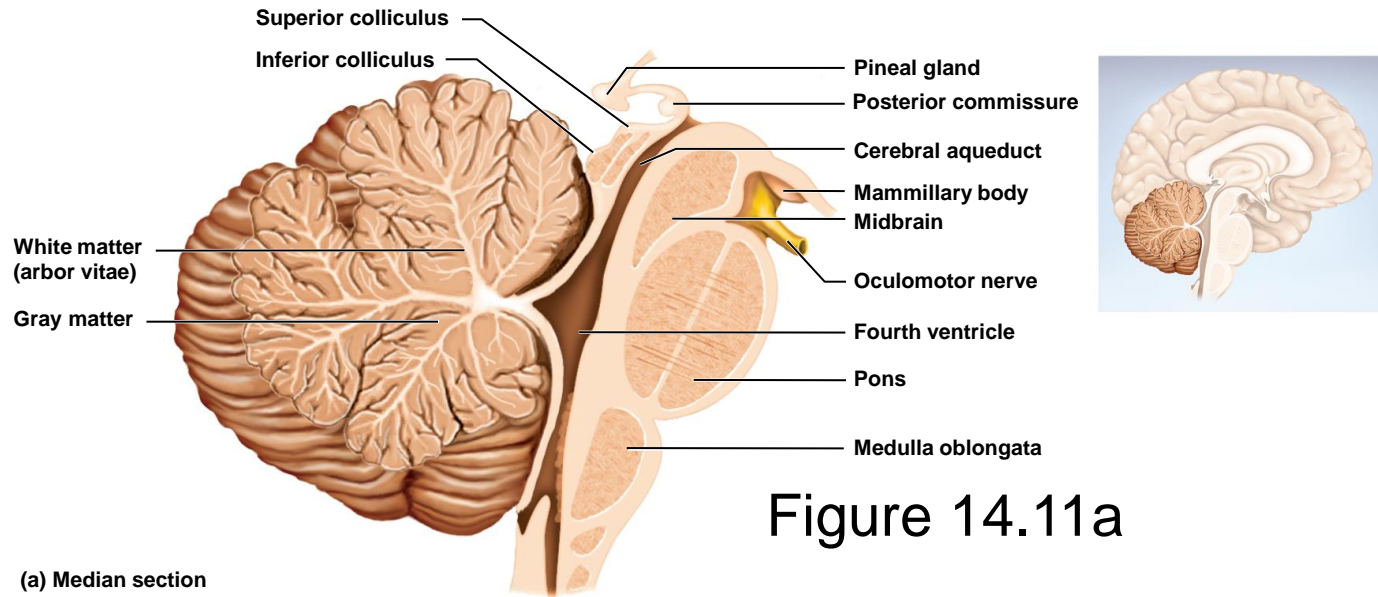


Figure 14.11a

- **cerebellar peduncles** – three pairs of stalks that connect the cerebellum to the brainstem
 - **inferior peduncles** – connected to medulla oblongata
 - most spinal input enters the cerebellum through inferior peduncle
 - **middle peduncles** – connected to the pons
 - most input from the rest of the brain enters by way of middle peduncle
 - **superior peduncles** – connected to the midbrain
 - carries cerebellar output
- consist of thick bundles of nerve fibers that carry signals to and from the cerebellum

Cerebellar Functions

- monitors muscle contractions and aids in motor coordination
- evaluation of sensory input
 - comparing textures without looking at them
 - spatial perception and comprehension of different views of 3D objects belonging to the same object
- timekeeping center
 - predicting movement of objects
 - helps predict how much the eyes must move in order to compensate for head movements and remain fixed on an object
- hearing
 - distinguish pitch and similar sounding words
- planning and scheduling tasks
- lesions may result in emotional overreactions and trouble with impulse control

INTEGRATIVE FUNCTIONS OF THE BRAIN



higher brain functions

- Sleep
- Memory
- Cognition
- Emotion
- Sensation
- Motor control
- Language.

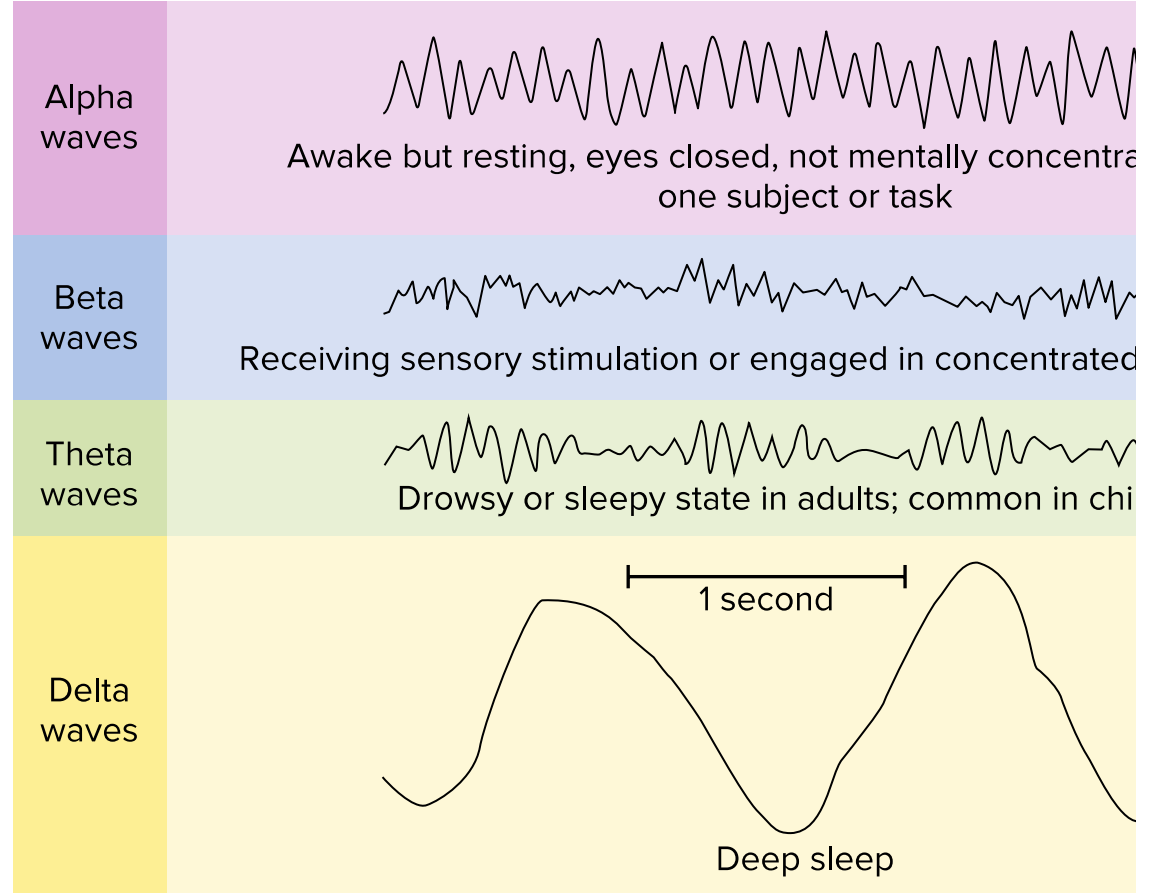
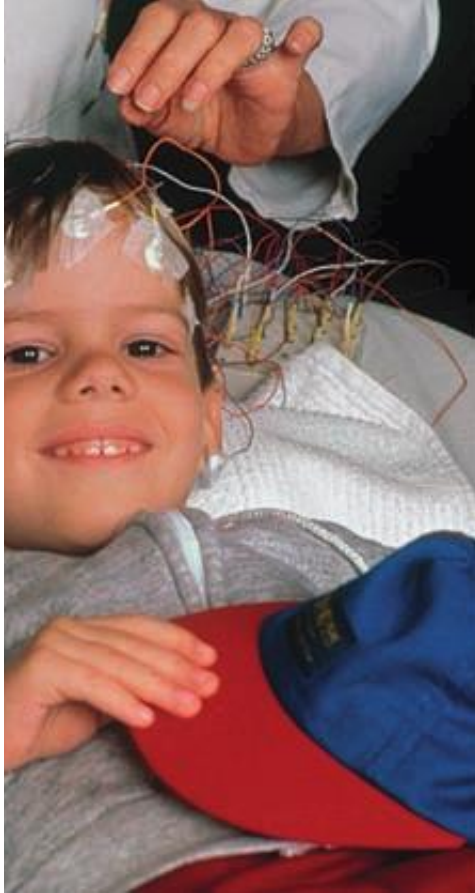The Electroencephalogram

EEG

For research and clinical purposes, it is common to monitor electrical activity called **brain waves**. Recorded with electrodes on the scalp, these are rhythmic voltage changes resulting predominantly from synchronized postsynaptic potentials (not action potentials) in the superficial layers of the cerebral cortex. The recording, called an **electroencephalogram (EEG)**, is useful in studying normal brain functions such as sleep and consciousness, and in diagnosing degenerative brain diseases, metabolic abnormalities, brain tumors, trauma, and so forth.

The Electroencephalogram

EEG



Brain waves

- **Alpha(α)waves** have a frequency of 8 to 13 Hz and are recorded especially in the parieto-occipital area. They dominate the EEG when a person is awake and resting, with the eyes closed and the mind wandering. They are suppressed when a person opens the eyes, receives specific sensory stimulation, or engages in a mental task such as performing mathematical calculations. They are absent during deep sleep.
- **Beta (β) waves** have a frequency of 14 to 30 Hz and occur in the frontal to parietal region. They are accentuated during mental activity and sensory stimulation.

Brain waves

- **Theta (θ) waves** have a frequency of 4 to 7 Hz. They are normal in children and in drowsy or sleeping adults, but a predominance of theta waves in awake adults suggests emotional stress or brain disorders.
- **Delta (δ) waves** are high-amplitude “slow waves” with a frequency of less than 3.5 Hz. Infants exhibit delta waves when awake, and adults exhibit them in deep sleep. A predominance of delta waves in awake adults indicates serious brain damage.

Sleep

Sleep can be defined as a temporary state of unconsciousness from which (in contrast to coma) one can awaken when stimulated. It is one of many bodily functions that occur in cycles called circadian rhythms, so named because they are marked by events that reoccur at intervals of about 24 hours.

Sleep occurs in distinct stages recognizable from changes in the EEG. In the first 30 to 45 minutes, the EEG waves drop in frequency but increase in amplitude as one passes through four sleep stages

Sleep

- **Stage 1.** One feels drowsy, closes the eyes, and begins to relax. Thoughts come and go, often accompanied by a drifting sensation. One awakens easily if stimulated. The EEG is dominated by alpha waves.
- **Stage 2.** One passes into light sleep. The EEG declines in frequency but increases in amplitude. Occasionally it exhibits 1 or 2 seconds of *sleep spindles*, high spikes resulting from interactions between neurons of the thalamus and cerebral cortex.

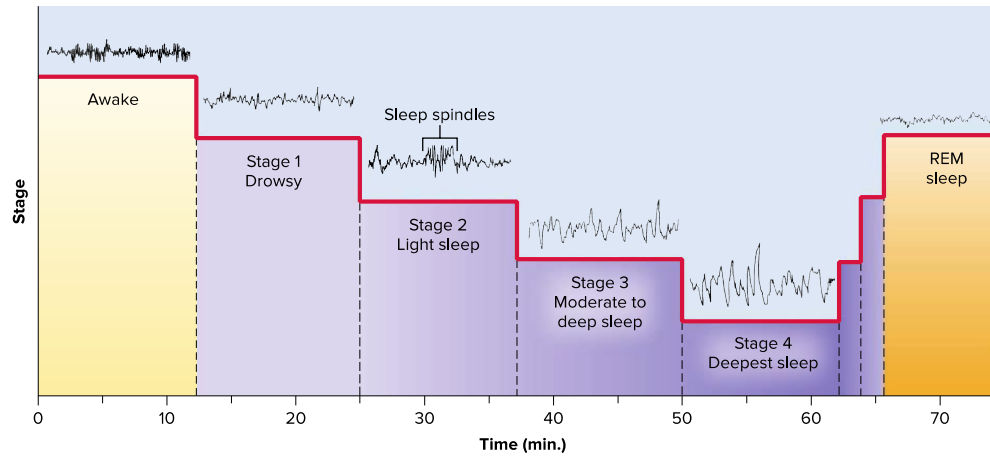
Sleep

- **Stage 3.** This is moderate to deep sleep, typically beginning about 20 minutes after stage 1. Sleep spindles occur less often, and theta and delta waves appear. The muscles relax, and the *vital signs* (body temperature, blood pressure, and heart and respiratory rates) fall.
- **Stage 4.** This is also called *slow-wave sleep (SWS)*, because the EEG is dominated by low-frequency, high-amplitude delta waves. The muscles are now very relaxed, vital signs are at their lowest levels, and one becomes difficult to awaken.

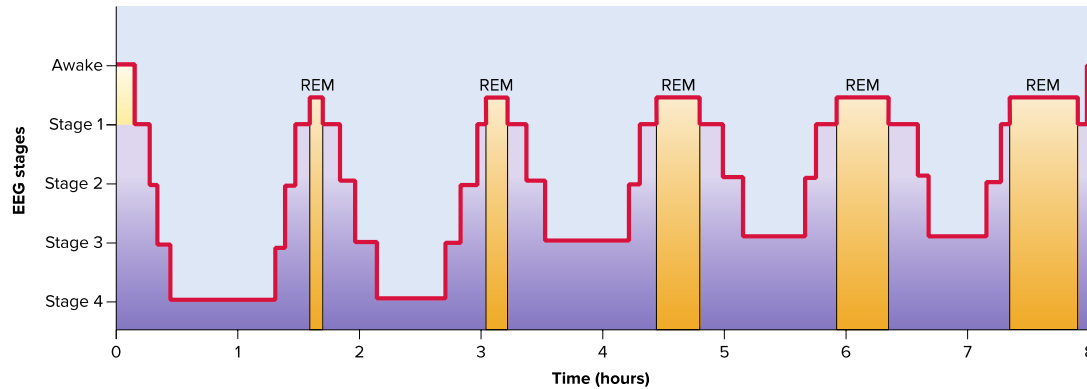
Sleep

About five times a night, a sleeper backtracks from stage 3 or 4 to stage 2 and exhibits bouts of rapid eye movement (REM) sleep. This is so named because the eyes oscillate back and forth as if watching a movie. It is also called paradoxical sleep because the EEG resembles the waking state, yet the sleeper is harder to arouse than in any other stage. The vital signs increase and the brain consumes even more oxygen than when awake. Sleep paralysis, other than in the muscles of eye movement, is especially strong during REM sleep. Sleep paralysis usually prevents the sleeper from acting out his or her dreams.

Sleep Stages and Brain Activity.



(a) One sleep cycle



(b) Typical 8-hour sleep period

Cognition



the range of mental processes by which we acquire and use knowledge-sensory perception, thought, reasoning, judgment, memory, imagination, and intuition. Such functions are widely distributed over regions of cerebral cortex called association areas, which constitute about 75% of all brain tissue. This is the most difficult area of brain research and the most incompletely understood aspect of cerebral function.

Memory

The hippocampus of the limbic system is an important memory-forming center. It does not store memories, but organizes sensory and cognitive experiences into a unified long-term memory. The hippocampus learns from sensory input while an experience is happening, but it has a short memory. Later, perhaps when one is sleeping, it plays this memory repeatedly to the cerebral cortex, which is a “slow learner” but forms longer-lasting memories. This process of “teaching the cerebral cortex” until a long-term memory is established is called memory consolidation. Long-term memories are held in various areas of cortex. One’s vocabulary and memory of faces and familiar objects, for example, reside in the superior temporal lobe, and memories of one’s plans and social roles are in the prefrontal cortex.

Emotion

Emotional feelings and memories are not exclusively cerebral functions, but result from an interaction between areas of the prefrontal cortex and diencephalon.

But the feelings themselves, and emotional memories, arise from deeper regions of the brain, especially the hypothalamus and amygdala. Here lie the nuclei that stimulate us to recoil in fear from a rattlesnake or yearn for a lost love.

The amygdala is a major component of the limbic system described earlier. It receives processed information from the general senses and from vision, hearing, taste, and smell.

Sensation

- **The Special Senses** are limited to the head, and some employ relatively complex sense organs. They are vision, hearing, equilibrium, taste, and smell.
- **The General Senses** are distributed over the entire body and employ relatively simple receptors. They include such senses as touch, pressure, stretch, movement, heat, cold, and pain.

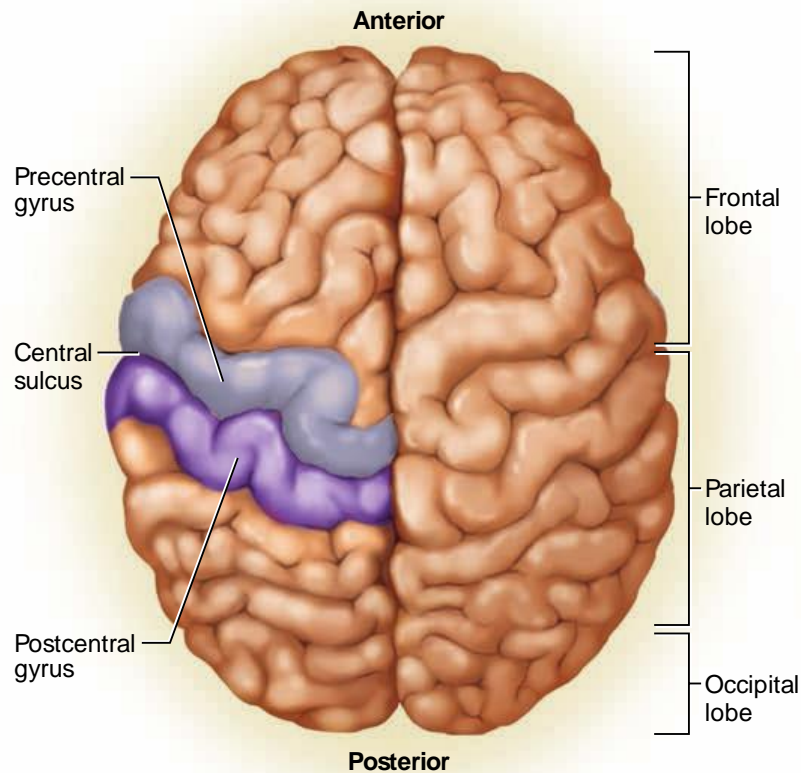
The Special Senses

- **Vision.** Visual signals are received by the **primary visual cortex** in the far posterior region of the occipital lobe. This is bordered anteriorly by the **visual association area**, which includes all the remainder of the occipital lobe, some of the posterior parietal lobe (concerned with spatial perception), and much of the inferior temporal lobe, where we recognize faces and other familiar objects.
- **Hearing.** Auditory signals are received by the **primary auditory cortex** in the superior region of the temporal lobe and in the nearby insula. The **auditory association area** occupies areas of temporal lobe inferior to the primary auditory cortex and deep within the lateral sulcus. This is where we become capable of recognizing spoken words, a familiar piece of music, or a voice on the telephone.

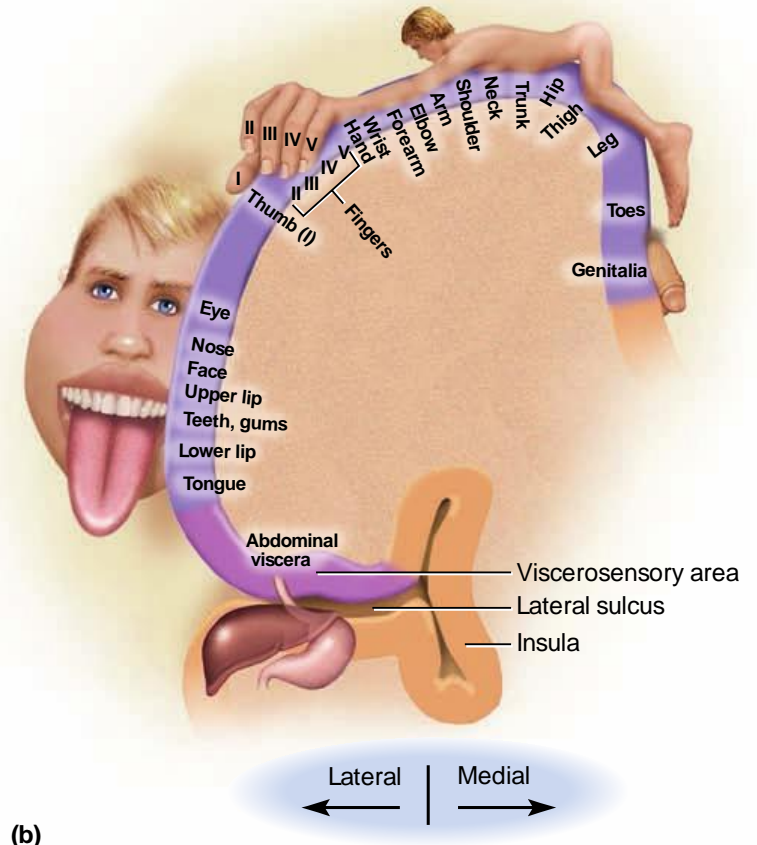
The Special Senses

- **Equilibrium.** Signals from the inner ear for equilibrium project mainly to the cerebellum and several brainstem nuclei concerned with head and eye movements and visceral functions. Some fibers of this system, however, are routed through the thalamus to areas of association cortex in the roof of the lateral sulcus and near the lower end of the central sulcus. This is the seat of consciousness of our body movements and orientation in space.
- **Taste and smell.** Gustatory (taste) signals are received by the **primary gustatory cortex** in the inferior end of the postcentral gyrus of the parietal lobe (discussed shortly) and an anterior region of the insula. Olfactory (smell) signals are received by the **primary olfactory cortex** in the medial surface of the temporal lobe and inferior surface of the frontal lobe. The *orbitofrontal cortex* mentioned earlier serves as a multimodal association area for both taste and smell, and is thus highly important in our enjoyment or rejection of various foods and drinks.

The General Senses



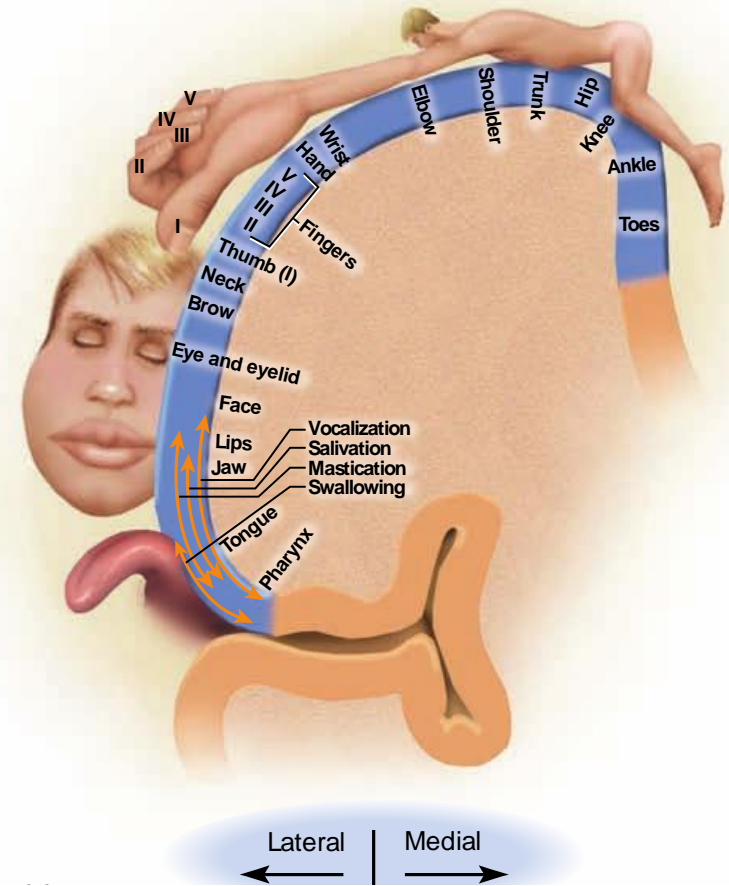
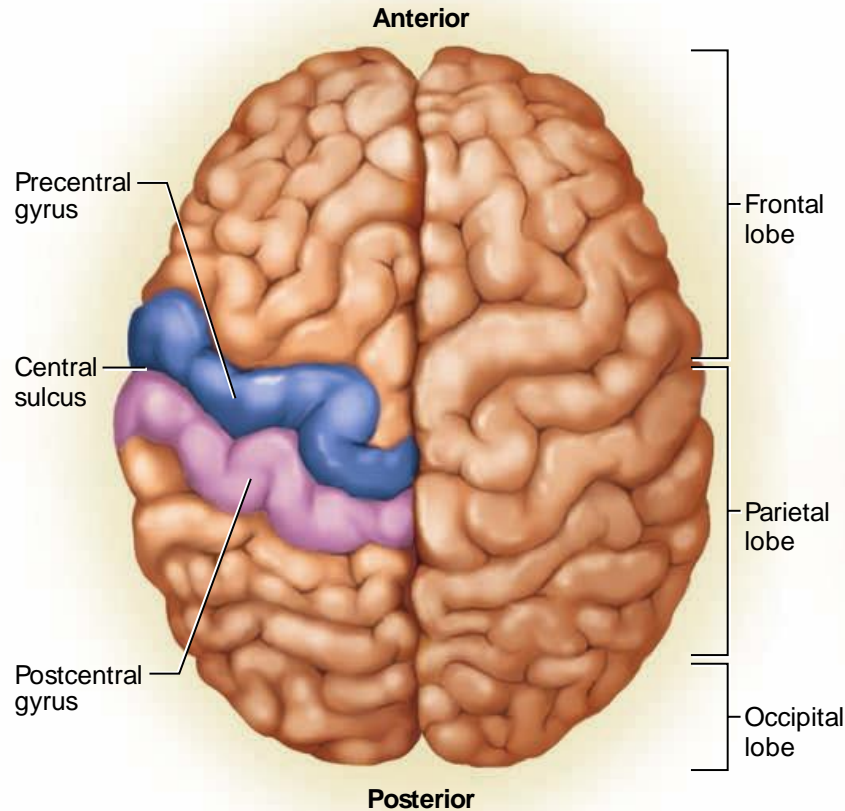
(a)



(b)

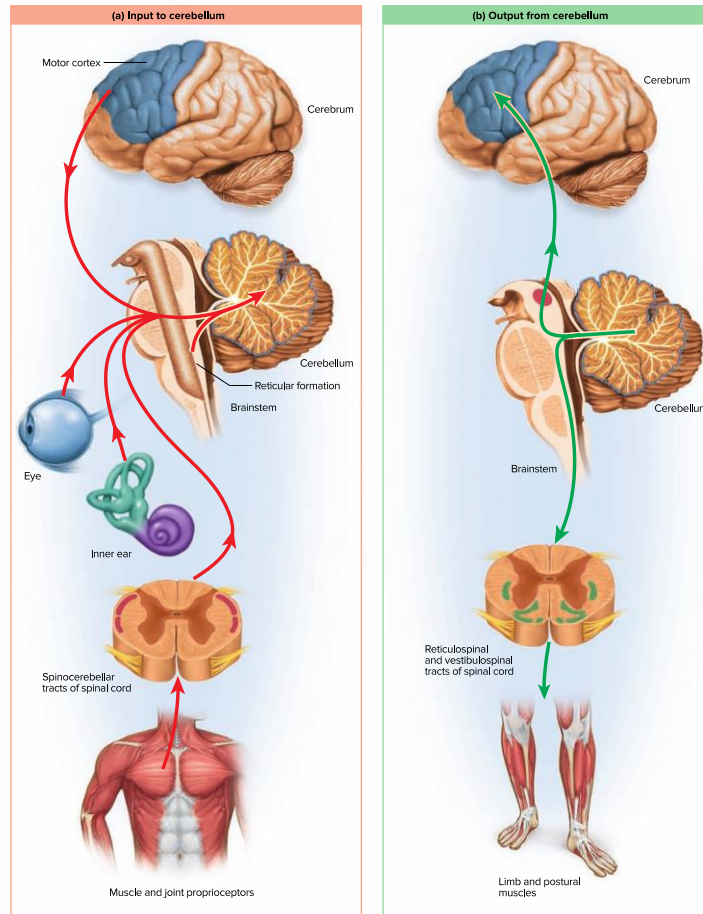
Motor Control

The Primary Motor Cortex (Precentral Gyrus).



Motor Control

Motor Pathways Involving the Cerebellum. .



Language



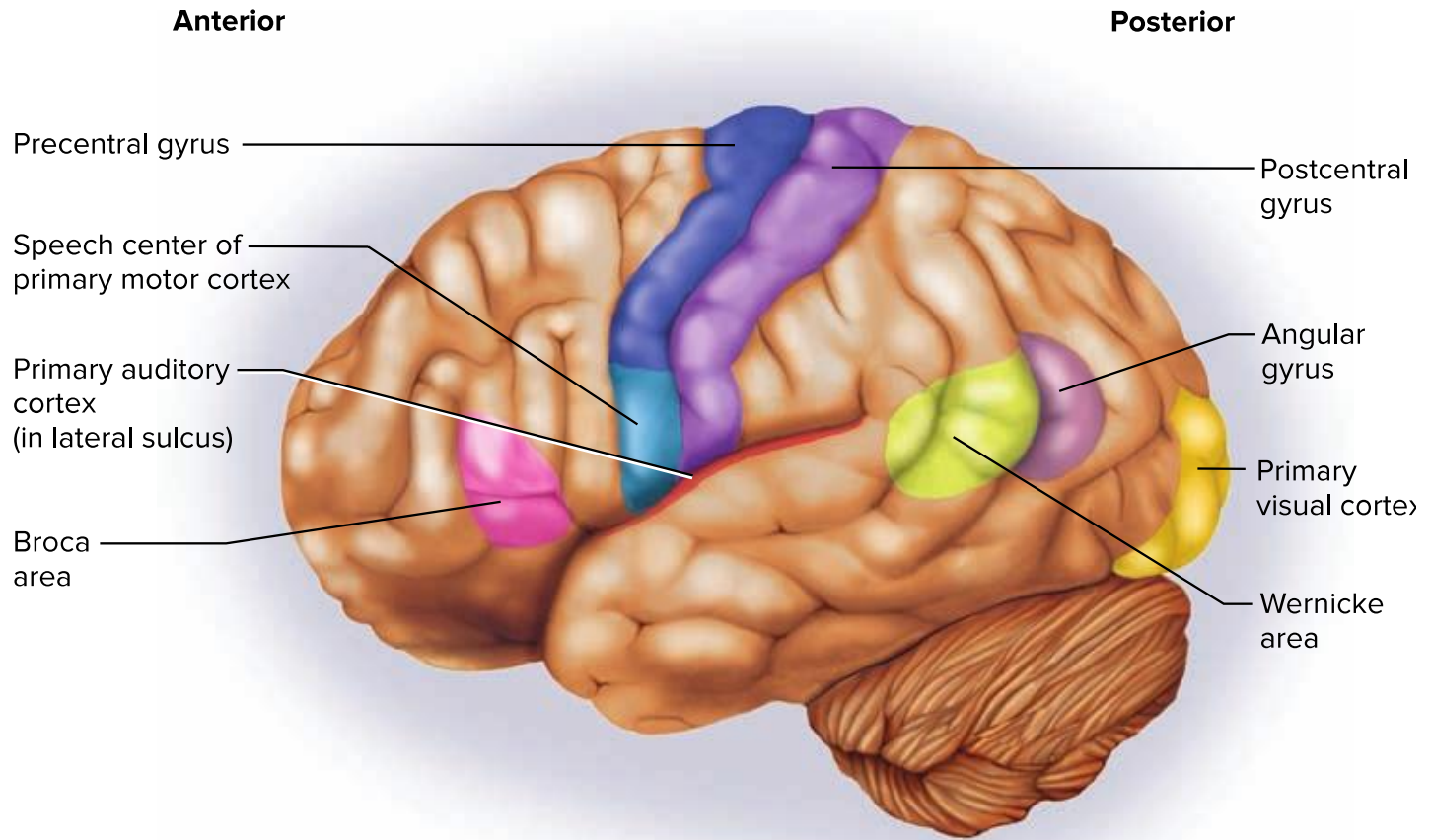
Language includes several abilities - reading, writing, speaking, sign language, and understanding words - assigned to different regions of cerebral cortex

Language

- **The Wernicke area** is responsible for the recognition of spoken and written language. It lies just posterior to the lateral sulcus, usually in the left hemisphere, at the crossroad between visual, auditory, and somatosensory areas of cortex, receiving input from all these neighboring regions.
- **The Broca area**, located in the inferior prefrontal cortex of the same hemisphere. PET scans show a rise in the metabolic activity of the Broca area as one prepares to speak or sign. This area generates a motor program for the muscles of the larynx, tongue, cheeks, and lips to produce speech, as well as for the hand motions of signing. It transmits this program to the primary motor cortex, which executes it-that is, it issues commands to the lower motor neurons that supply the relevant muscles.

Language

Language Centers of the Left Hemisphere.

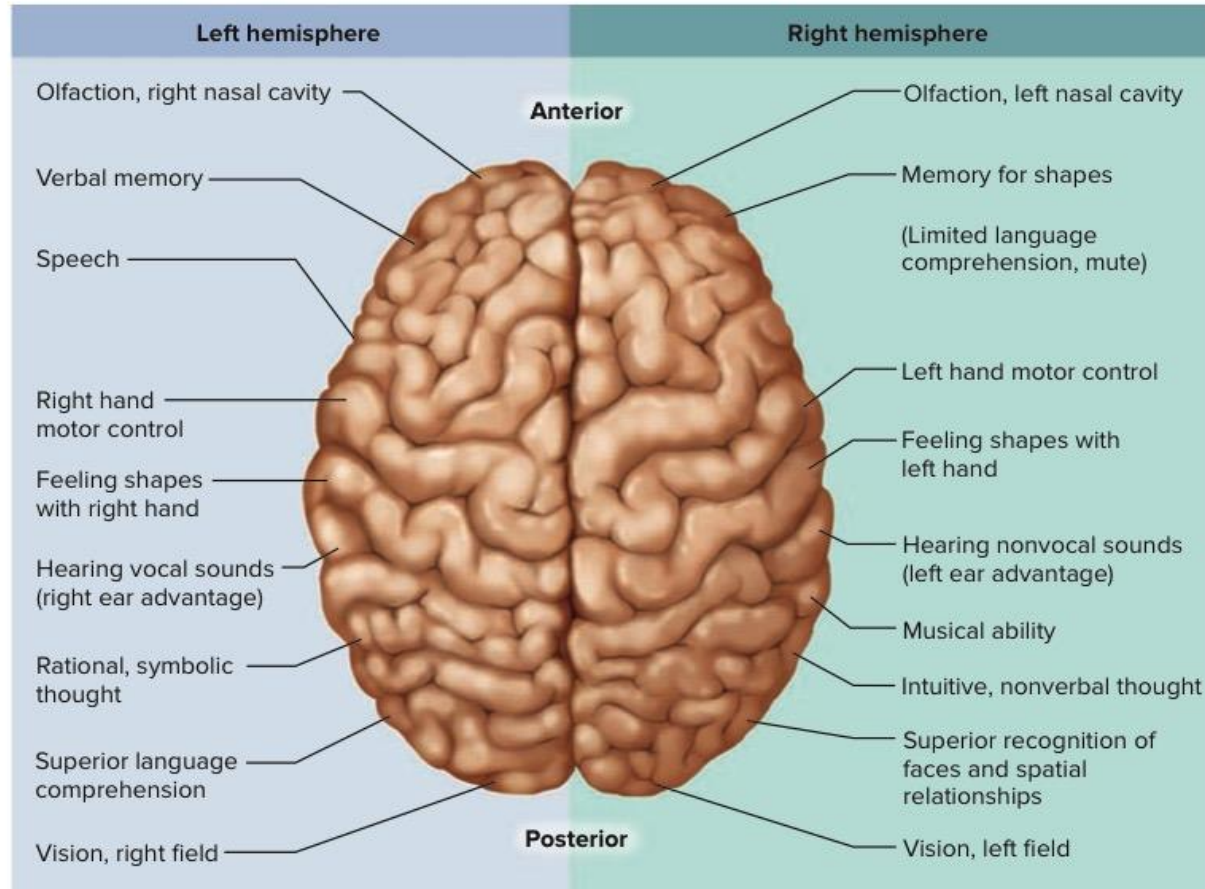


Language

Aphasia is any language deficit resulting from lesions in the hemisphere (usually the left) containing the Wernicke and Broca areas.

- Nonfluent (Broca) aphasia
- Fluent (Wernicke) aphasia

Cerebral Lateralization



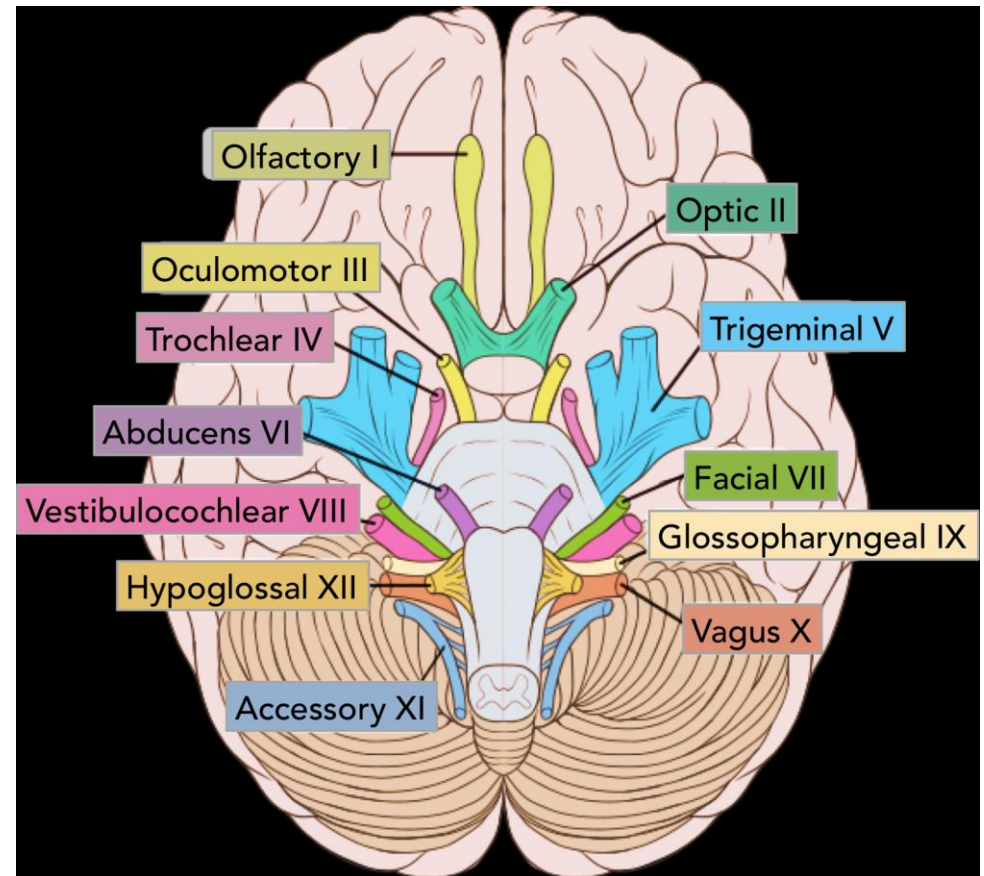


Thank You!



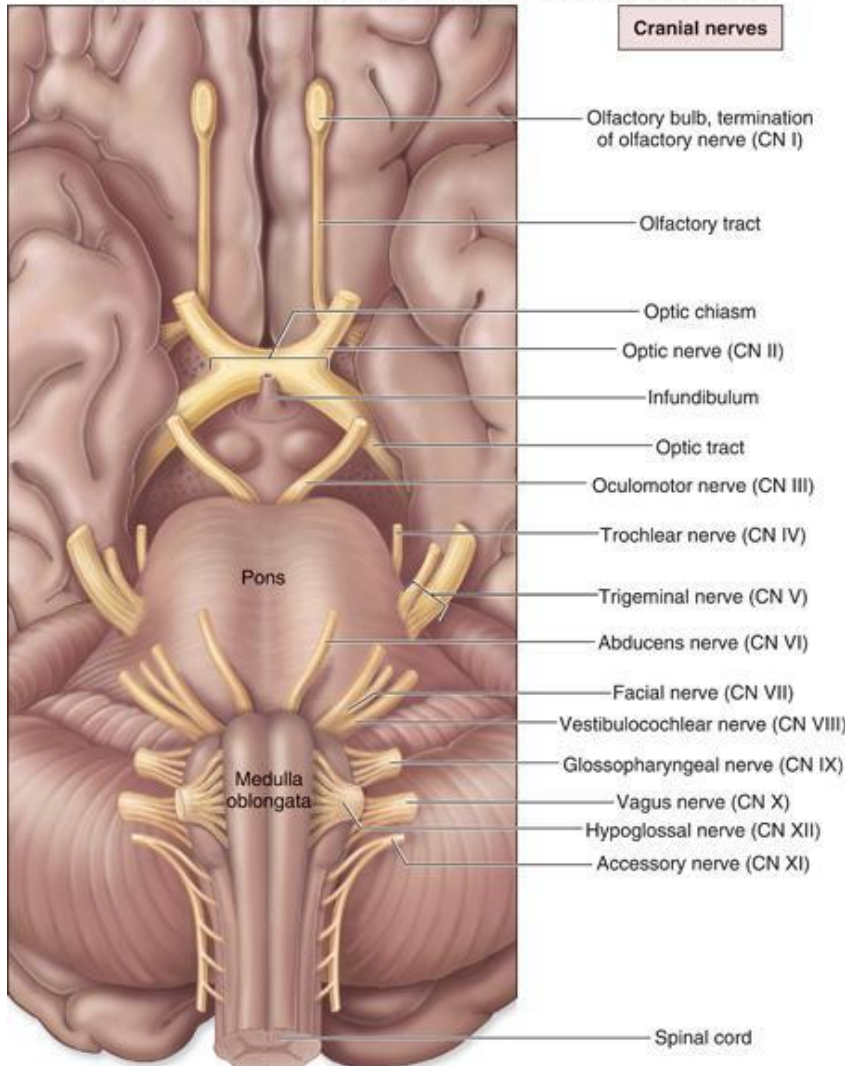
**Al-Farabi Kazakh
National
University
Higher School of
Medicine**

Nervous System: Cranial Nerves



Cranial Nerves

Copyright © The McGraw-Hill Companies, Inc. Permission required for reproduction or display.



- Indicated by Roman numerals I-XII from anterior to posterior
- May have one or more of 3 functions
 - Sensory (special or general)
 - Somatic motor (skeletal muscles)
 - Parasympathetic (regulation of glands, smooth muscles, cardiac muscle)
- Proprioception
 - Positional information of body parts

Cranial Nerves

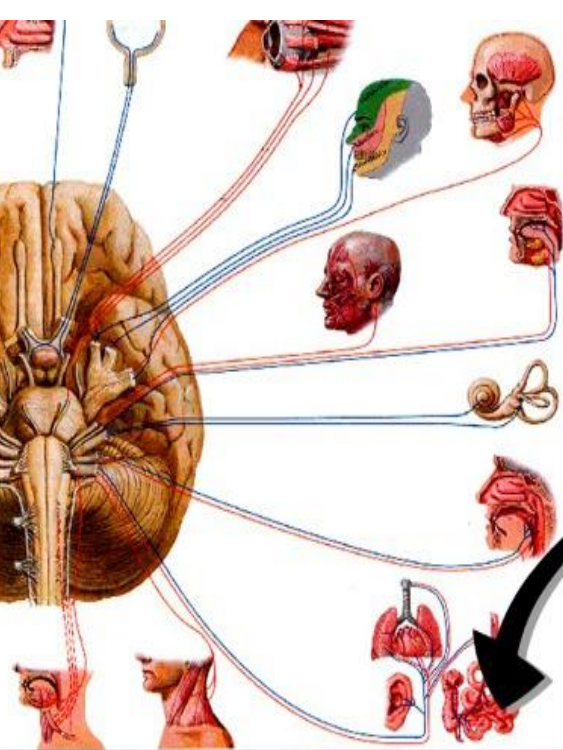
- Olfactory (I)
- Optic (II)
- Oculomotor (III)
- Trochlear (IV)
- Trigeminal (V)
- Abducens (VI)
- Facial (VII)
- Vestibulocochlear (VIII)
 - Also known as auditory
- Glossopharyngeal (IX)
- Vagus (X)
- Accessory (XI)
 - Also known as spinal accessory
- Hypoglossal (XII)

Mnemonic Aids for Cranial Nerves

- On Old Olympus Towering Tops A Famous Vocal German Viewed Some Hops
 - Olfactory, Optic, Oculomotor, Trochlear, Trigeminal, Abducens, Facial, Vestibulocochlear, Glossopharyngeal, Vagus, Spinal Accessory (Accessory), Hypoglossal

Mnemonic Aids for Sensory and /or Motor Functions of Cranial Nerves

- Some Say Marry Money, But My Brother Says Big Business Matters More
- The first letter of each word signifies whether the particular cranial nerve is sensory only (S); motor (M); or both sensory and motor (B)



CRANIAL NERVES

SENSORY

OLFACTORY (I)
OPTIC (II)
VESTIBULOCOCHLEAR (VIII)

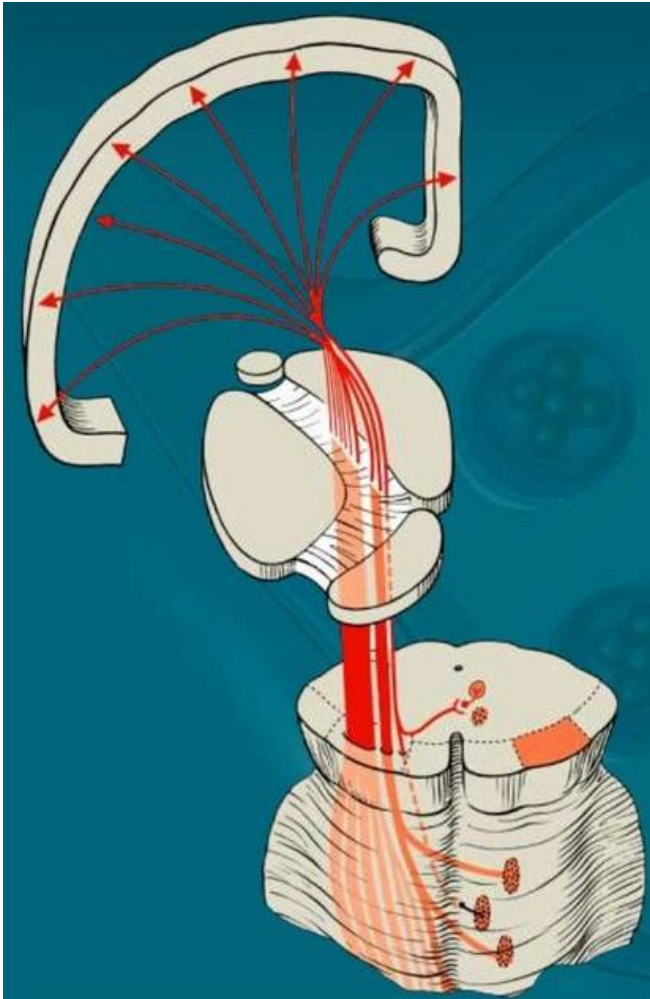
MOTOR

OCULOMOTOR (III)
TROCHLEAR (IV)
ABDUCENS (VI)
ACCESSORY (XI)
HYPOGLOSSAL (XII)

MIXED

TRIGEMINAL (V)
FACIAL (VII)
GLOSSOPHARYNGEAL (IX)
VAGUS (X)

Corticospinal tract (motor pathway)



I motor neuron-The lower part
of the anterior central gyrus



Corona radiata



Genu of the internal capsule



Cerebral peduncles

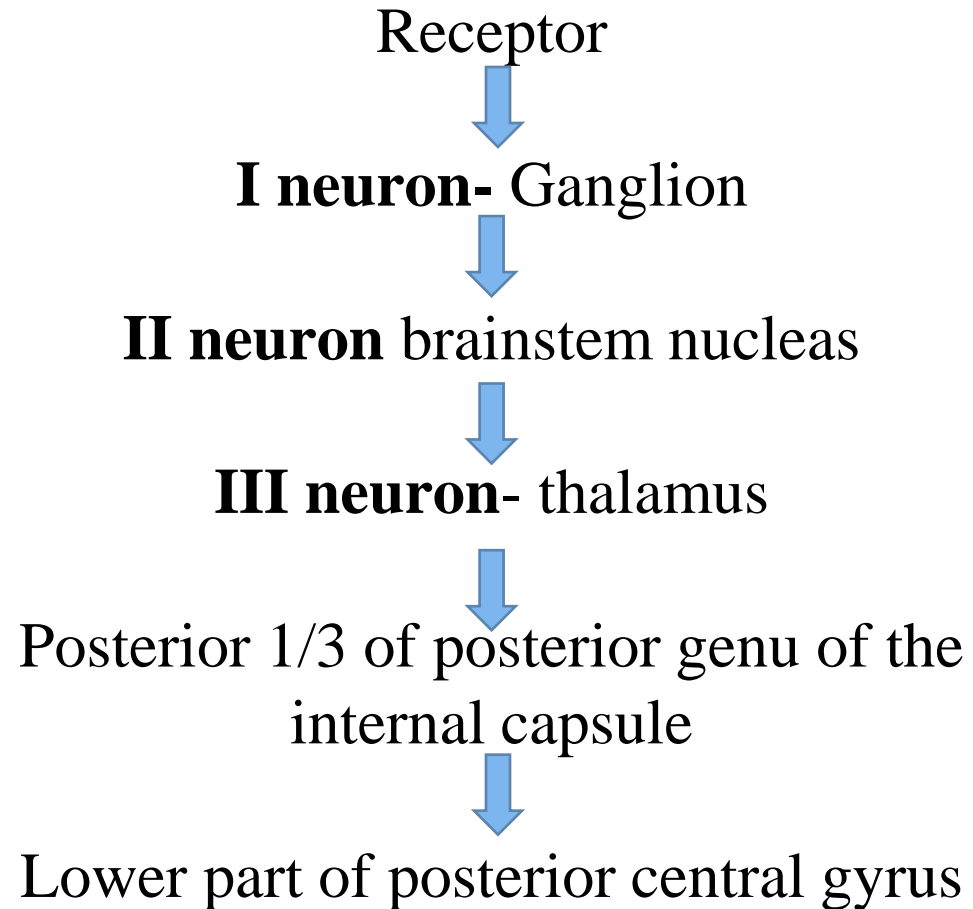
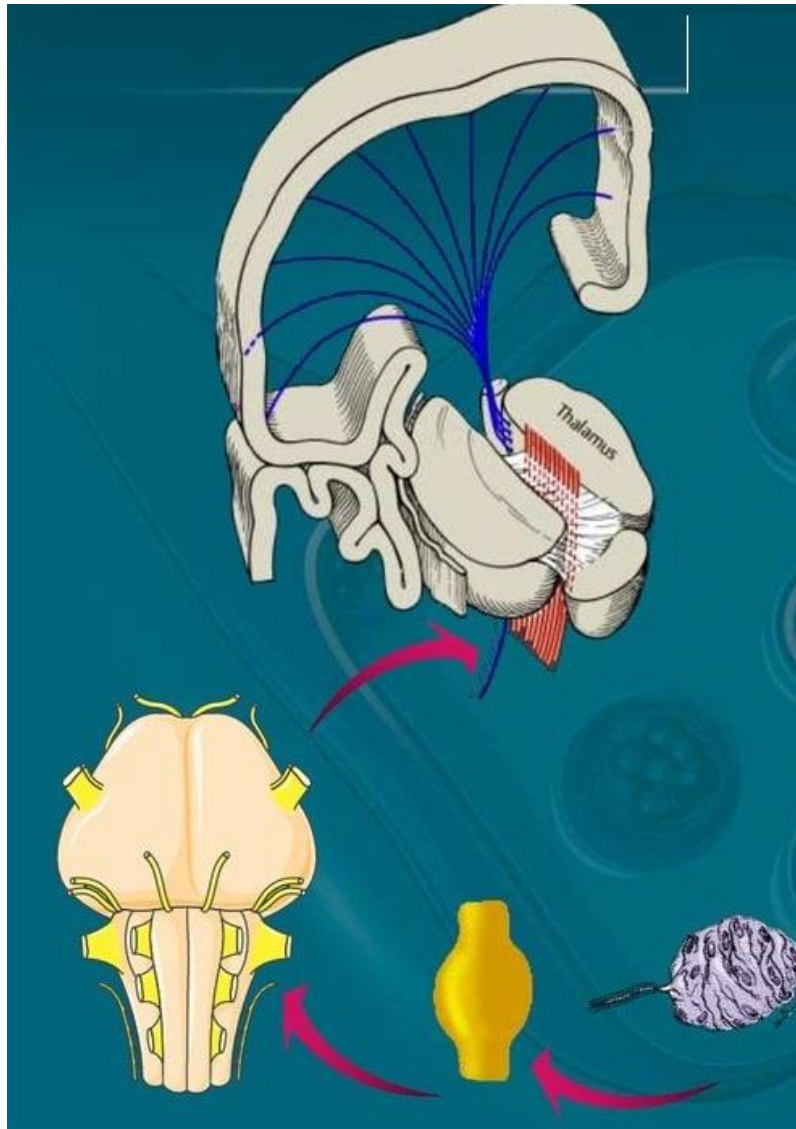


II motor neuron (brainstem
nucleus)



Muscles

Sensory pathways of cranial nerves

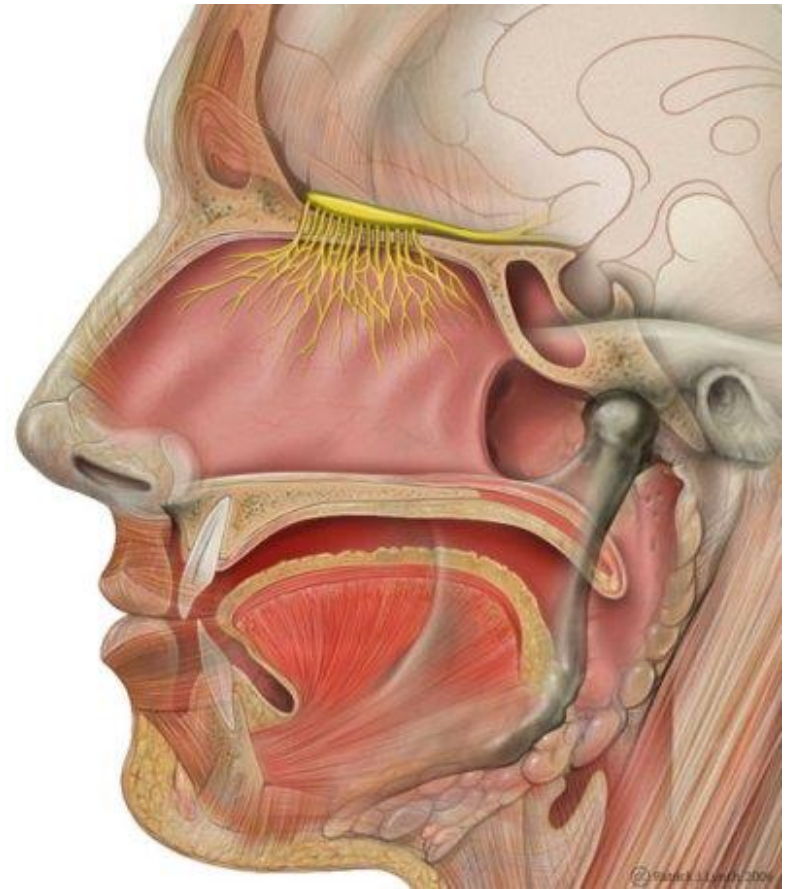


The main functions of the cranial nerves

1. **Olfactory**- smell
2. **Optic**- vision
3. **Oculomotor**- 4 of the 6 extrinsic eye muscles
4. **Trochlear**- extrinsic eye muscles
5. **Trigeminal**- sensory fibers to the face and motor fibers to the chewing muscles
6. **Abducens**- controls eye muscles that turn the eye laterally
7. **Facial**- facial expression
8. **Vestibulocochlear**- hearing and balance
9. **Glossopharyngeal**- tongue and pharynx
10. **Vagus**- from medulla- acetylcholine slows heart & breathing
11. **Accessory**- accessory part of vagus nerve
12. **Hypoglossal**- moves muscles under tongue

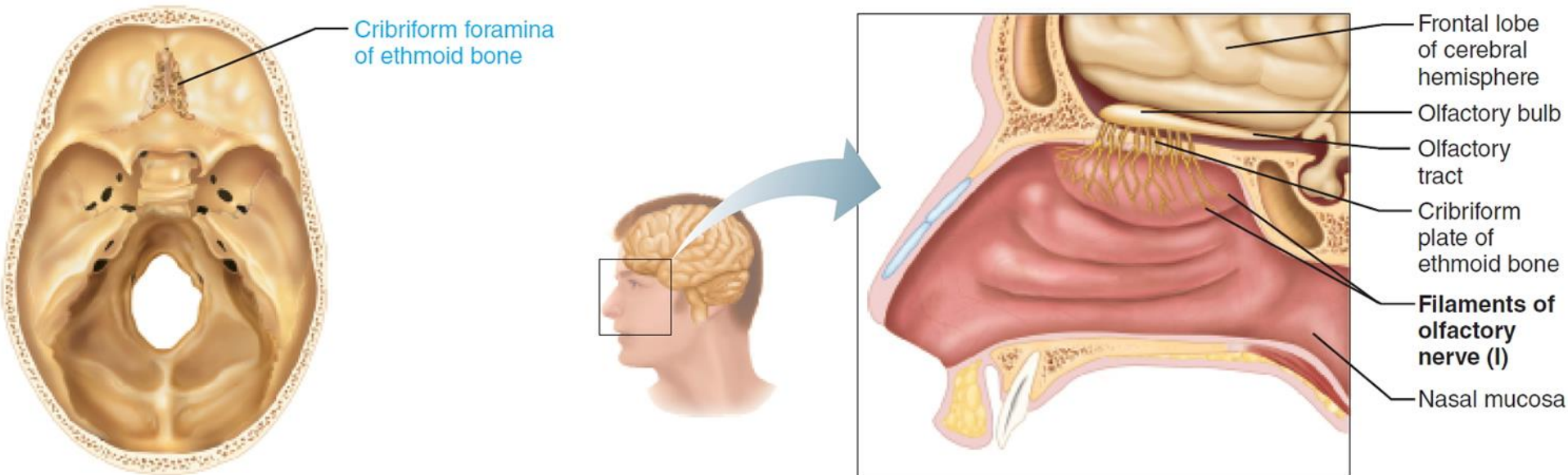
I. Olfactory Nerve

- **It is a sensory nerve** that transmits a sensory information to the brain allowing us to have a sense of smell
- Olfactory nerve is only one component of the overall pathway and is, in fact, made up of multiple nerve fibers/rootlets coming from the receptors cells.



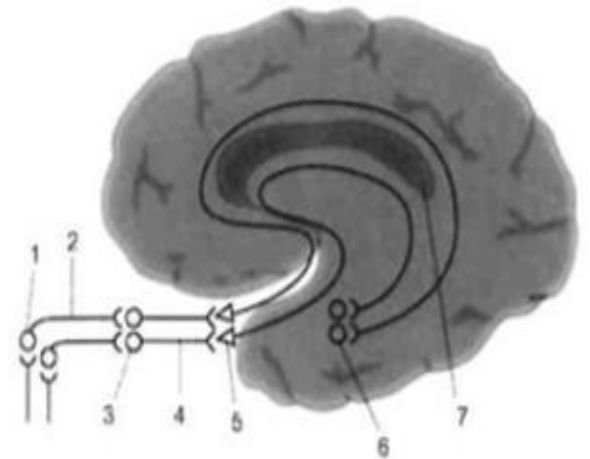
I. Olfactory Nerve

- The olfactory epithelium occupies the superior part of the nasal cavity (**Olfactory mucosa in nasal cavity**), covering the inferior surface of the cribriform plate and extending down along the superior nasal conchae.
- Each has a single odor sensitive dendrite projecting from one side of the cell body and an unmyelinated axons extending from the other side.
- Bundle of axons of olfactory receptors extend through about 20 olfactory foramina in the cribriform plate of the **ethmoid bone**



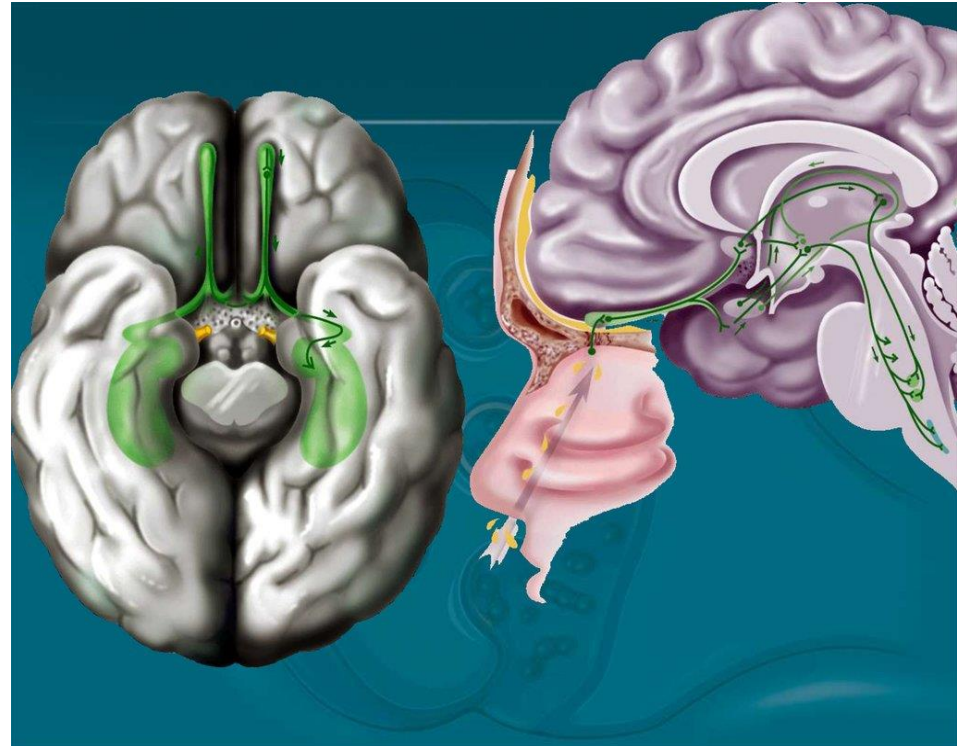
I. Olfactory Nerve

- Olfactory nerves end in the brain in paired masses of gray matter called the **olfactory bulbs**. Two extensions of the brain that rest on the cribriform plate.
- Within the olfactory bulbs, the axon terminals of olfactory receptor form synapses with the dendrite and cell bodies of the next neurons in the olfactory pathway.
- The axons of these neuron make up the olfactory tract, which extend posteriorly from the olfactory bulbs.
- Axons in the olfactory tract end in the primary olfactory area in the temporal lobe of the temporal cerebral cortex.



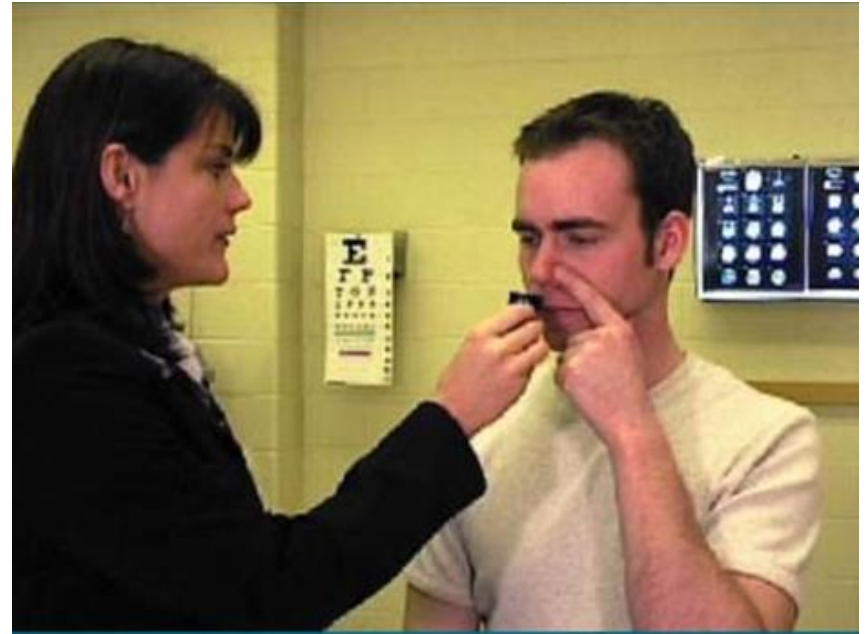The pathway can be summarized as follows:

- olfactory receptor cells
- olfactory nerves
- olfactory bulb
- olfactory tract
- olfactory striae
- olfactory cortex
- output targets of the olfactory cortex



Olfactory testing

- Determine whether subject can smell (not necessarily identify) aromatic substances such as:
 - coffee, vanilla,
 - clove oil, or soap



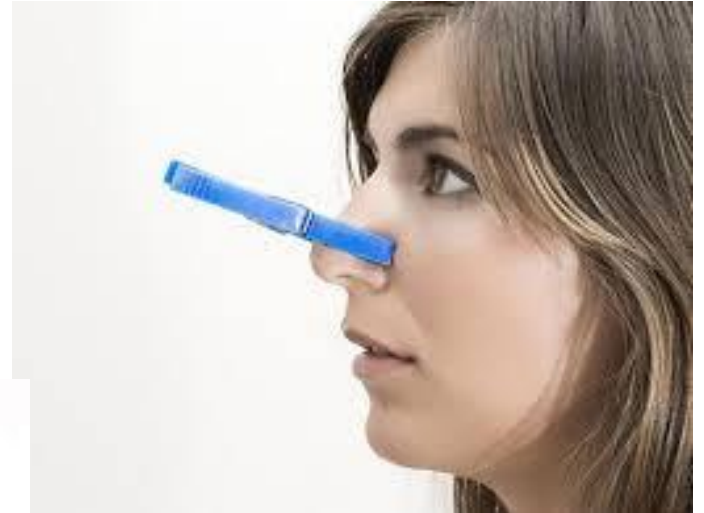Nota bene!

(Pay special attention)

- Harsh odorous substances (alcohol, acetic acid, etc.) cannot be used, because they irritate not only 1 pair, but also the trigeminal and glossopharyngeal nerves

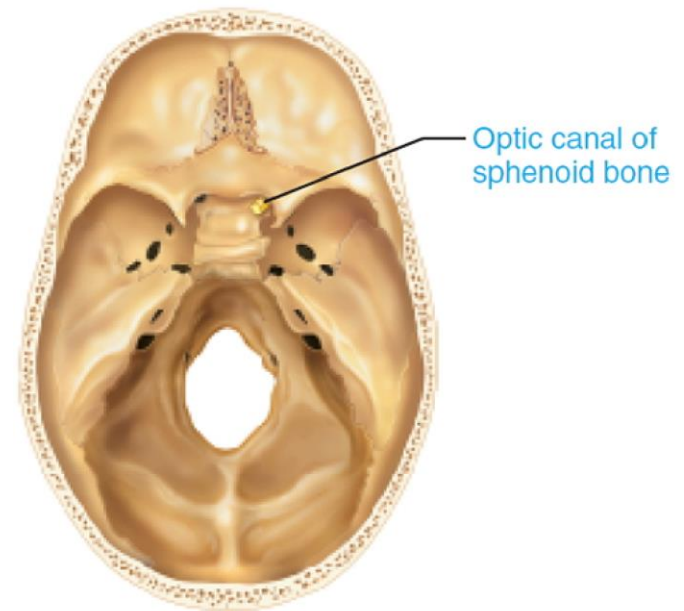
Effect of Damage

- Impaired sense of smell



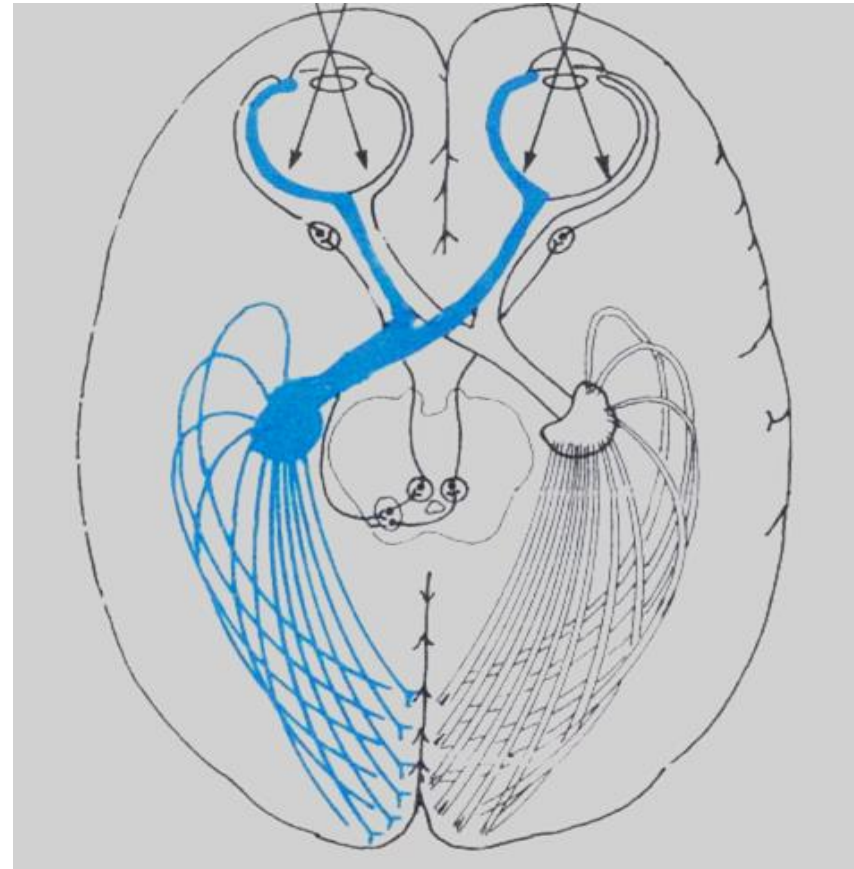
II Optic Nerve

- **Sensory nerve**
- Contains axons that conduct nerve impulses for vision.
- **In the retina**, rods and cones initiate visual signals and relay them to bipolar cells, which transmit the signals to ganglion cells.
- Axons of all ganglion cells in the retina of each eye join to form an optic nerve, which **pass through the optic foramen.**



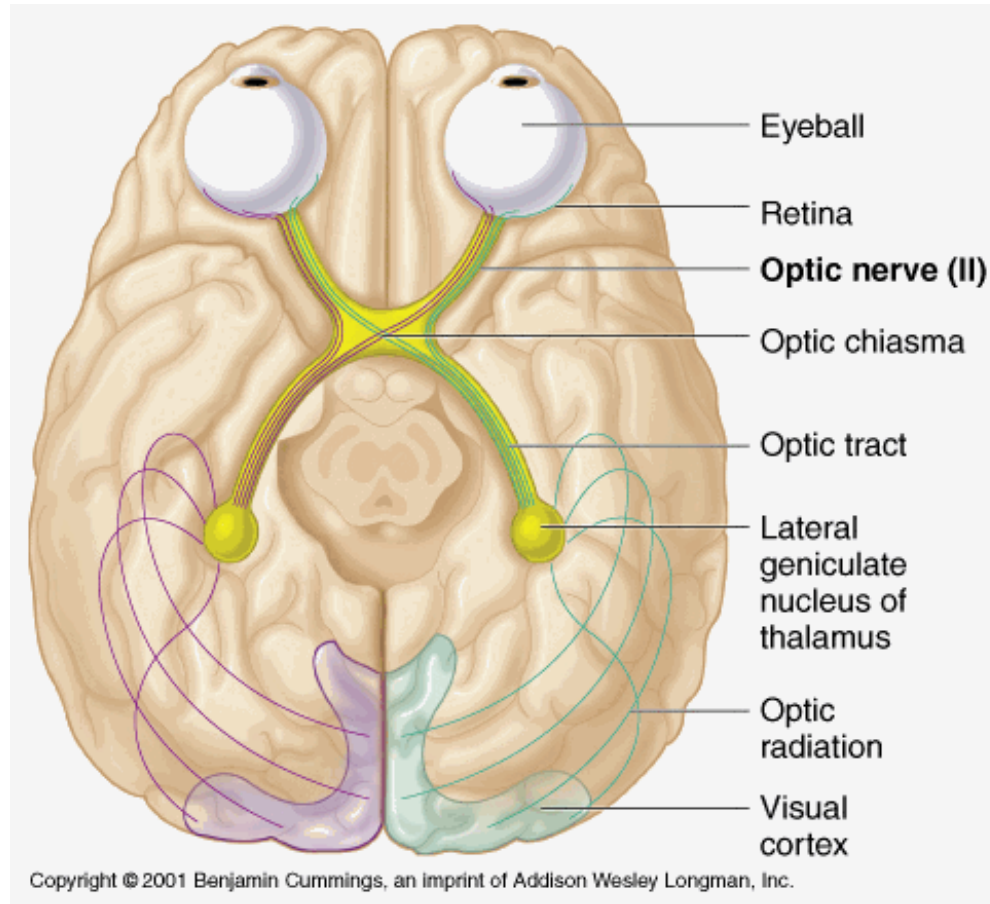
II Optic Nerve

- Posterior to the eyeball, the two optic nerves merge to form the optic chiasm.
- Within the chiasm, axons from the medial half of each eye cross to the opposite side, axons from the lateral half remain on the same side.
- Posterior to the chiasm, the regrouped axons, some from each eye, form the optic tracts.
- Most axons in the optic tracts end in the lateral geniculate nucleus of the **thalamus**.



II Optic Nerve

- There, they synapse with neuron whose axons extend to the primary visual area in the **occipital lobe of the cerebral cortex.**
- A few axons pass through the optic chiasm and then extend to the **superior colliculi of the midbrain.**



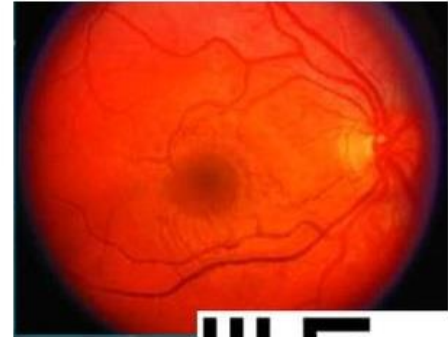


It can be subdivided into four main parts:

- The optic nerve head (i.e. intraocular part) measures about 1 mm in length.
- The intraorbital part is approximately 25 mm in length.
- The intracanalicular part is most variable, ranging between 4 – 10 mm in length.
- The Intracranial part accounts for about 10 mm of the total length of the nerve.

Clinical Test

- Inspect retina with ophthalmoscope;
- Test peripheral vision and
- Visual acuity



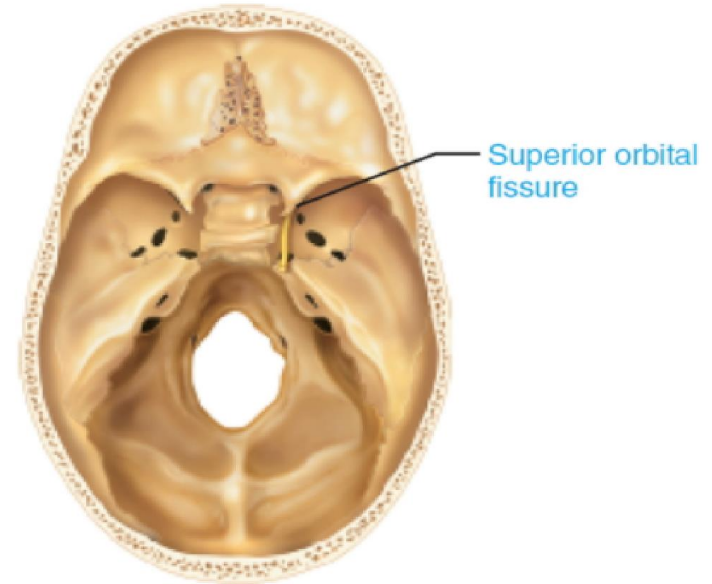
Effect of Damage

- Blindness in part or all of visual field



III Oculomotor Nerve

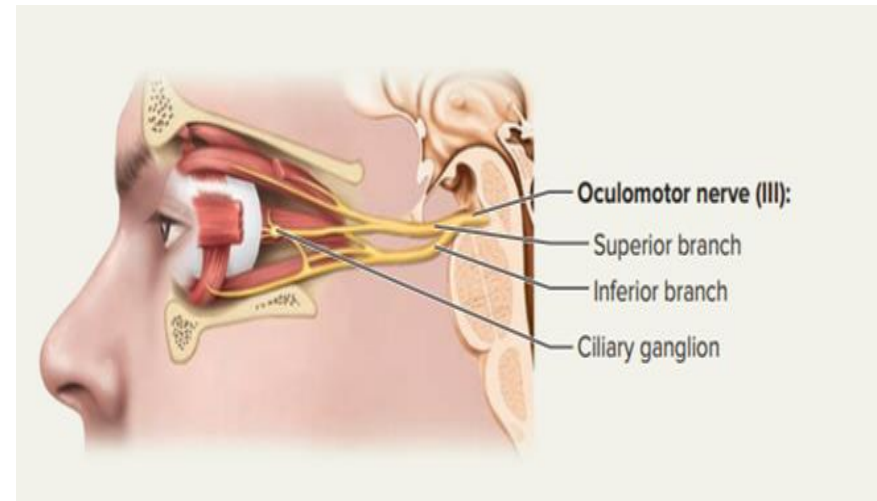
- This nerve controls muscles that turn the eyeball up, down, and medially, as well as controlling the iris, lens, and upper eyelid
- Motor nerve
- Originate in Midbrain
- Oculomotor nerve extends anteriorly and divides into superior and inferior branches, both of which pass through the **superior orbital fissure into the orbit.**



Axons in the superior branch innervate the superior rectus (extrinsic eyeball muscle) and the levator palpebrae superioris (muscles of upper eyelid)

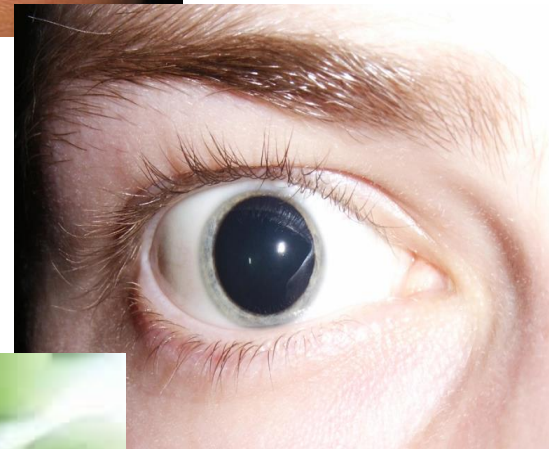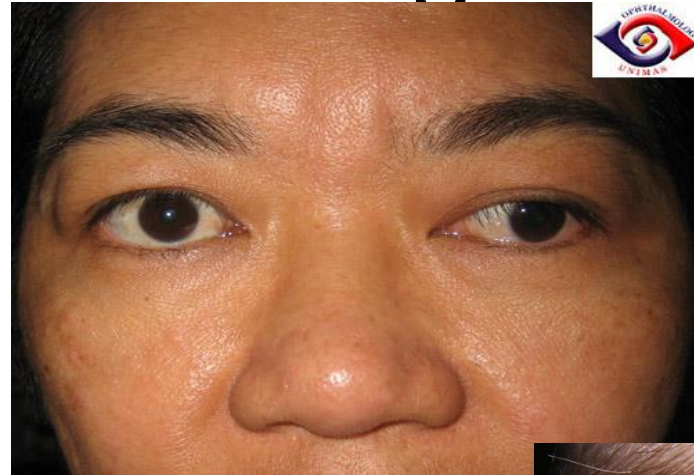III Oculomotor Nerve

- Axons in the inferior branch supply the medial rectus, inferior rectus and inferior oblique muscles (all extrinsic eyeball muscles).
- These somatic motor neurons control movements of the eyeball and upper eyelid.
- The inferior branch of the oculomotor nerve also provides parasympathetic innervation to intrinsic eyeball muscles, which are smooth muscles.




Effect of Damage

- Drooping eyelid;
- dilated pupil;
- inability to move eye in some directions;
- tendency of eye to rotate laterally at rest;
- double vision;
- difficulty focusing



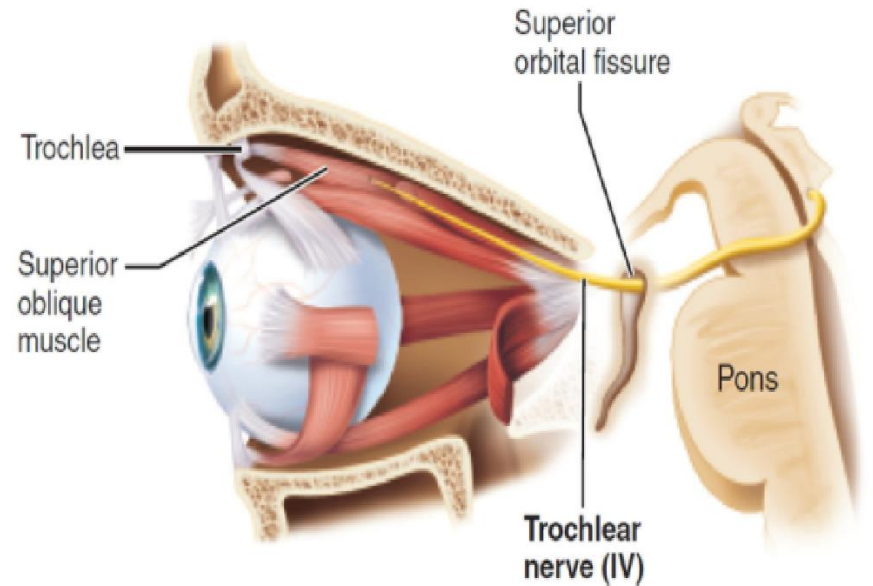
Clinical Test

- Look for differences in size and shape of right and left pupils;
- test pupillary
- response to light;
- test ability to track moving objects



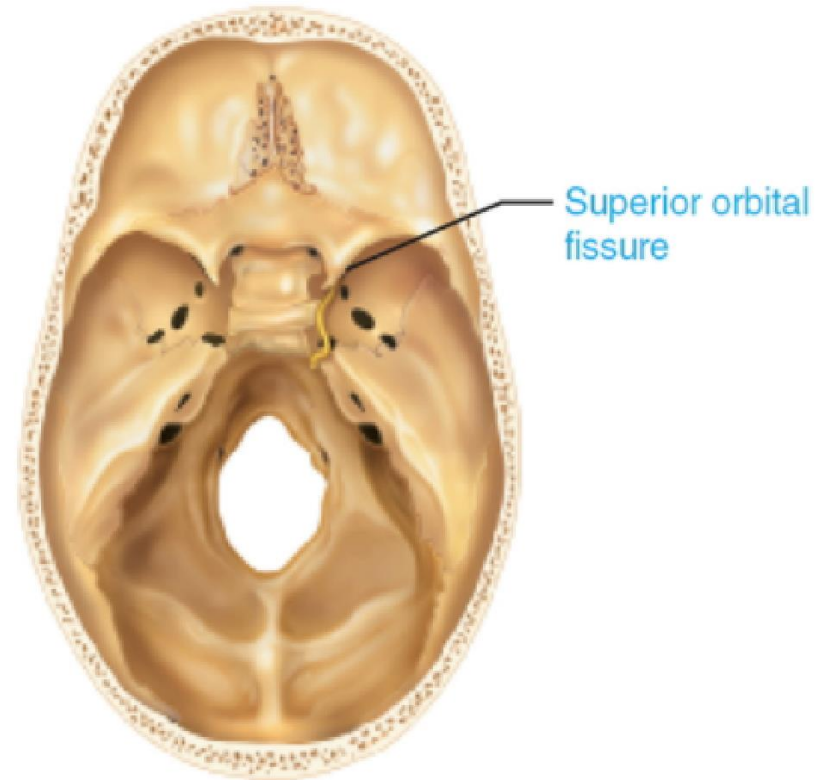
IV. Trochlear Nerve

- This nerve controls a muscle that directs the vision slightly downward and rotates the top of the eyeball toward the nose, especially in compensating for head movements.
- This is the only cranial nerve that **arises from the posterior side of the brainstem.**
- Motor nerve
- Smallest cranial nerve



IV. Trochlear Nerve

- The motor neurons originate in the trochlear nucleus in the midbrain, and axons from the nucleus pass through **the superior orbital fissure of orbit.**
- These somatic motor axons innervate the superior oblique muscles of the eyeball. (extrinsic eyeball muscle that control movement of the eyeball)

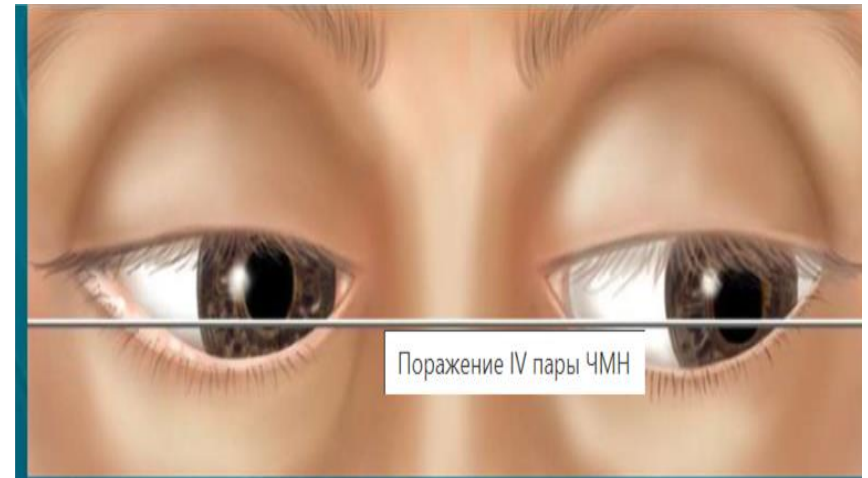


Effect of Damage

- Double vision and weakened ability to look downward;
- eye points superolaterally and subject tends to tuck the chin in and tilt the head downward to minimize the double vision

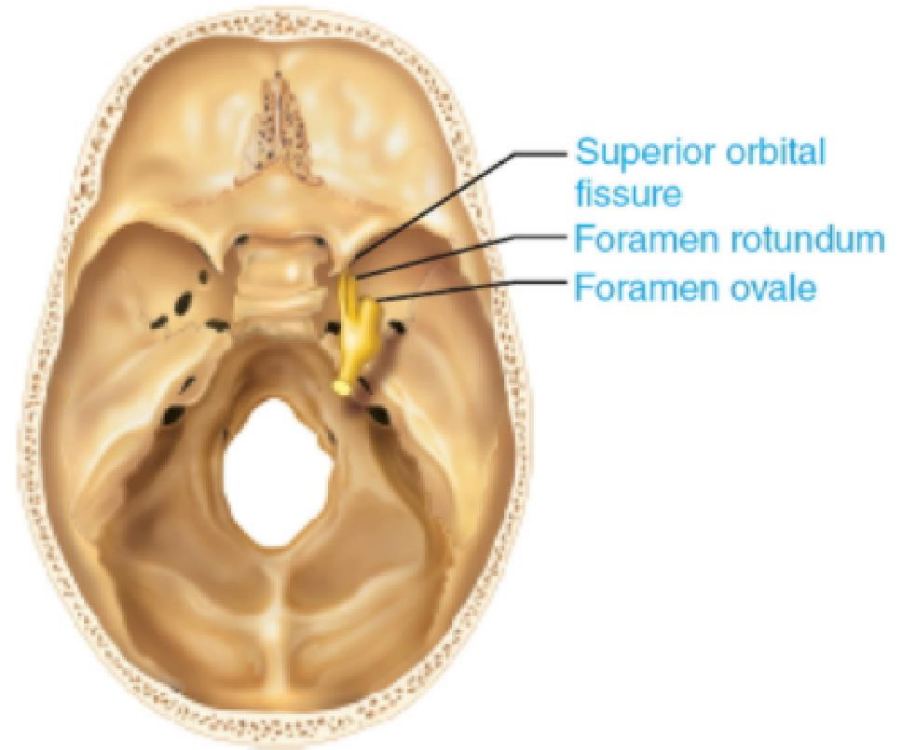
Clinical Test

- Ask subject to tilt the head toward one shoulder; affected eye shows upward deviation when head is tilted toward that side (Bielschowsky's head tilt test)



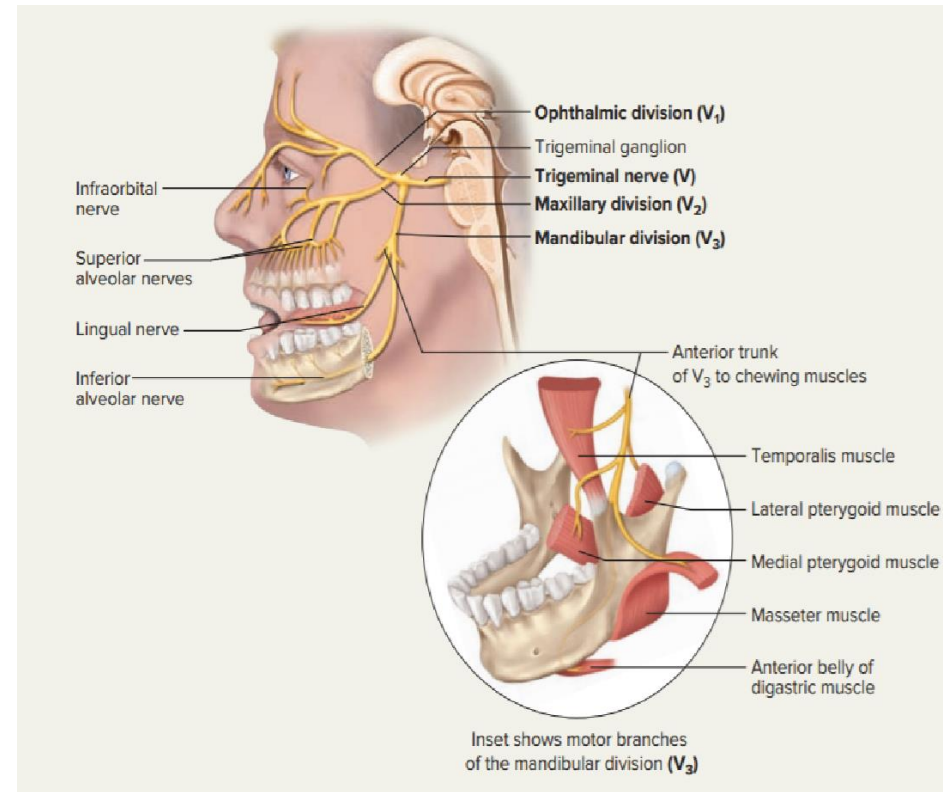
V. Trigeminal Nerve

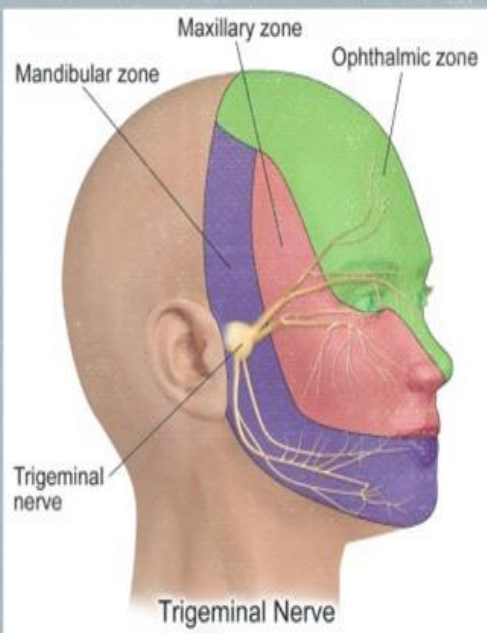
- Mixed nerve
- Largest cranial nerve
- 2 roots from venterolateral of the pons
- Have large sensory root and small motor root



V. Trigeminal Nerve

- The main function of the trigeminal nerve is to receive sensation from the face and control the four muscles of mastication (the masseter, temporalis, medial pterygoid, and the lateral pterygoid.)





Trigeminal nerve

Ophthalmic division V1

Sensory
 Function: Touch, temperature, and pain sensations from upper face
 Origin: Superior region of face as illustrated; surface of eyeball; lacrimal (tear) gland; superior nasal mucosa; frontal and ethmoid sinuses
 Terminated: Pons
 Cranial Passage: Superior orbital fissure
 Effect of Damage: Loss of sensation from upper face
 Clinical Test: Test corneal reflex (blinking in response to light touch to eyeball)

Maxillary division V2

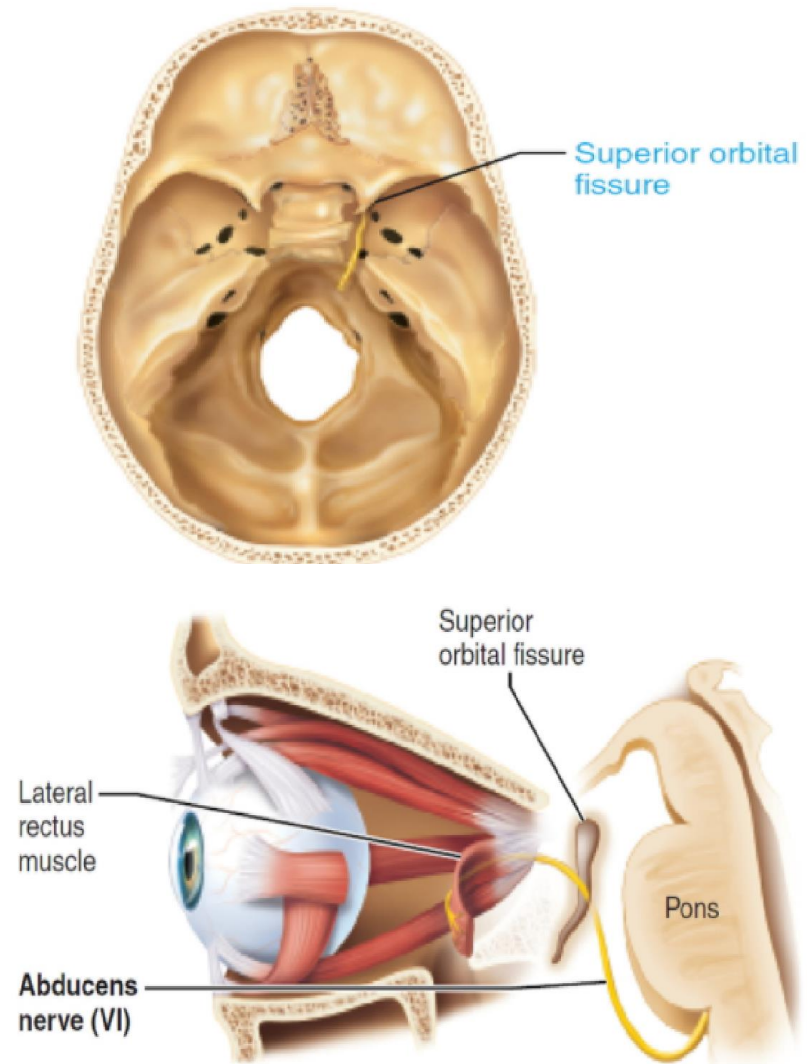
Sensory
 Function: Same as V1, lower on face
 Origin: Middle region of face as illustrated; nasal mucosa; maxillary sinus; palate; upper teeth and gums
 Terminated: Pons
 Cranial Passage: Foramen rotundum and infraorbital foramen
 Effect of Damage: Loss of sensation from middle face
 Clinical Test: Test sense of touch, pain, and temperature with light touch, pinpricks, and hot and cold objects

Mandibular division V3

Mixed Sensory
 Function Same as V1 and V2, lower on face.
 Motor: Mastication
 Origin: Sensory: Inferior region of face as illustrated; anterior two-thirds of tongue (but not taste buds); lower teeth and gums; floor of mouth; dura mater
 Motor: Pons
 Terminated: Sensory: Pons
 Motor: Anterior belly of digastric; masseter, temporalis, mylohyoid, and pterygoid muscles; tensor tympani muscle of middle ear
 Cranial Passage: Foramen ovale
 Effect of Damage: Loss of sensation; impaired chewing
 Clinical Test: Assess motor functions by palpating masseter and temporalis while subject clenches teeth; test ability to move mandible from side to side and to open mouth against resistance

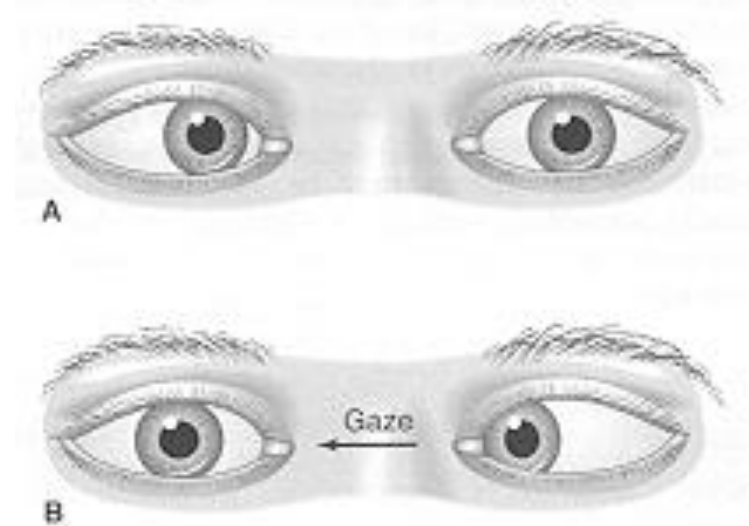VI. Abducens Nerve

- This nerve controls a muscle that turns the eyeball laterally.
- Motor nerve
- Origin – abducens nucleus of the pons
- Somatic motor axons extend from the nucleus to the lateral rectus muscle of the eyeball, through the superior orbital fissure of the orbit



Effect of Damage

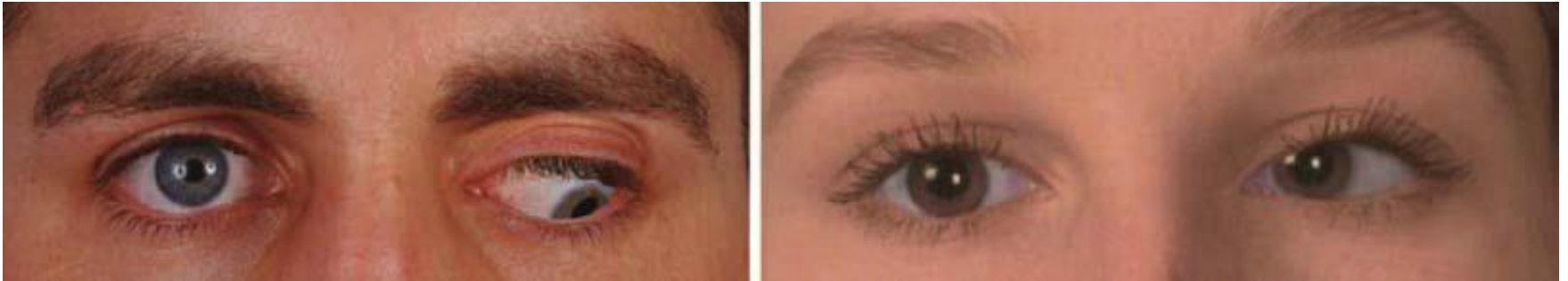- Inability to turn eye laterally; at rest, eye turns medially because of action of antagonistic muscles



Clinical Test

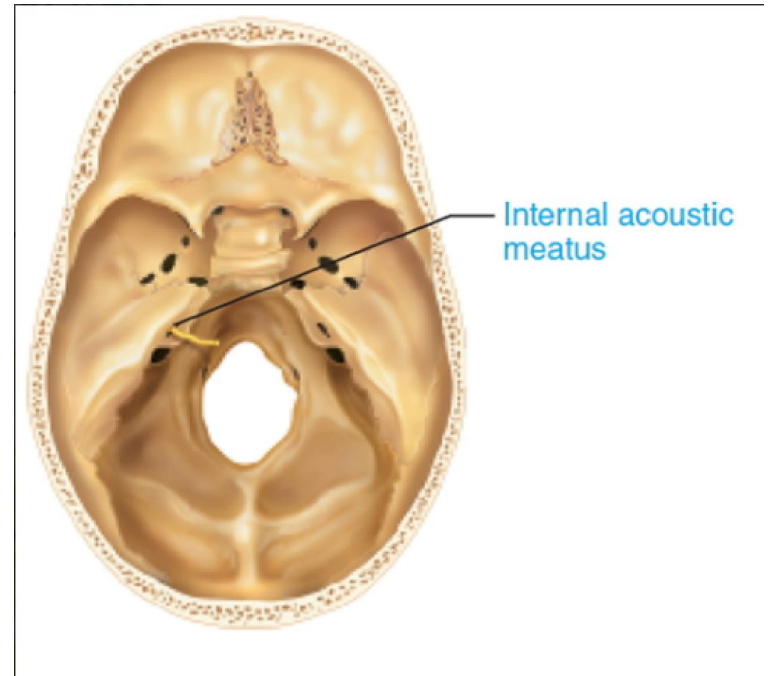
Test lateral eye movement

Which nerve is paralysed?



VII. Facial Nerve

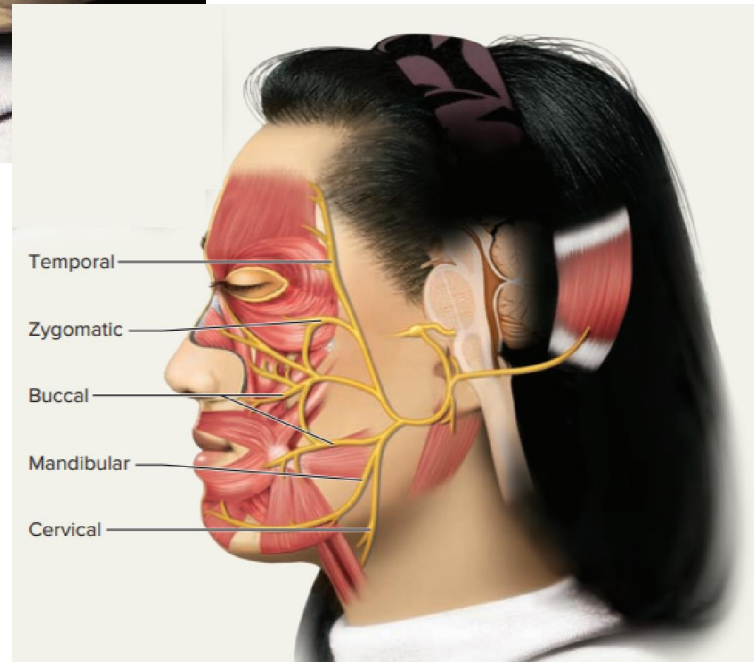
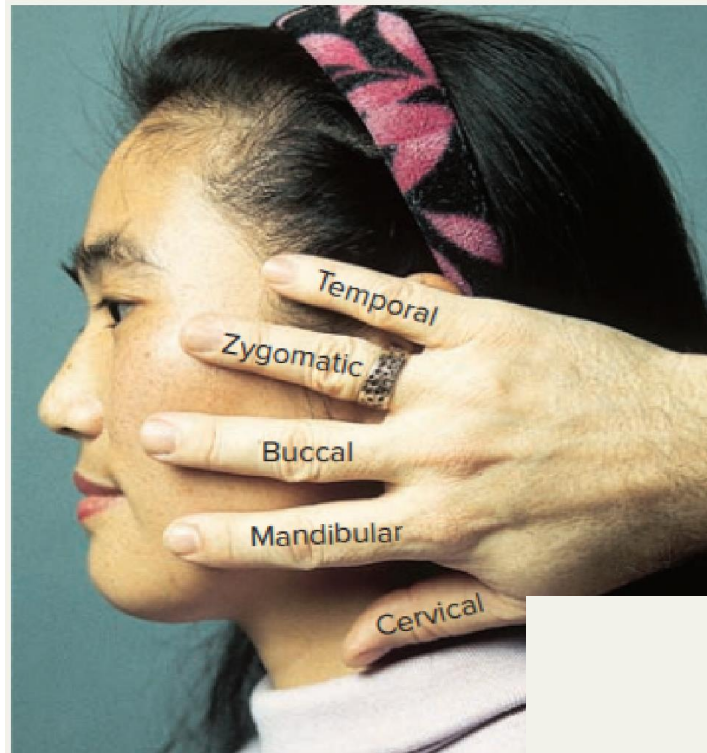- This is the major motor nerve of the facial muscles.
- **Origin:**
 - Sensory: Taste buds of anterior two-thirds of tongue
 - Motor: Pons
- **Termination:**
 - Sensory: Thalamus
 - Motor: Somatic fibers to digastric muscle, stapedius muscle of middle ear, stylohyoid muscle, muscles of facial expression.
 - Autonomic fibers to submandibular and sublingual salivary glands, tear glands, nasal and palatine glands



Cranial Passage: Internal acoustic meatus and stylomastoid foramen

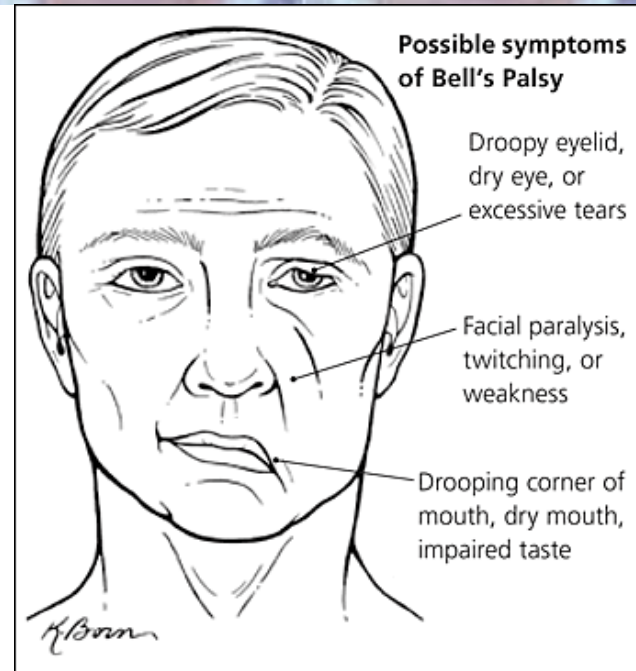
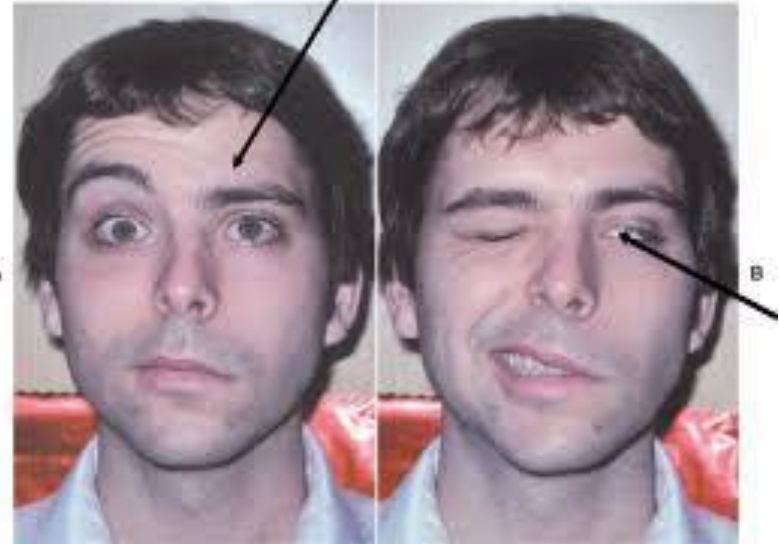Five prominent branches:

- Temporal
- Zygomatic
- Buccal
- Mandibular
- Cervical



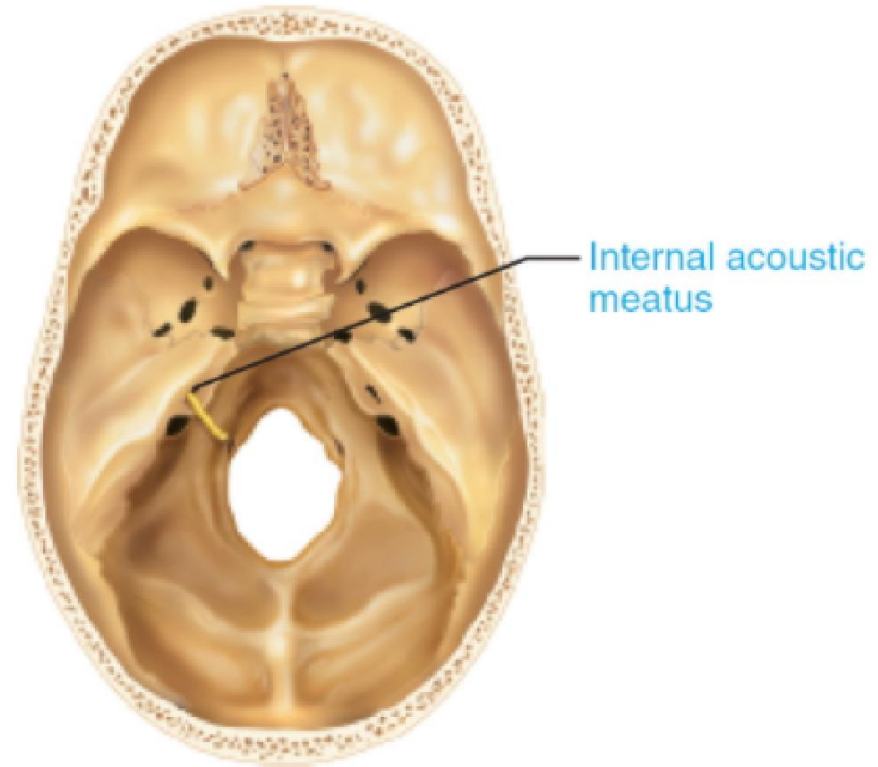
Effect of Damage

- Inability to control facial muscles;
- sagging due to loss of muscle tone;
- distorted sense of taste, especially for sweets



VIII. Vestibulocochlear Nerve

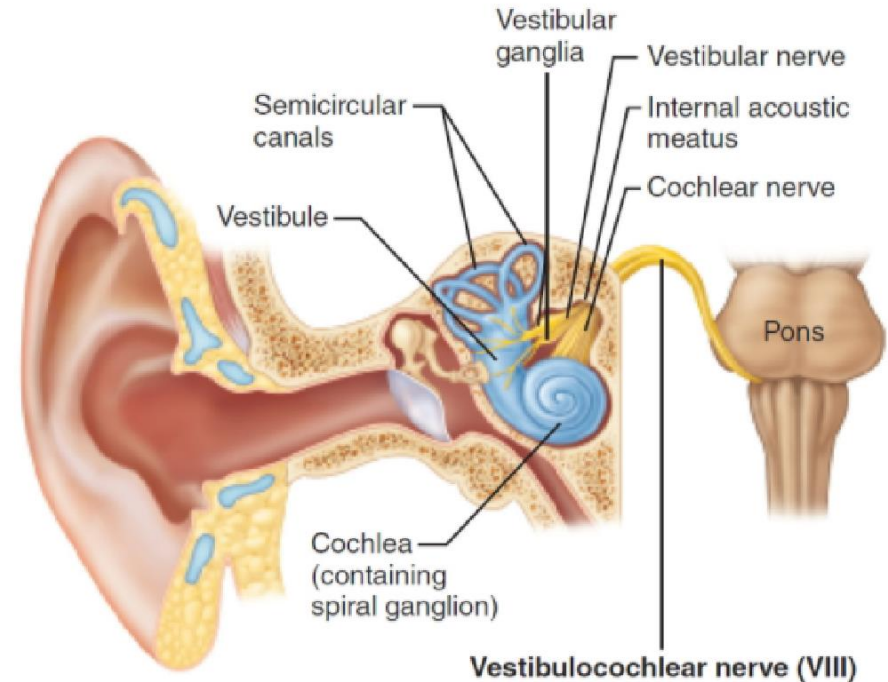
- This is the nerve of hearing and equilibrium, but it also has motor fibers that lead to cells of the cochlea that tune the sense of hearing.
- Origin:
 - Sensory: Cochlea, vestibule, and semicircular ducts of inner ear
 - Motor: Pons



Cranial Passage: Internal acoustic meatus

VIII. Vestibulocochlear Nerve

- Termination:
 - Sensory: Fibers for hearing end in medulla; fibers for equilibrium end at junction of medulla and pons
 - Motor: Outer hair cells of cochlea of inner ear



Effect of Damage

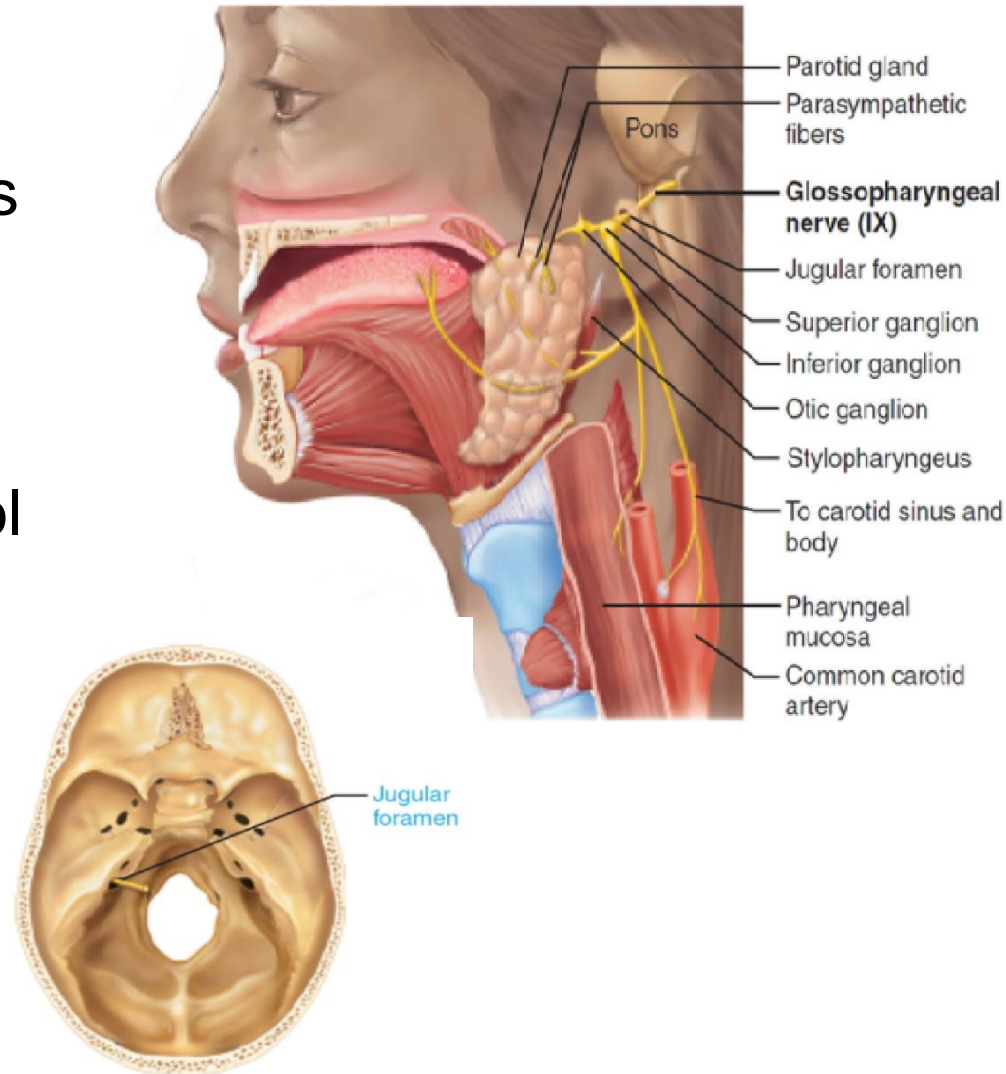
- Nerve deafness, dizziness, nausea, loss of balance, and nystagmus (involuntary rhythmic oscillation of eyes from side to side)



IX. Glossopharyngeal Nerve

- This is a complex, **mixed** nerve with numerous sensory and motor functions in the head, neck, and thoracic regions
- Sensation from the tongue, throat, and outer ear; control of food ingestion; and some aspects of cardiovascular and respiratory function.

Cranial Passage: Jugular foramen



IX. Glossopharyngeal Nerve

- **Origin:**

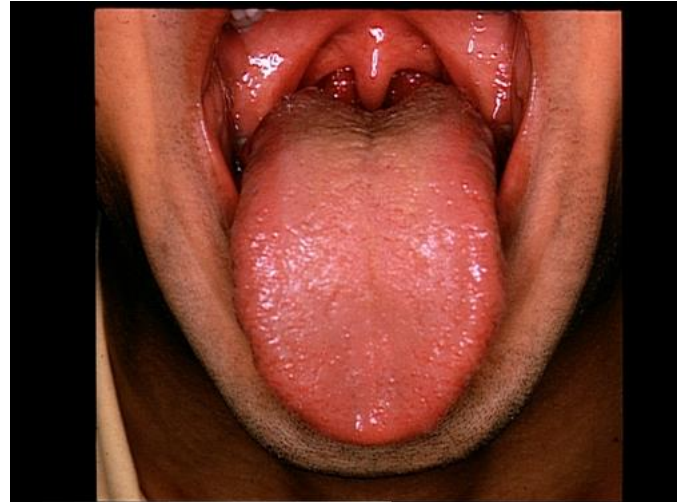- **Sensory:** Pharynx; middle and outer ear; posterior onethird of tongue (including taste buds); internal carotid artery
- **Motor:** Medulla oblongata

- **Termination**

- **Sensory:** Medulla oblongata
- **Motor:** Parotid salivary gland; glands of posterior tongue; stylopharyngeal muscle (which dilates pharynx during swallowing)

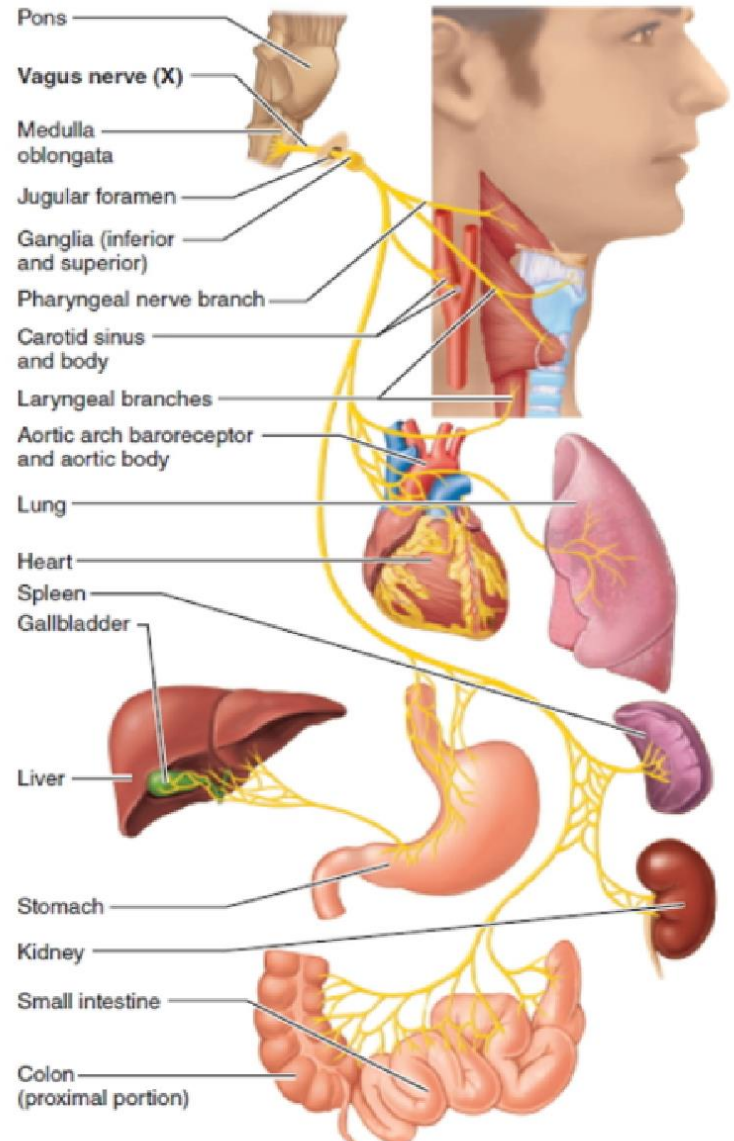
Effect of Damage

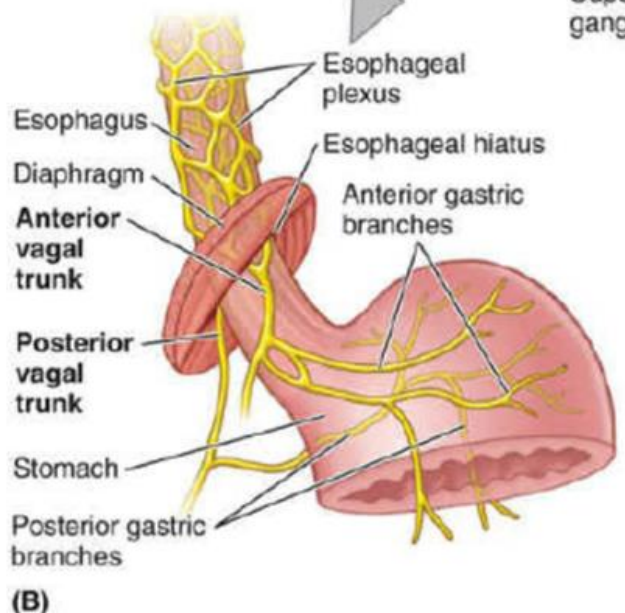
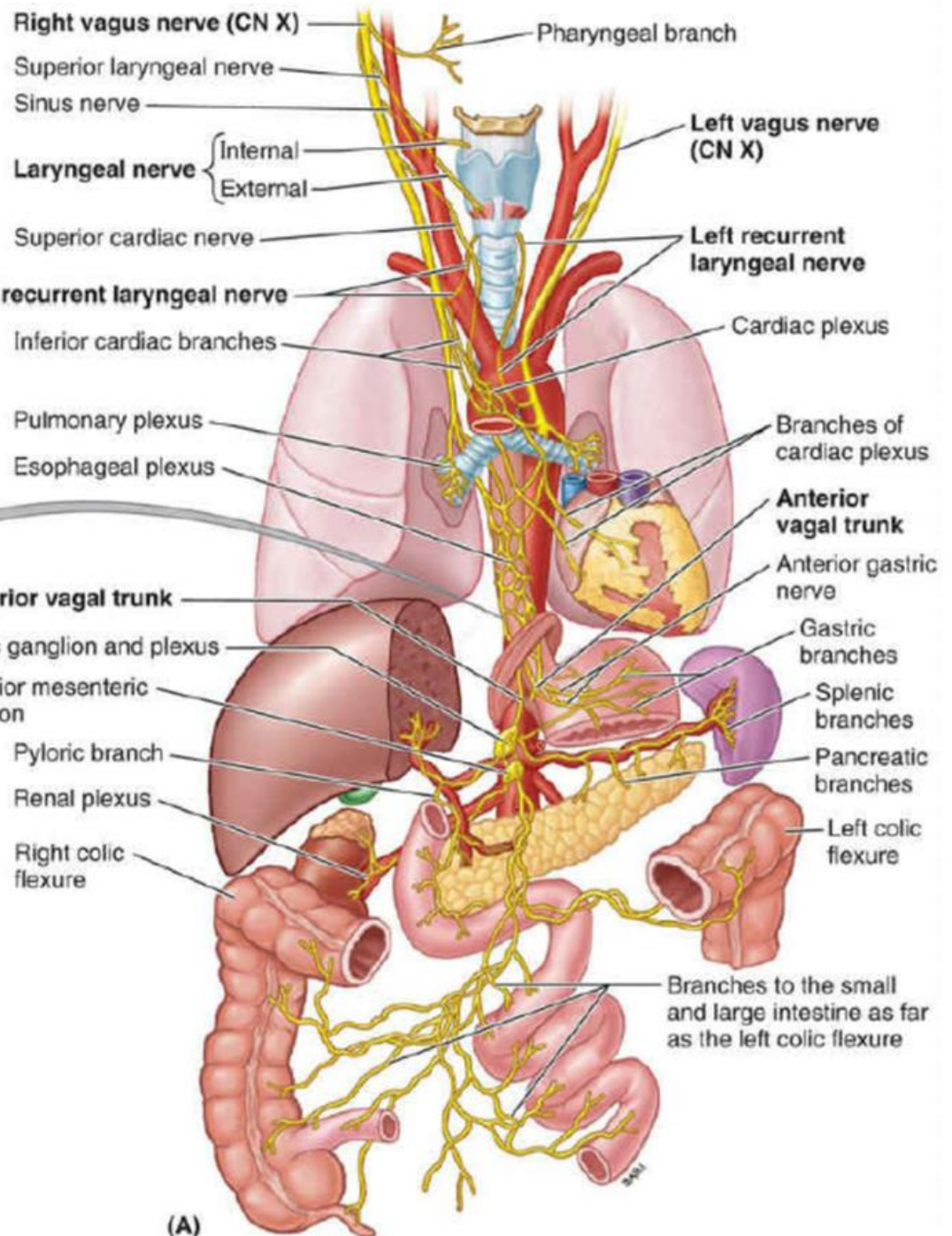
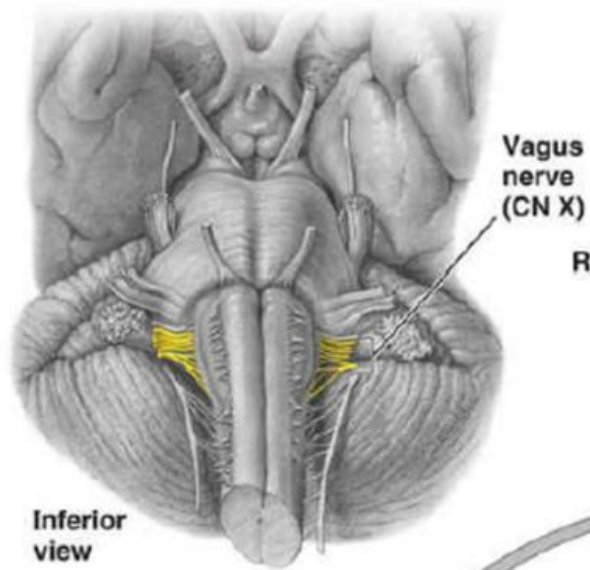
- Loss of bitter and sour taste;
- Impaired swallowing



X. Vagus Nerve

- The vagus has the most extensive distribution of any cranial nerve, supplying not only organs in the head and neck but also most viscera of the thoracic and abdominopelvic cavities. It plays major roles in the control of cardiac, pulmonary, digestive, and urinary functions.





Function

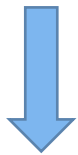
- Sensory:
 - Taste; sensations of hunger, fullness, and gastrointestinal discomfort
- Motor:
 - Swallowing, speech, deceleration of heart, bronchoconstriction, gastrointestinal secretion and motility

Sensory axon

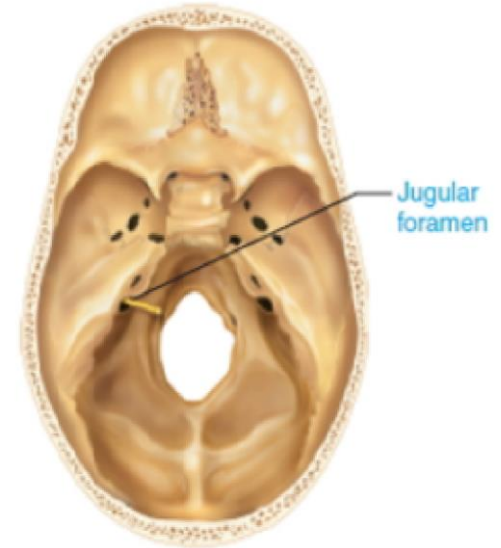
Arise from:

- Thoracic and abdominopelvic viscera
- root of tongue
- pharynx, larynx
- epiglottis
- outer ear
- dura mater

These axons pass through the jugular foramen

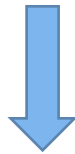

and end in the : Medulla oblongata and pons



Motor axons

- Arise from: Medulla oblongata



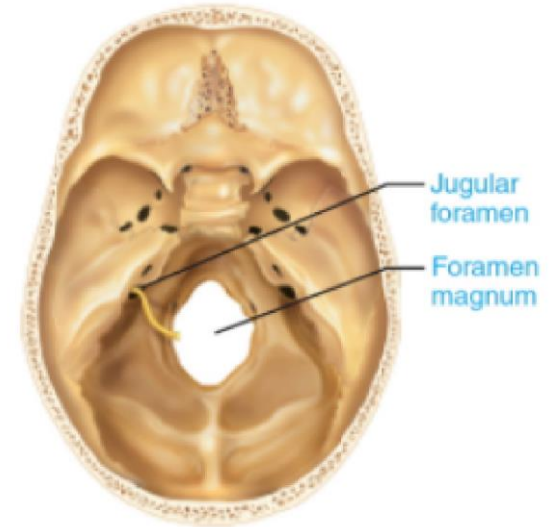
- Terminate:
 - Tongue,
 - palate,
 - pharynx, larynx,
 - lungs, heart, liver
 - spleen, digestive tract,
 - kidney, ureter

Effect of Damage

- Hoarseness or loss of voice;
- Impaired swallowing and gastrointestinal
- motility;
- Fatal if both vagus nerves are damaged

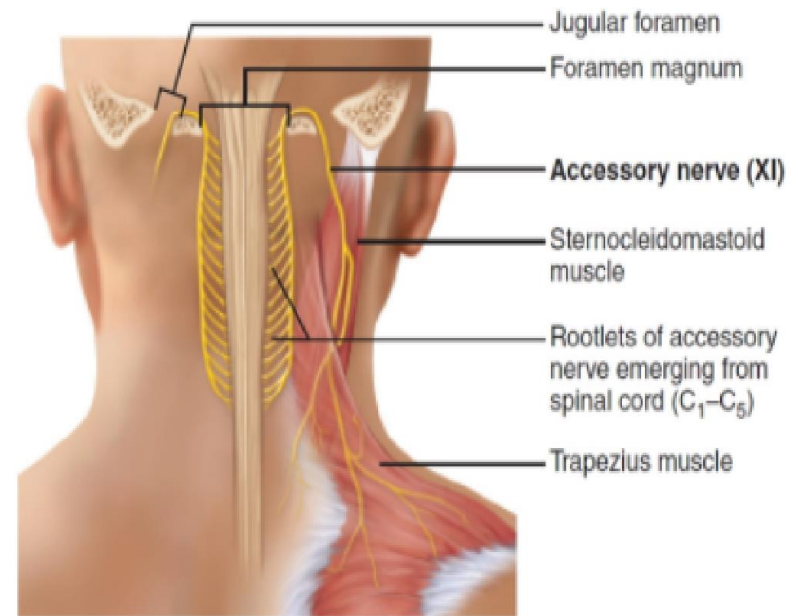
XI. Accessory Nerve

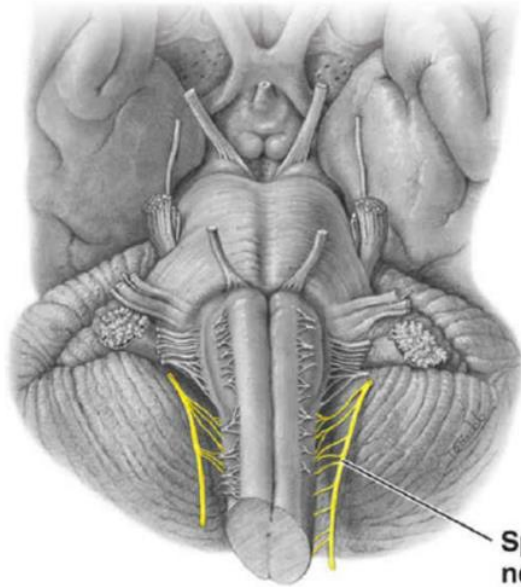
- Motor nerve
- Motor axons arise in the anterior gray of the 1st 5 segments of the cervical portion of the spinal cord.
- The axons from the segment exit the spinal cord laterally and come together, pass through the **foramen magnum** and exit through the **jugular foramen** along with the vagus nerve.



XI. Accessory Nerve

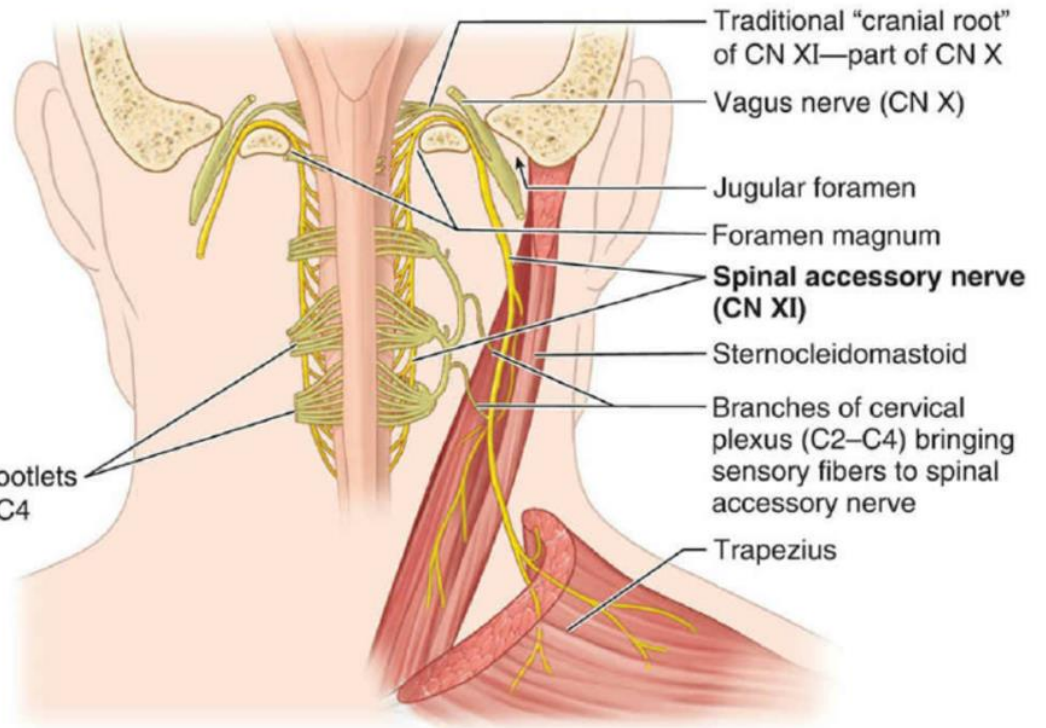
- The accessory nerve controls mainly swallowing and neck and shoulder muscles
- (Termination: Palate, pharynx, trapezius and sternocleidomastoid muscles)





Inferior view

Spinal accessory
nerve
(CN XI)

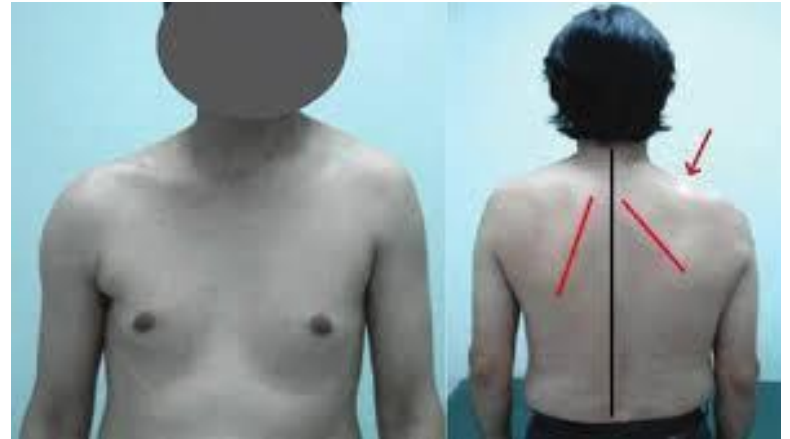

Posterior rootlets
of C3 and C4

Posterior view

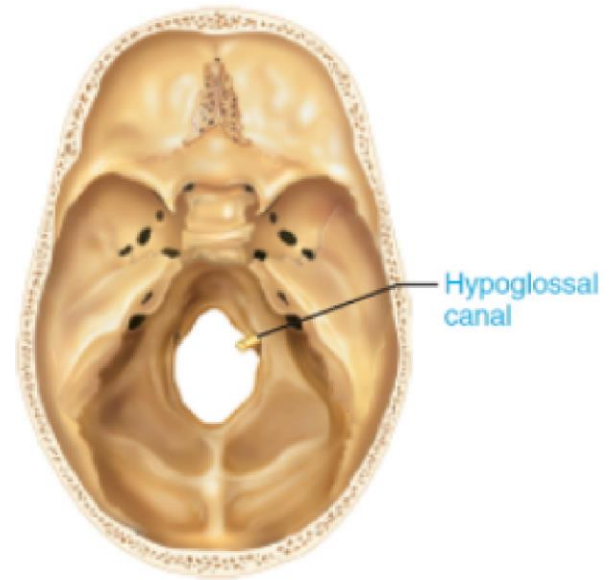
Effect of Damage

- Impaired movement of head, neck, and shoulders;
- Difficulty shrugging shoulder on damaged side;
- Paralysis of sternocleidomastoid, causing head to turn toward injured side



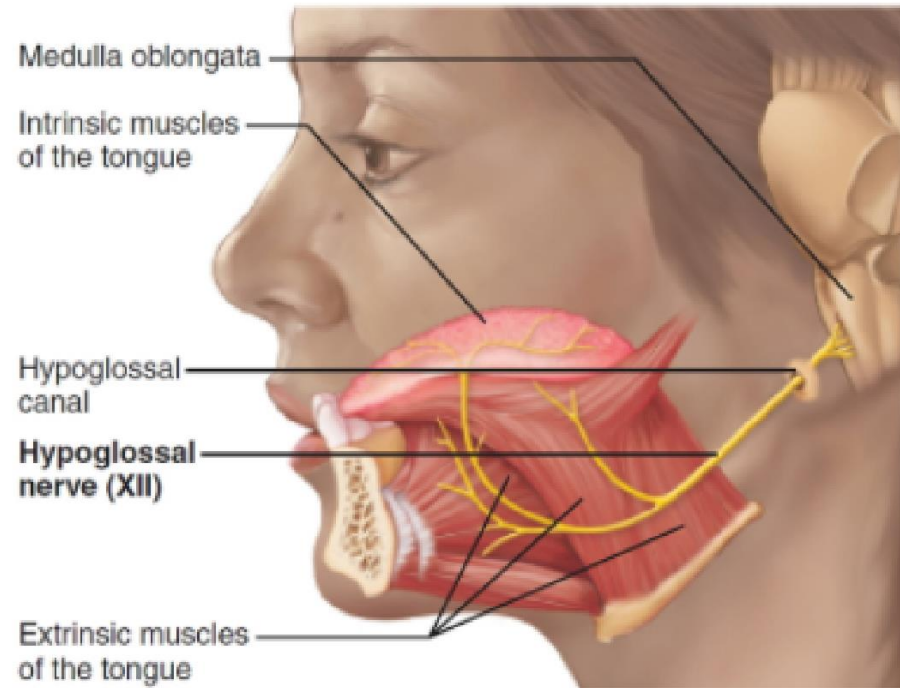
XII. Hypoglossal Nerve

- Motor nerve
- Somatic motor axons originate in the hypoglossal nuclei in the MO, pass through the hypoglossal canal, and supply the muscles of the tongue.



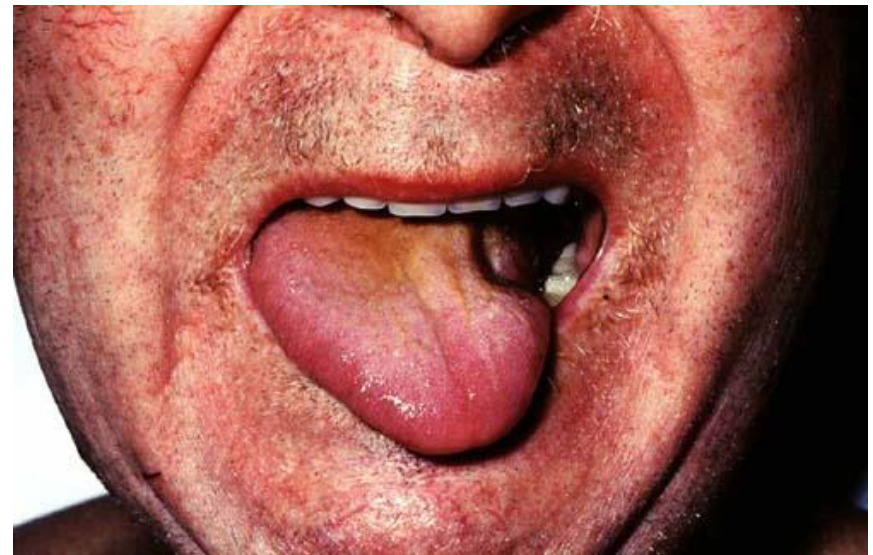
XII. Hypoglossal Nerve

- These axons conduct impulses for speech and swallowing.



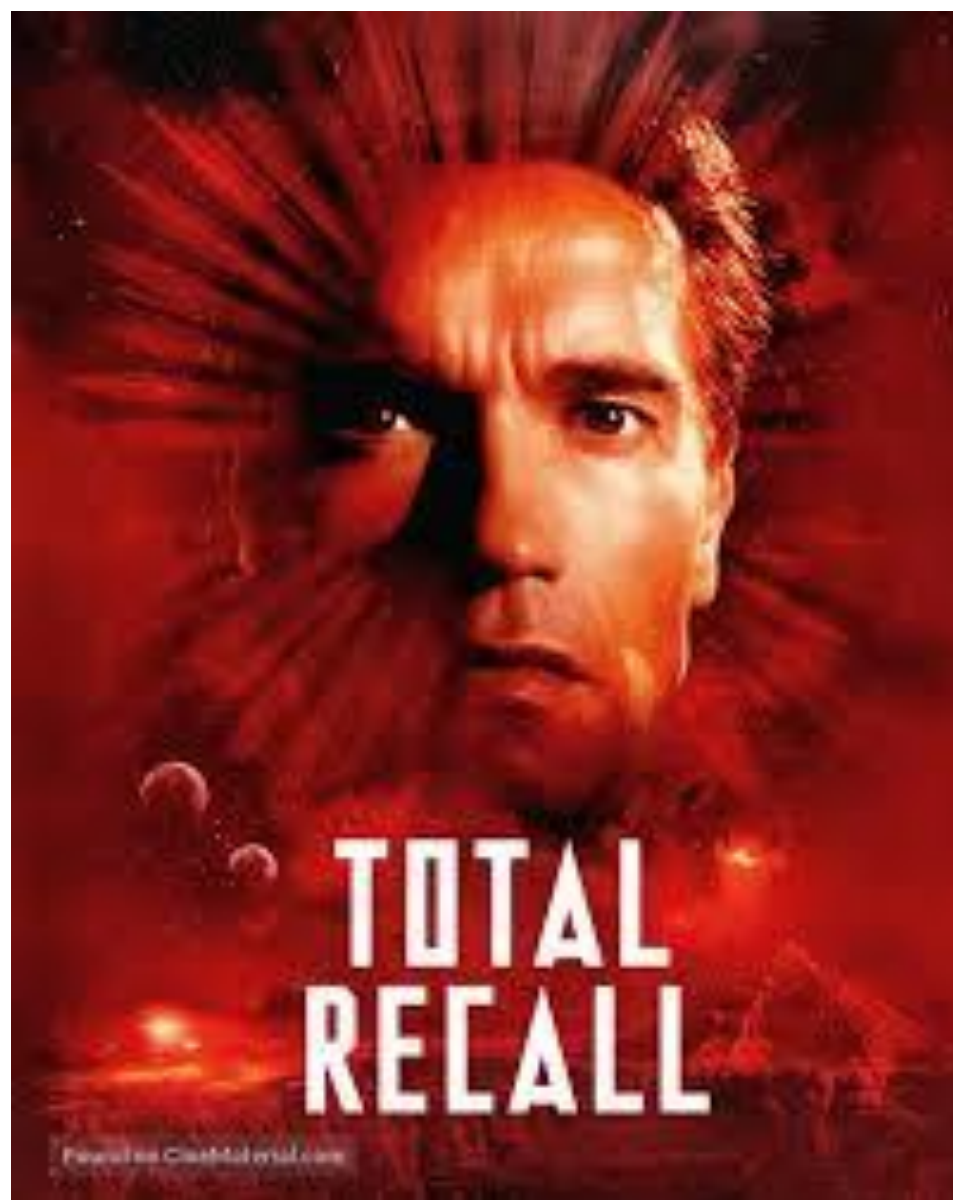
Effect of Damage

- Impaired speech and swallowing;
- inability to protrude tongue if both right and left nerves are damaged;
- deviation of tongue toward injured side,
- and atrophy on that side, if only one nerve is damaged



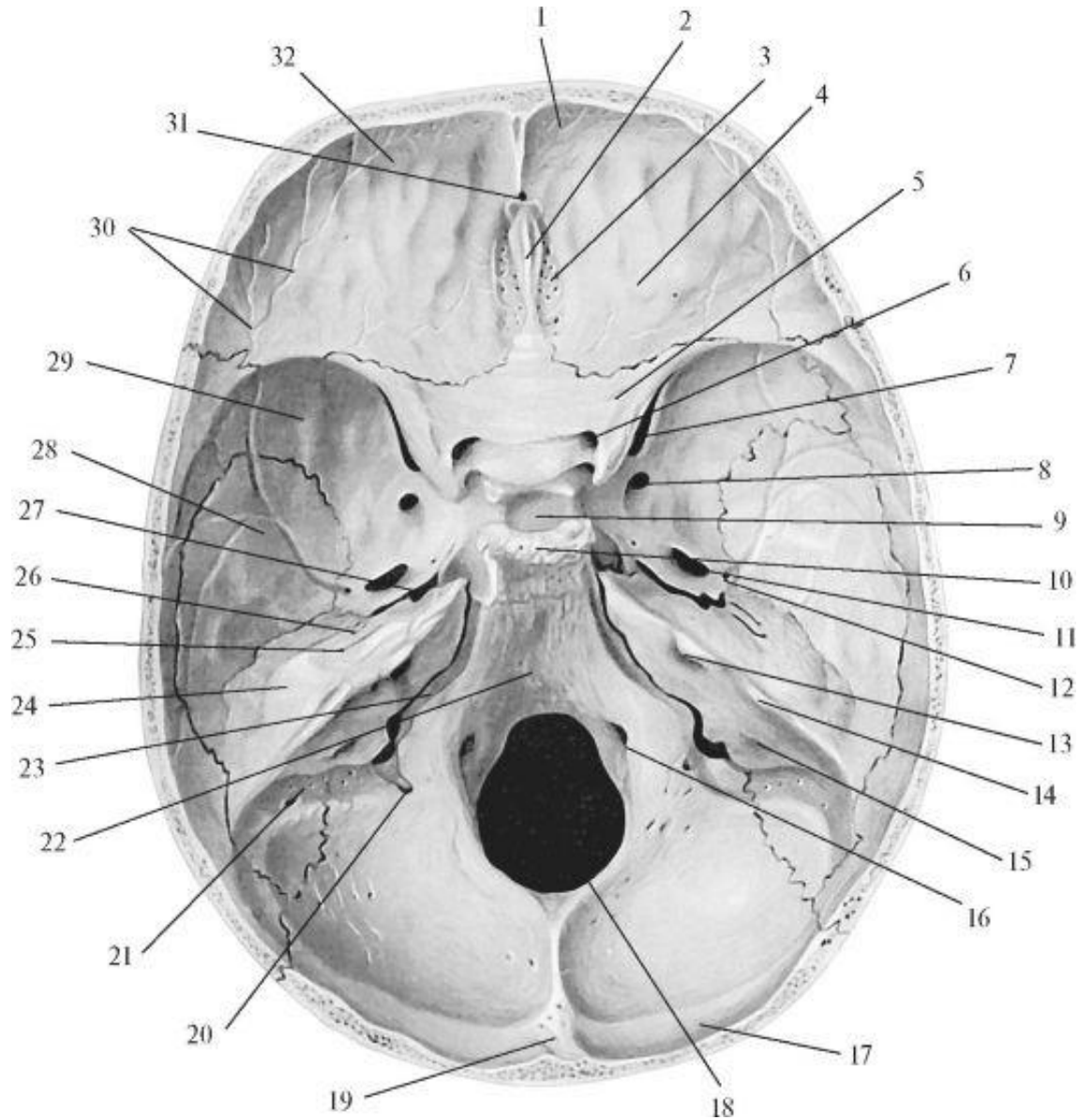
Points to Remember

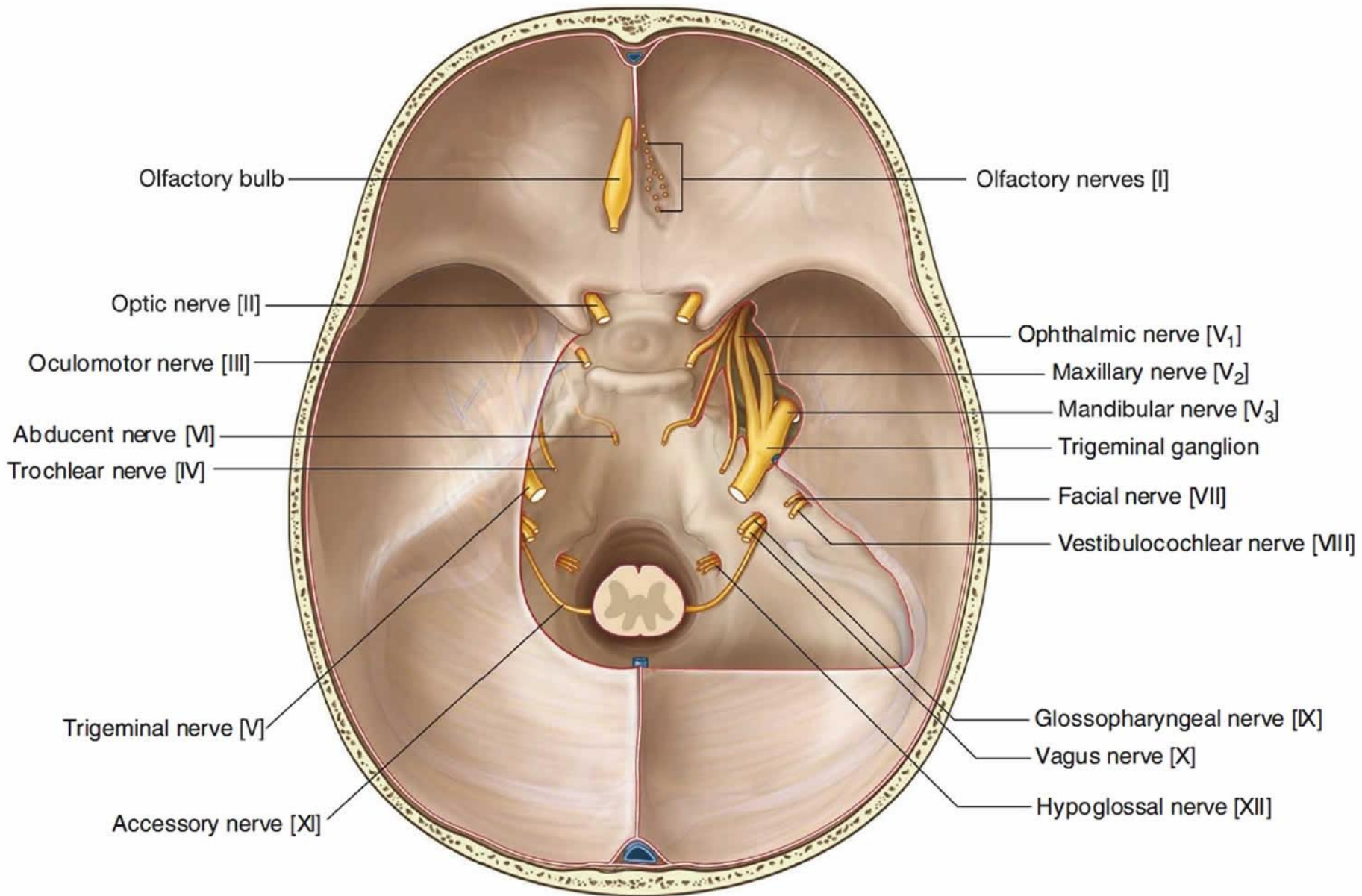
- Cranial nerves are part of the peripheral nervous system.
- Carry sensory or motor information or a combination and function in parasympathetic nervous system.
- Cranial nerves I, II and VIII are purely sensory.
- Cranial nerves III, IV, VI, XI and XII are motor (although also function for proprioception).



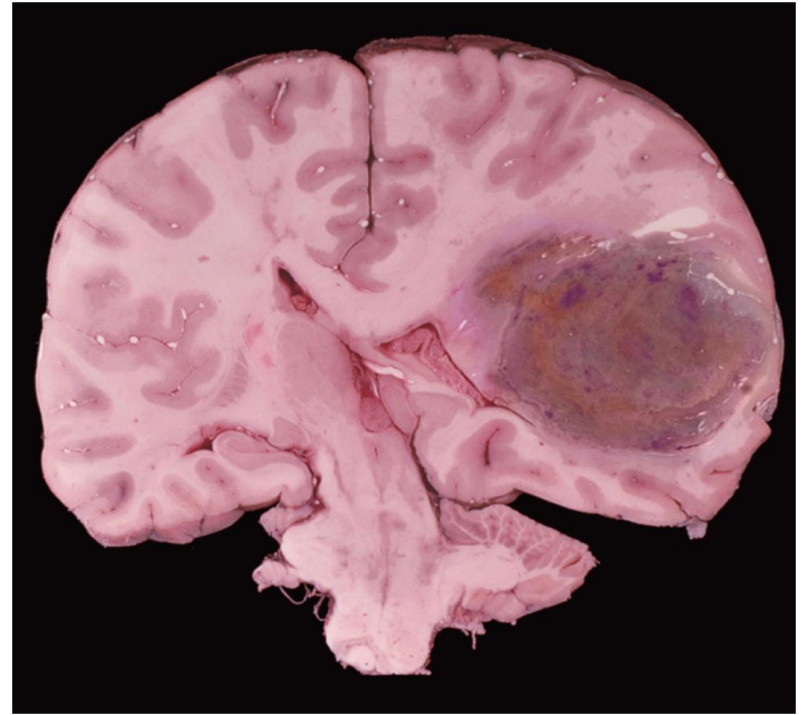
Short Quiz

Let's recall the main outputs of the cranial nerves





Brain I



Overview of the Brain Meninges, Ventricles, Cerebrospinal Fluid, and Blood Supply

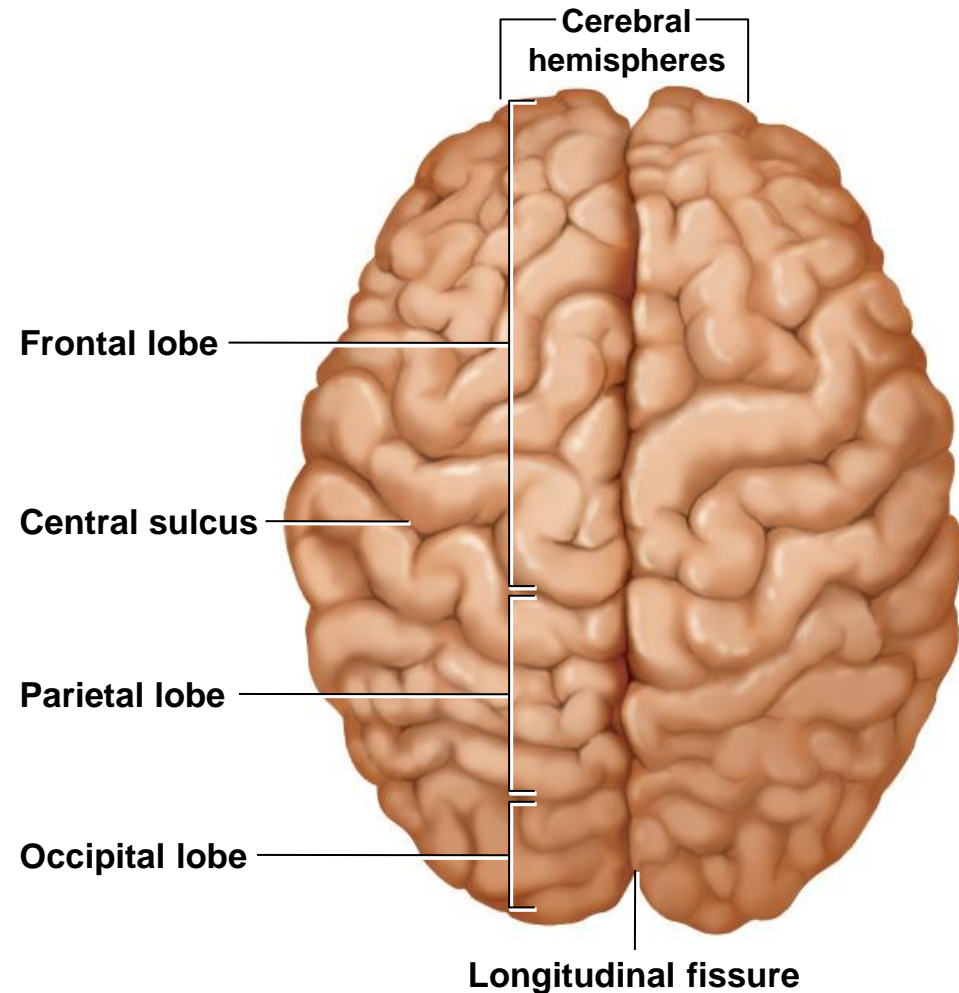
Learning Outcomes

- describe the major subdivisions and anatomical landmarks of the brain;
- describe the locations of its gray and white matter;
- describe the embryonic development of the CNS relate this to adult brain anatomy
- describe the meninges of the brain;
- describe the fluid-filled chambers within the brain;
- discuss the production, circulation, and function of the cerebrospinal fluid that fills these chambers;
- explain the significance of the brain barrier system

Central Nervous System

- overview of the brain
- meninges, ventricles, cerebrospinal fluid and blood supply
- hindbrain and midbrain
- forebrain
- integrative functions
- the cranial nerves

Anatomy & Physiology: The Unity of Form and Function McGraw-Hill Education; 8th Edition



(a) Superior view

Figure 14.1a

Introduction to the Nervous System

- Aristotle thought brain was 'radiator' to cool blood
- Hippocrates was more accurate, "*from the brain only, arises our pleasures, joys, laughter, and jests, as well as our sorrows, pains, griefs, and tears*"
- cessation of brain activity - clinical criterion of death
- evolution of the central nervous system shows spinal cord very little changed while brain has changed a great deal.
 - greatest growth in areas of vision, memory, and motor control of the prehensile hand.

Directional Terms and Landmarks

- **rostral** - toward the forehead
- **caudal** - toward the spinal cord
- brain weighs about 1600 g (3.5 lb) in men, and 1450 g in women
- three major portions of the brain - **cerebrum, cerebellum, brainstem**
 - **cerebrum** is 83% of brain volume; cerebral hemispheres, gyri and sulci, longitudinal fissure, corpus callosum
 - **cerebellum** contains 50% of the neurons; second largest brain region, located in posterior cranial fossa
 - **brainstem** the portion of the brain that remains if the cerebrum and cerebellum are removed; diencephalon, midbrain, pons, and medulla oblongata

Anatomy & Physiology: The Unity of Form and Function McGraw-Hill Education; 8th Edition

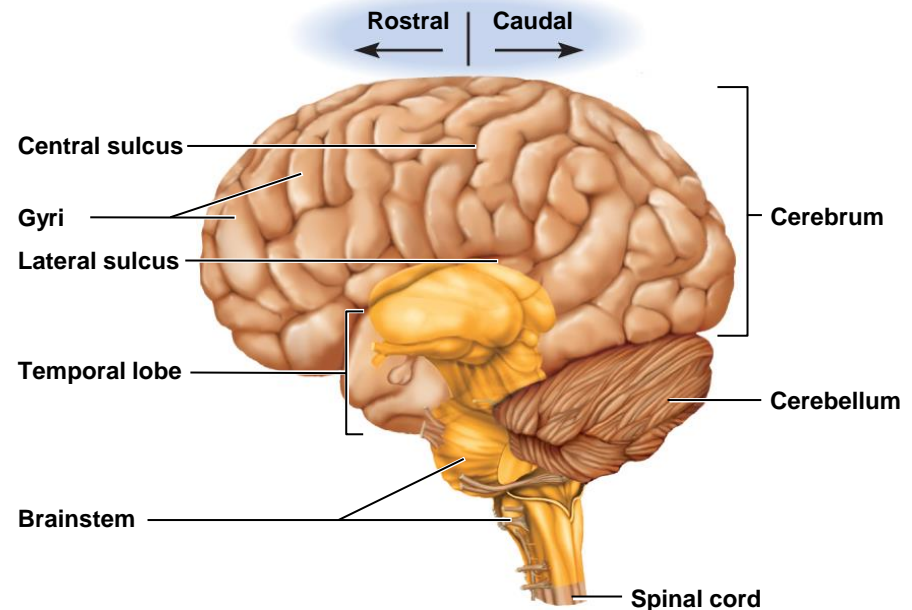


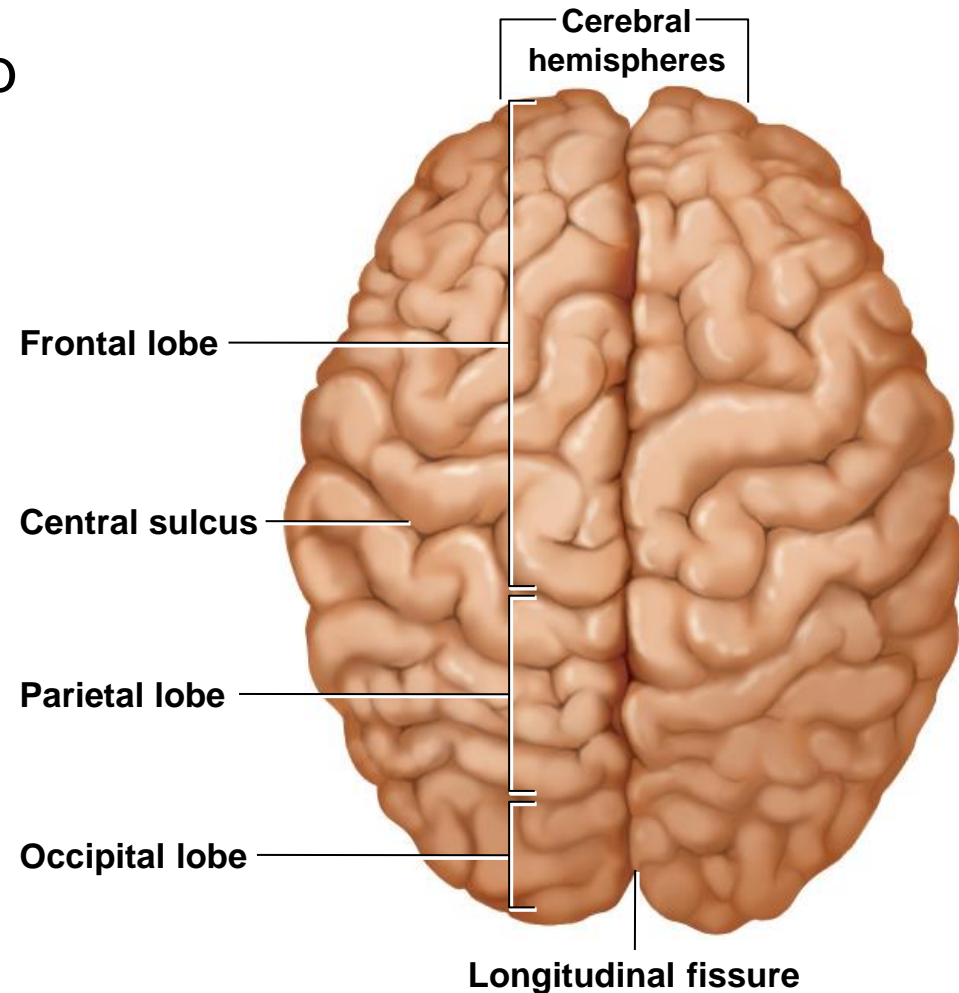
Figure 14.1b

(b) Lateral view

Cerebrum

Anatomy & Physiology: The Unity of Form and Function McGraw-Hill Education; 8th Edition

- **longitudinal fissure** – deep groove that separates cerebral hemispheres
- **gyri** - thick folds
- **sulci** - shallow grooves
- **corpus callosum** – thick nerve bundle at bottom of longitudinal fissure that connects hemispheres



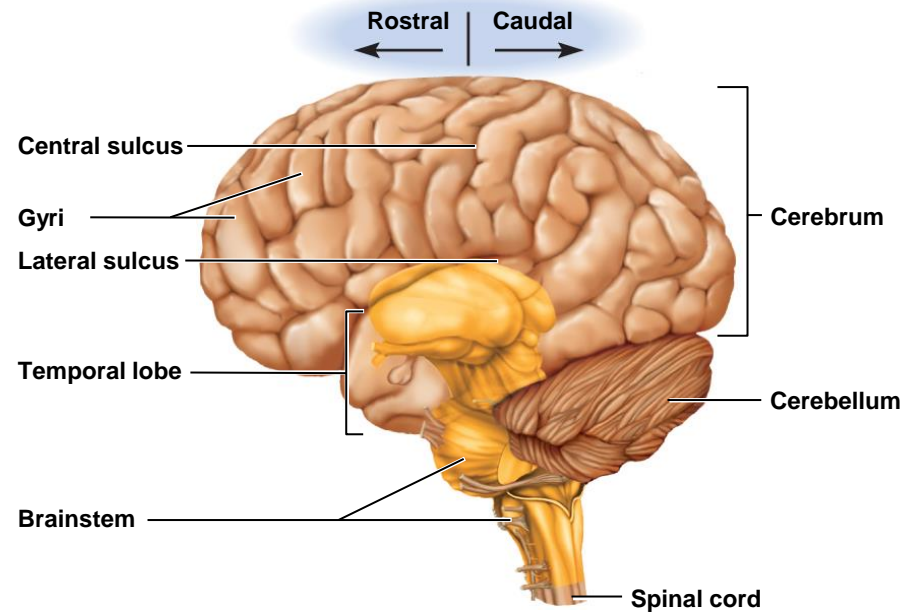
(a) Superior view

Figure 14.1a

Cerebellum

- occupies **posterior cranial fossa**
- marked by **gyri, sulci, and fissures**
- about 10% of brain volume
- contains over 50% of brain neurons

Anatomy & Physiology: The Unity of Form and Function McGraw-Hill Education; 8th Edition



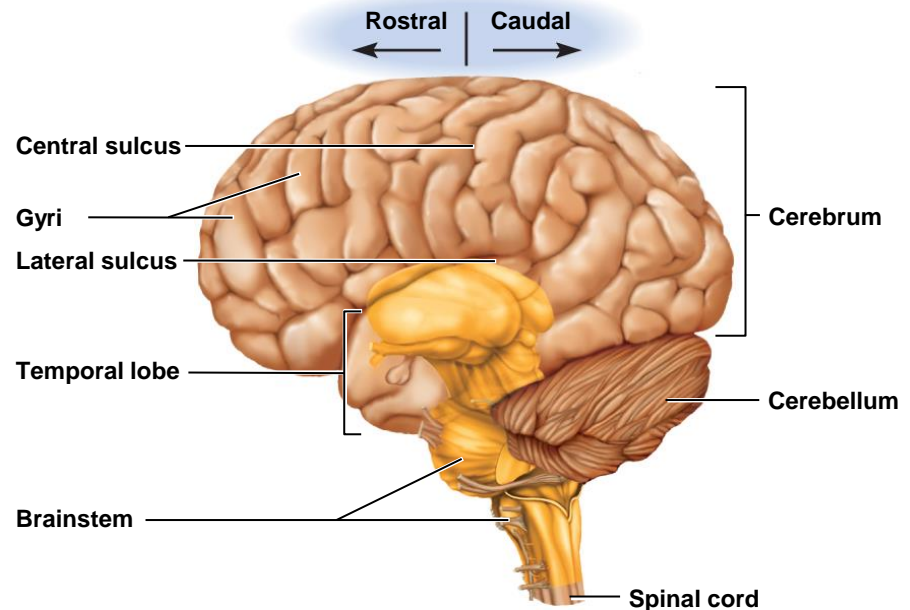
(b) Lateral view

Figure 14.1b

Brainstem

- **brainstem** – what remains of the brain if the cerebrum and cerebellum are removed
- **major components**
 - diencephalon
 - midbrain
 - pons
 - medulla oblongata

Anatomy & Physiology: The Unity of Form and Function McGraw-Hill Education; 8th Edition

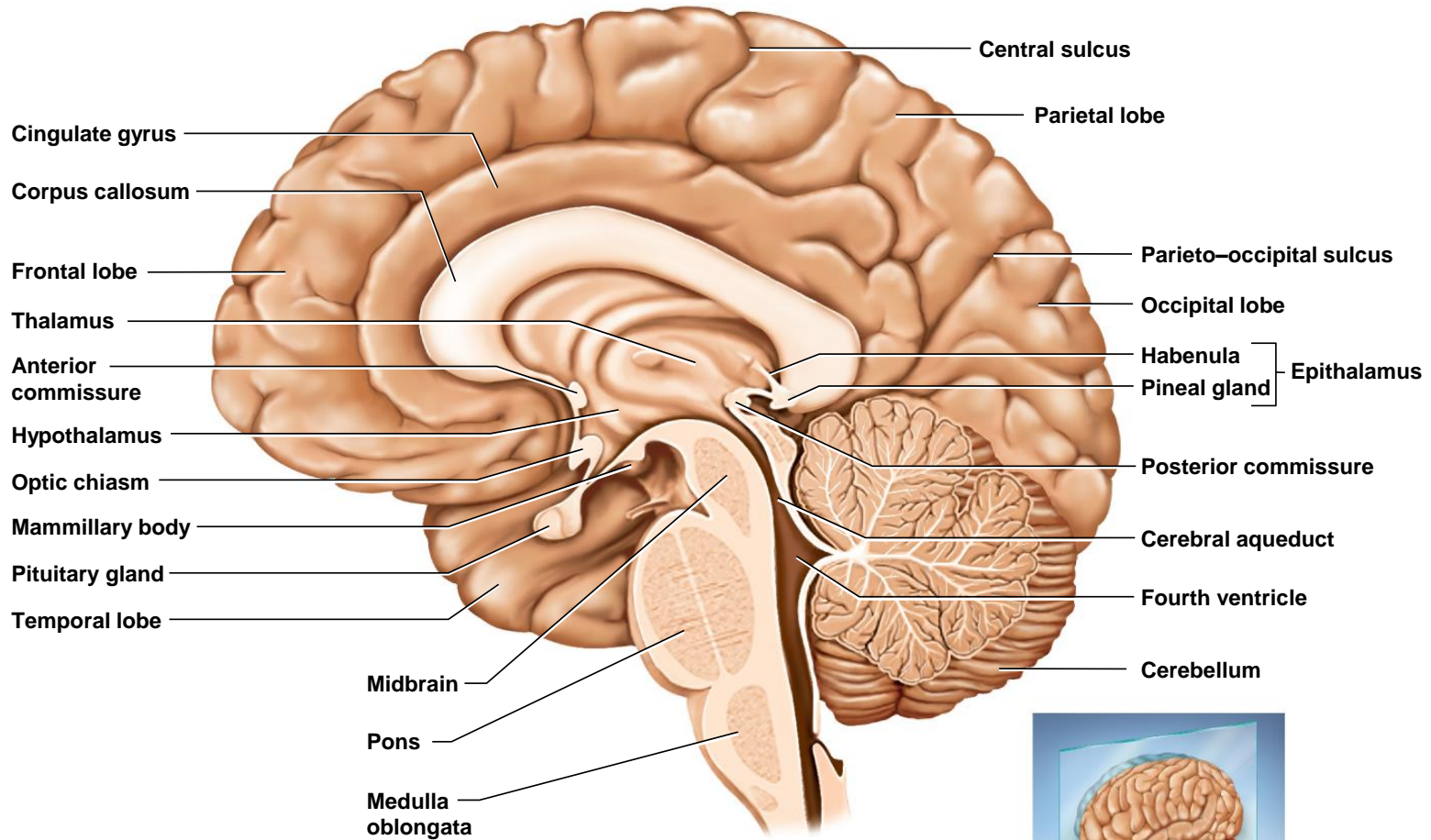


(b) Lateral view

Figure 14.1b

Median Section of the Brain

Anatomy & Physiology: The Unity of Form and Function McGraw-Hill Education; 8th Edition

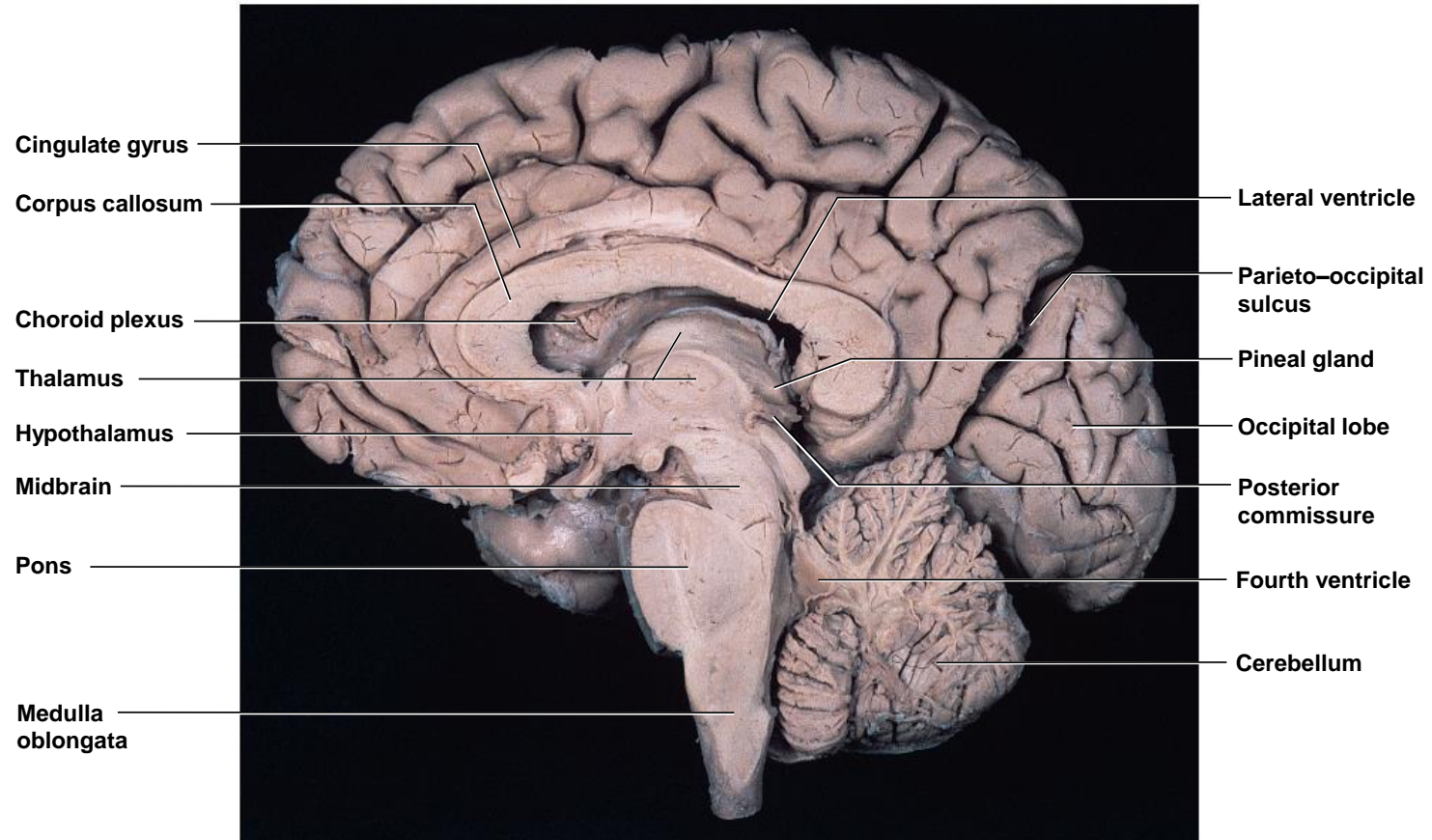


(a)

Figure 14.2a

Median Section of Cadaver Brain

Anatomy & Physiology: The Unity of Form and Function McGraw-Hill Education; 8th Edition



(b)

© The McGraw-Hill Companies, Inc./Dennis Strete, photographer

Figure 14.2b

Gray and White Matter

- **gray matter** – the seat of neuron cell bodies, dendrites, and synapses
 - dull white color when fresh, due to little myelin
 - forms surface layer, **cortex**, over cerebrum and cerebellum
 - forms **nuclei** deep within brain
- **white matter** - bundles of axons
 - lies **deep to cortical gray matter**, opposite relationship in the spinal cord
 - pearly white color from **myelin** around nerve fibers
 - composed of **tracts**, bundles of axons, that connect one part of the brain to another, and to the spinal cord

Embryonic Development

- nervous system develops from **ectoderm**
 - outermost tissue layer of the embryo
- early in third week of development
 - **neuroectoderm** – dorsal streak appears along the length of embryo
 - thickens to form **neural plate**
 - destined to give rise to most neurons and all glial cells except microglia, which come from mesoderm
- as thickening progresses
 - neural plate sinks and its edges thicken
 - forming a **neural groove** with a raised **neural fold** on each side
 - neural folds fuse along the midline
 - beginning in the cervical region and progressing rostrally and caudally

Embryonic Development

- by fourth week, creates a hollow channel – **neural tube**
 - neural tube separates from overlying ectoderm
 - sinks deeper
 - grows lateral processes that later will form motor nerve fibers
 - lumen of neural tube becomes fluid-filled space
 - central canal in spinal cord
 - ventricles of the brain
- **neural crest** – formed from ectodermal cells that lay along of the margins of the groove and separate from the rest forming a longitudinal column on each side
 - gives rise to the two inner **meninges**, most of the **peripheral nervous system**, and other structures of the **skeletal, integumentary, and endocrine** systems

Embryonic Development

- by fourth week, the neural tube exhibits three anterior dilations (primary vesicles)
 - **forebrain** (prosencephalon)
 - **midbrain** (mesencephalon)
 - **hindbrain** (rhombencephalon)
- by fifth week, it subdivides into five secondary vesicles
 - **forebrain** divides into two of them
 - **telencephalon** – becomes cerebral hemispheres
 - **diencephalon** – has optic vesicles that becomes retina of the eye
 - **midbrain** remains undivided and remains
 - **mesencephalon**
 - **hind brain** divides into two vesicles
 - **metencephalon**
 - **myelencephalon**

Embryonic Neural Tube

Anatomy & Physiology: The Unity of Form and Function McGraw-Hill Education; 8th Edition

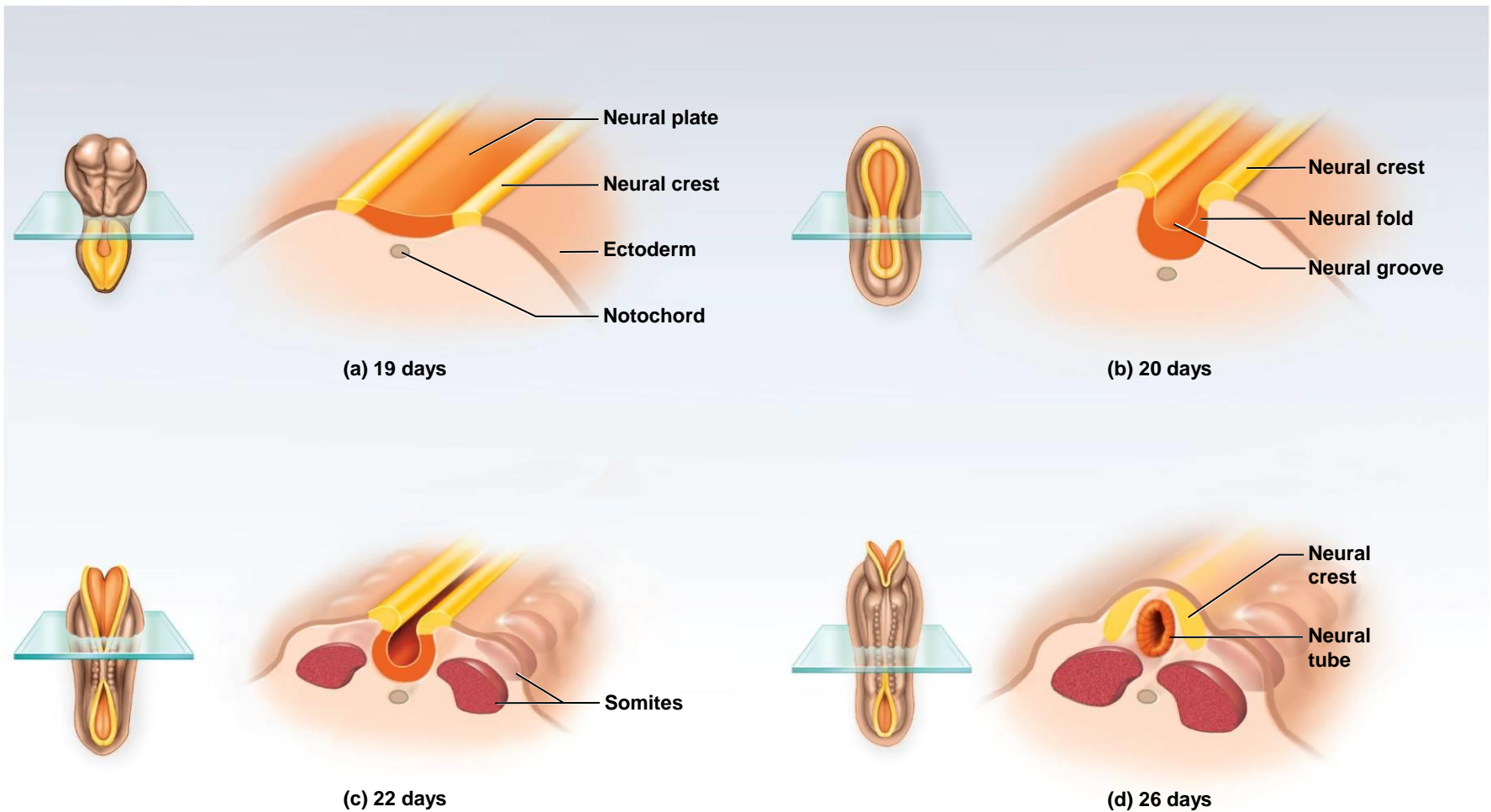
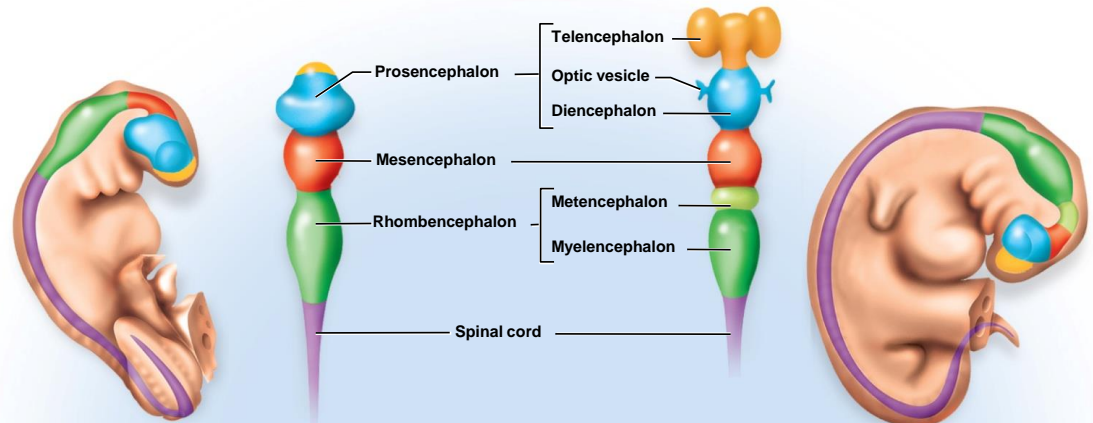


Figure 14.3

Embryonic Brain Development

Anatomy & Physiology: The Unity of Form and Function McGraw-Hill Education; 8th Edition

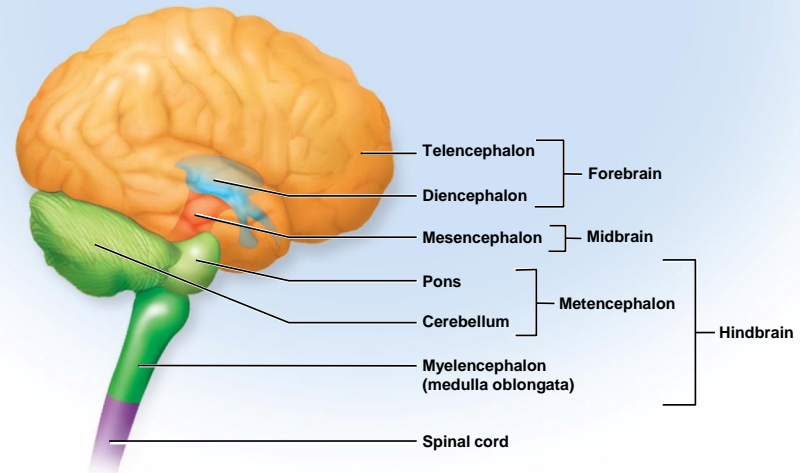
- 4th week
 - forebrain
 - midbrain
 - hindbrain



(a) 4 weeks

(b) 5 weeks

- 5th week
 - telencephalon
 - diencephalon
 - mesencephalon
 - metencephalon
 - myelencephalon



(c) Fully developed

Figure 14.4

Meninges

- **meninges** – three connective tissue membranes that envelop the brain
 - lies between the nervous tissue and bone
 - as in spinal cord, they are the **dura mater**, **arachnoid mater**, and the **pia mater**
 - protect the brain and provide structural framework for its arteries and veins
- **dura mater**
 - in cranial cavity - **2 layers**
 - outer **periosteal** – equivalent to periosteum of cranial bones
 - inner **meningeal** – continues into vertebral canal and forms dural sac around spinal cord
 - cranial dura mater is pressed closely against cranial bones
 - no epidural space
 - not attached to bone except: around **foramen magnum**, **sella turcica**, the **crista galli**, and **sutures of the skull**
 - layers separated by **dural sinuses** – collect blood circulating through brain
 - folds inward to extend between parts of the brain
 - **falx cerebri** separates the two cerebral hemispheres
 - **tentorium cerebelli** separates cerebrum from cerebellum
 - **falx cerebelli** separates the right and left halves of cerebellum

Meninges

- arachnoid mater and pia mater are similar to those in the spinal cord
- **arachnoid mater**
 - transparent membrane over brain surface
 - **subarachnoid space** separates it from pia mater below
 - **subdural space** separates it from dura mater above in some places
- **pia mater**
 - very thin membrane that follows contours of brain, even dipping into sulci
 - not usually visible without a microscope

Meninges of the Brain

Anatomy & Physiology: The Unity of Form and Function McGraw-Hill Education; 8th Edition

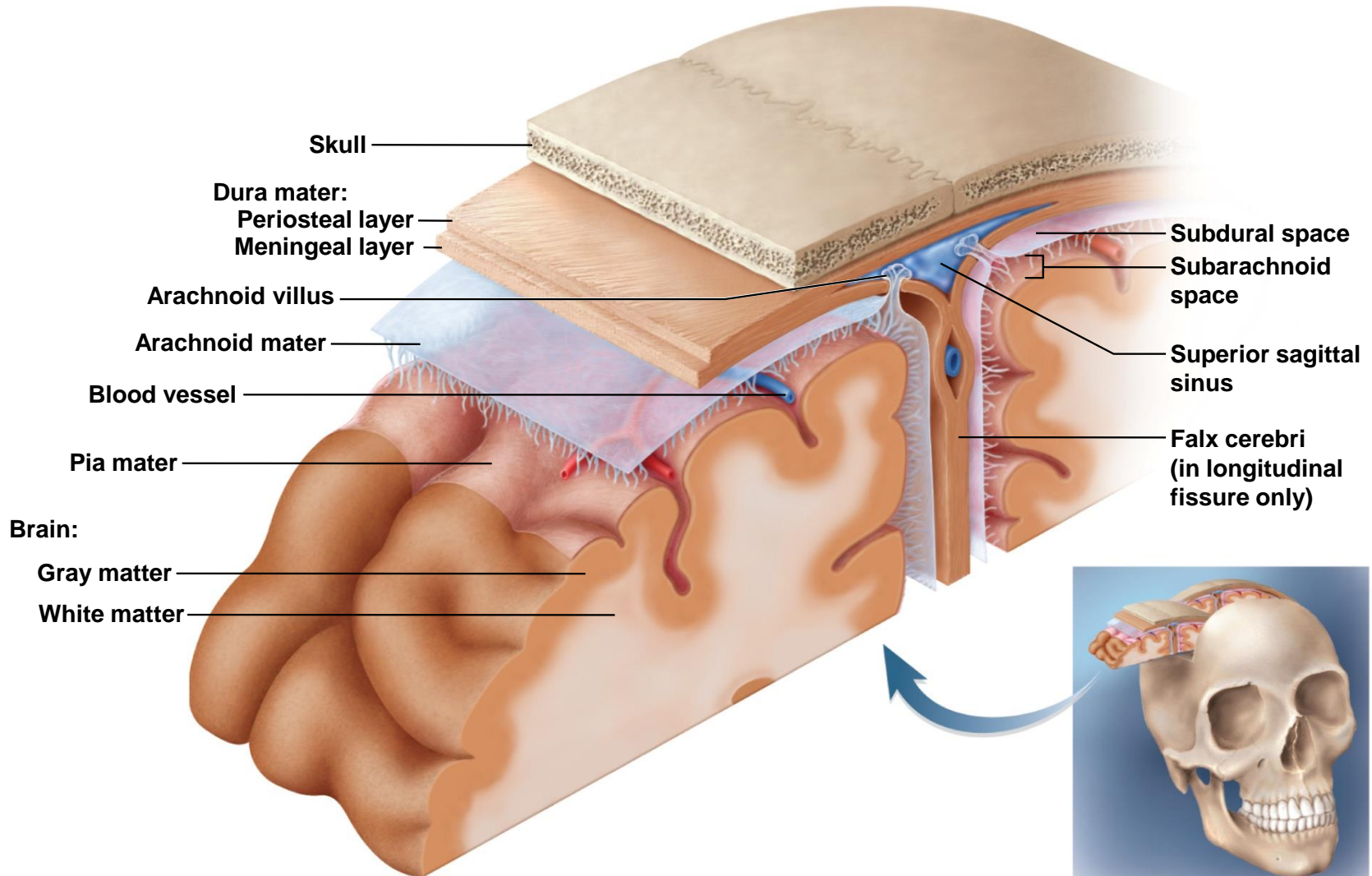


Figure 14.5

Meningitis

- **meningitis** - inflammation of the meninges
 - serious disease of infancy & childhood
 - especially between 3 months and 2 years of age
- caused by bacterial and virus invasion of the CNS by way of the nose and throat
- pia mater and arachnoid are most often affected
- **bacterial meningitis** can cause swelling the brain, enlarging the ventricles, and hemorrhage
- **signs** include high fever, stiff neck, drowsiness, and intense headache and may progress to coma – death within hours of onset
- diagnosed by examining the CSF for bacteria
 - **lumbar puncture (spinal tap)** draws fluid from subarachnoid space between two lumbar vertebrae

Brain Ventricles

Anatomy & Physiology: The Unity of Form and Function McGraw-Hill Education; 8th Edition

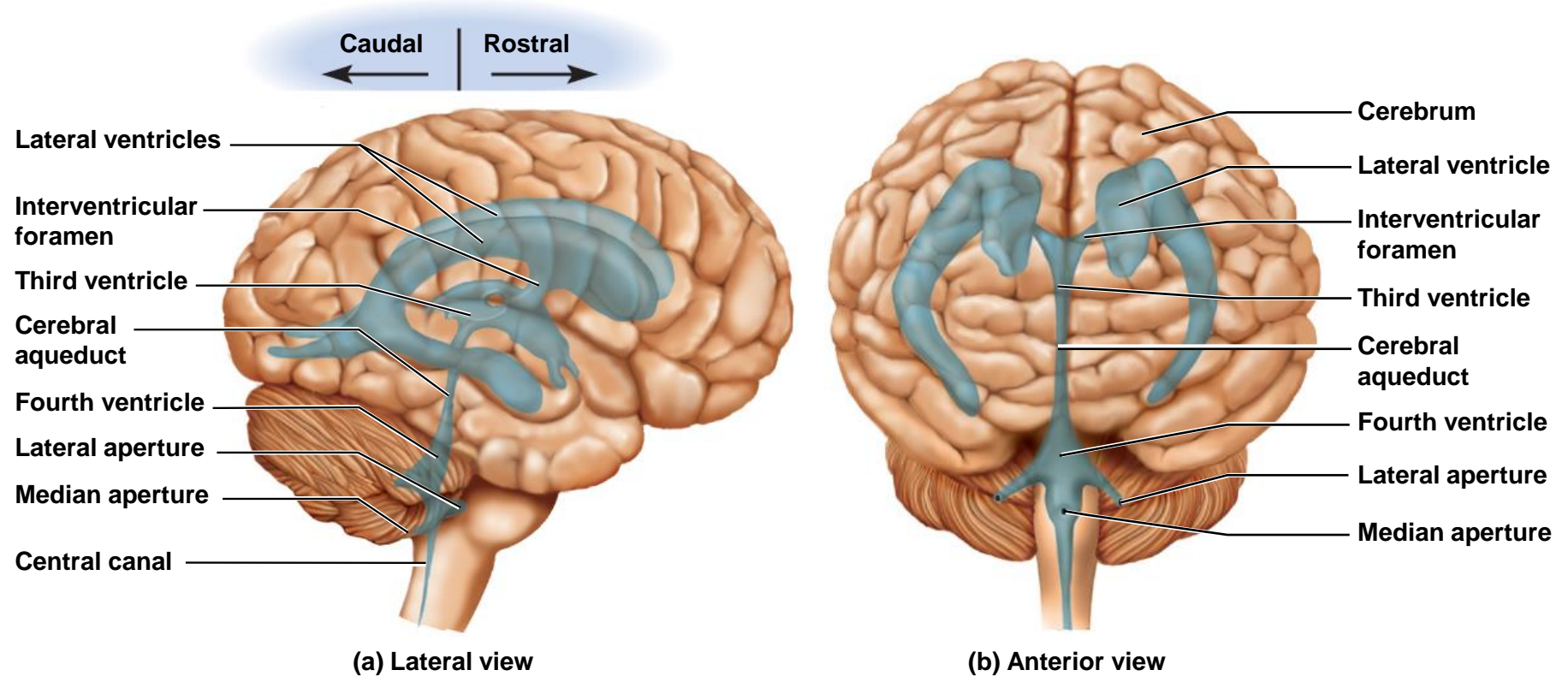


Figure 14.6 a-b

Ventricles of the Brain

Anatomy & Physiology: The Unity of Form and Function McGraw-Hill Education; 8th Edition

Rostral (anterior)

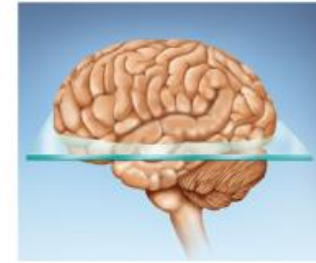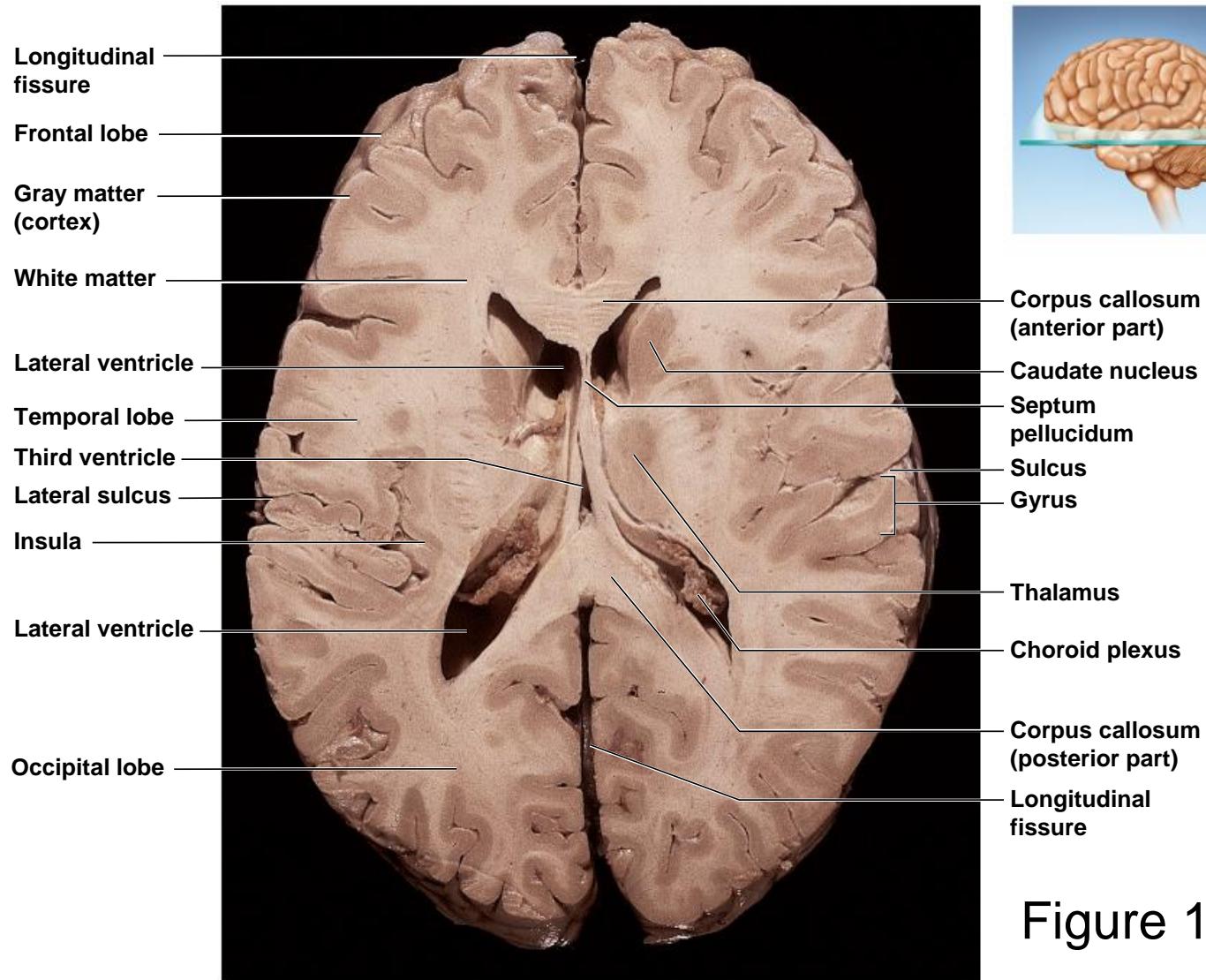


Figure 14.6c

(c)

Caudal (posterior)

Ventricles and Cerebrospinal Fluid

- **ventricles** – four internal chambers within the brain
 - two **lateral ventricles** – one in each cerebral hemisphere
 - **interventricular foramen** - a tiny pore that connects to third ventricle
 - **third ventricle** - single narrow medial space beneath corpus callosum
 - **cerebral aqueduct** runs through midbrain and connects third to fourth ventricle
 - **fourth ventricle** – small triangular chamber between pons and cerebellum
 - connects to **central canal** runs down through spinal cord
- **choroid plexus** – spongy mass of blood capillaries on the floor of each ventricle
- **ependyma** – neuroglia that lines the ventricles and covers choroid plexus
 - produces cerebrospinal fluid

Cerebrospinal Fluid (CSF)

- **cerebrospinal fluid (CSF)** – clear, colorless liquid that fills the ventricles and canals of CNS
 - bathes its external surface
- brain produces and absorbs 500 mL/day
 - 100 – 160 mL normally present at one time
 - 40% formed in subarachnoid space external to brain
 - 30% by the general ependymal lining of the brain ventricles
 - 30% by the choroid plexuses
- production begins with the filtration of blood plasma through the capillaries of the brain
 - ependymal cells modify the filtrate, so CSF has more sodium and chloride than plasma, but less potassium, calcium, glucose, and very little protein

Cerebrospinal Fluid (CSF) Circulation

- CSF continually flows through and around the CNS
 - driven by its own pressure, beating of ependymal cilia, and pulsations of the brain produced by each heartbeat
- CSF secreted in **lateral ventricles** flows through **intervertebral foramina** into **third ventricle**
- then down the **cerebral aqueduct** into the **fourth ventricle**
- third and fourth ventricles add more CSF along the way
- small amount of CSF fills the **central canal of the spinal cord**
 - all escapes through three pores
 - **median aperture** and **two lateral apertures**
 - leads into **subarachnoid space** of brain and spinal cord surface
- CSF is reabsorbed by **arachnoid villi**
 - cauliflower-shaped extension of the **arachnoid meninx**
 - protrudes through dura mater
 - into **superior sagittal sinus**
 - CSF penetrates the walls of the villi and mixes with the blood in the sinus

Functions of CSF

- **buoyancy**
 - allows brain to attain considerable size without being impaired by its own weight
 - if it rested heavily on floor of cranium, the pressure would kill the nervous tissue
- **protection**
 - protects the brain from striking the cranium when the head is jolted
 - **shaken child syndrome** and **concussions** do occur from severe jolting
- **chemical stability**
 - flow of CSF rinses away metabolic wastes from nervous tissue and homeostatically regulates its chemical environment

Flow of Cerebrospinal Fluid

Anatomy & Physiology: The Unity of Form and Function McGraw-Hill Education; 8th Edition

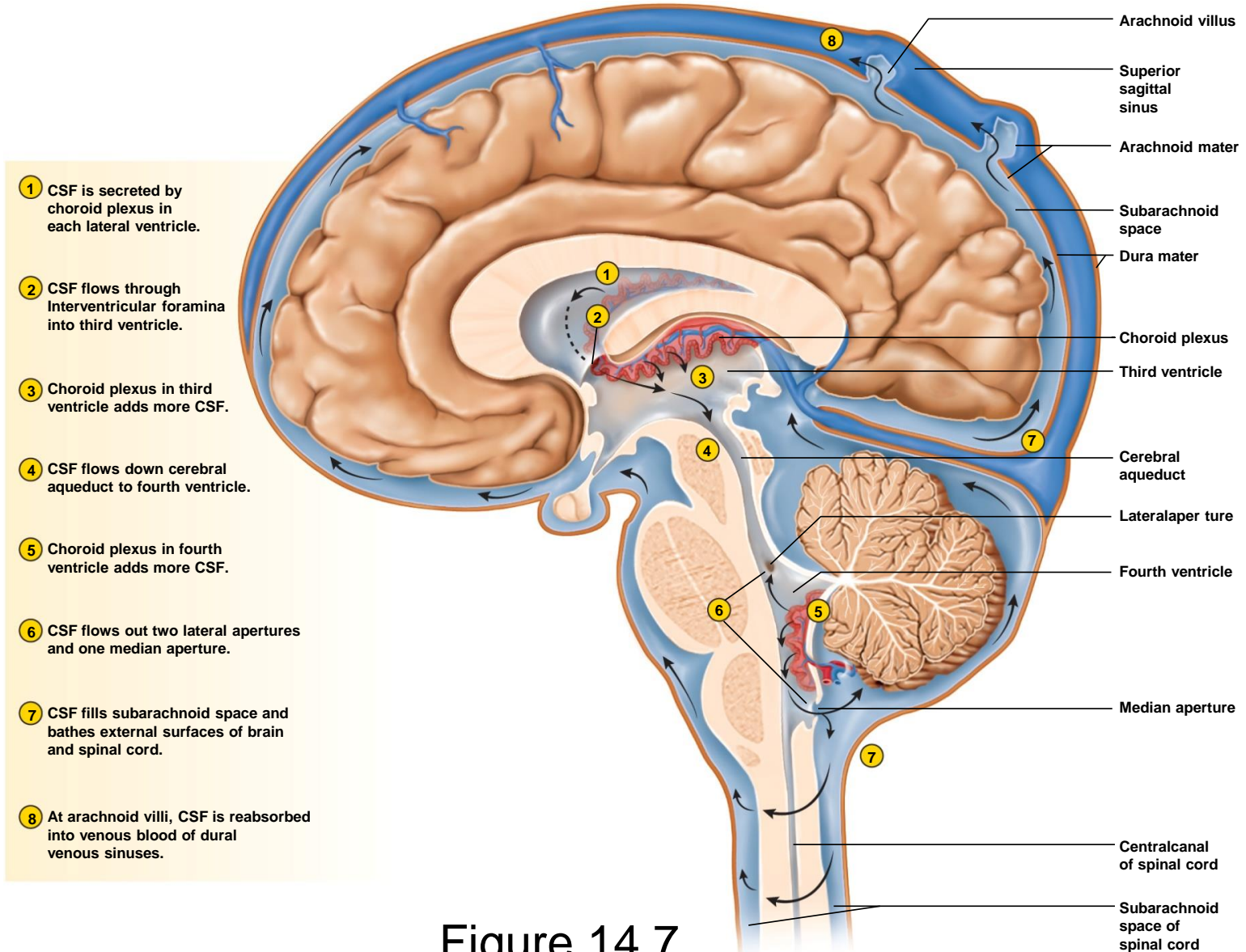


Figure 14.7

Blood Supply to the Brain

- brain is only 2% of the adult body weight, and receives 15% of the blood
 - 750 mL/min
- neurons have a high demand for ATP, and therefore, oxygen and glucose, so a constant supply of blood is critical to the nervous system
 - 10 second interruption of blood flow may cause loss of consciousness
 - 1 – 2 minute interruption can cause significant impairment of neural function
 - 4 minutes with out blood causes irreversible brain damage

Brain Barrier System

- blood is also a source of antibodies, macrophages, bacterial toxins, and other harmful agents
- **brain barrier system** – strictly regulates what substances can get from the bloodstream into the tissue fluid of the brain
- two points of entry must be guarded:
 - blood capillaries throughout the brain tissue
 - capillaries of the choroid plexus
- **blood-brain barrier** - protects blood capillaries throughout brain tissue
 - consists of tight junctions between endothelial cells that form the capillary walls
 - **astrocytes** reach out and contact capillaries with their perivascular feet
 - induce the endothelial cells to form tight junctions that completely seal off gaps between them
 - anything leaving the blood must pass through the cells, and not between them
 - **endothelial cells** can exclude harmful substances from passing to the brain tissue while allowing necessary ones to pass

Brain Barrier System

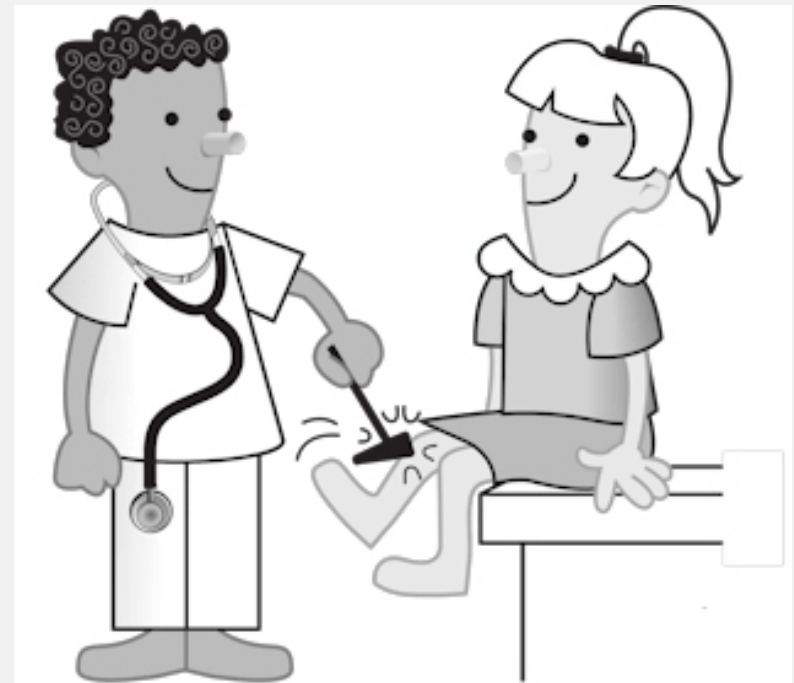- **blood-CSF barrier** - protects the brain at the choroid plexus
 - form tight junctions between the ependymal cells
 - tight junctions are absent from ependymal cells elsewhere
 - important to allow exchange between brain tissue and CSF
- **blood barrier system** is **highly permeable** to water, glucose, and lipid-soluble substances such as oxygen, carbon dioxide, alcohol, caffeine, nicotine, and anesthetics
- **slightly permeable** to sodium, potassium, chloride, and the waste products urea and creatinine
- obstacle for delivering medications such as antibiotics and cancer drugs
- trauma and inflammation can damage BBS and allow pathogens to enter brain tissue
 - **circumventricular organs (CVOs)** – places in the third and fourth ventricles where the barrier is absent
 - blood has direct access to the brain
 - enables the brain to monitor and respond to fluctuations in blood glucose, pH, osmolarity, and other variables
 - CVOs afford a route for invasion by the human immunodeficiency virus (HIV) **14-30**



**Al-Farabi Kazakh
National
University
Higher School of
Medicine**

The Spinal Cord, Spinal Nerves, and Somatic Reflexes

Somatic Reflexes



LEARNING OUTCOMES

When you have completed this section, you should be able to:

- a. define reflex and explain how reflexes differ from other motor actions;*
- b. describe the general components of a typical reflex arc;*
- c. explain how the basic types of somatic reflexes function.*



◆ Introduction

- Most of us have had our reflexes tested with a little rubber hammer; a tap below the knee produces an uncontrollable jerk of the leg, for example. In this section, we discuss what reflexes are and how they are produced by an assembly of receptors, neurons, and effectors. We also survey the different types of **neuromuscular reflexes** and how they are important in motor coordination of our everyday tasks.

◆ The Nature of Reflexes

Reflexes are quick, involuntary, stereotyped reactions of glands or muscles to stimulation. This definition sums up **four important properties**:

1. **Reflexes require stimulation**—they are not spontaneous actions like muscle tics but responses to sensory input.
2. **Reflexes are quick**—they generally involve only a few interneurons, or none, and minimum synaptic delay.



3. **Reflexes are *involuntary***—they occur without intent, often without our awareness, and they are difficult to suppress. Given an adequate stimulus, the response is essentially automatic. You may become conscious of the stimulus that evoked a reflex, and this awareness may enable you to correct or avoid a potentially dangerous situation, but awareness is not a part of the reflex itself. It may come after the reflex action has been completed, and somatic reflexes can occur even if the spinal cord has been severed so that no stimuli reach the brain.

4. **Reflexes are *stereotyped***—they occur in essentially the same way every time; the response is very predictable, like the variability of voluntary movement.



- Reflexes include glandular secretion and contractions of all three types of muscle. The reflexes of skeletal muscle are called somatic reflexes, since they involve the somatic nervous system.
- Somatic reflexes have traditionally been called spinal reflexes, but this is a misleading expression for two reasons:
 - (1) Spinal reflexes are not exclusively somatic; visceral reflexes also involve the spinal cord.
 - (2) Some somatic reflexes are mediated more by the brain than by the spinal cord.



A somatic reflex employs a **reflex arc**, in which signals travel along the following pathway (fig. 13.20):

1. *somatic receptors* in the skin, muscles, and tendons;
2. *afferent nerve fibers*, which carry information from these receptors to the posterior horn of the spinal cord or to the brainstem;
3. *an integrating center*, a point of synaptic contact between neurons in the gray matter of the cord or brainstem;
4. *efferent nerve fibers*, which carry motor impulses to the muscles;
5. *effectors*, the muscles that carry out the response.



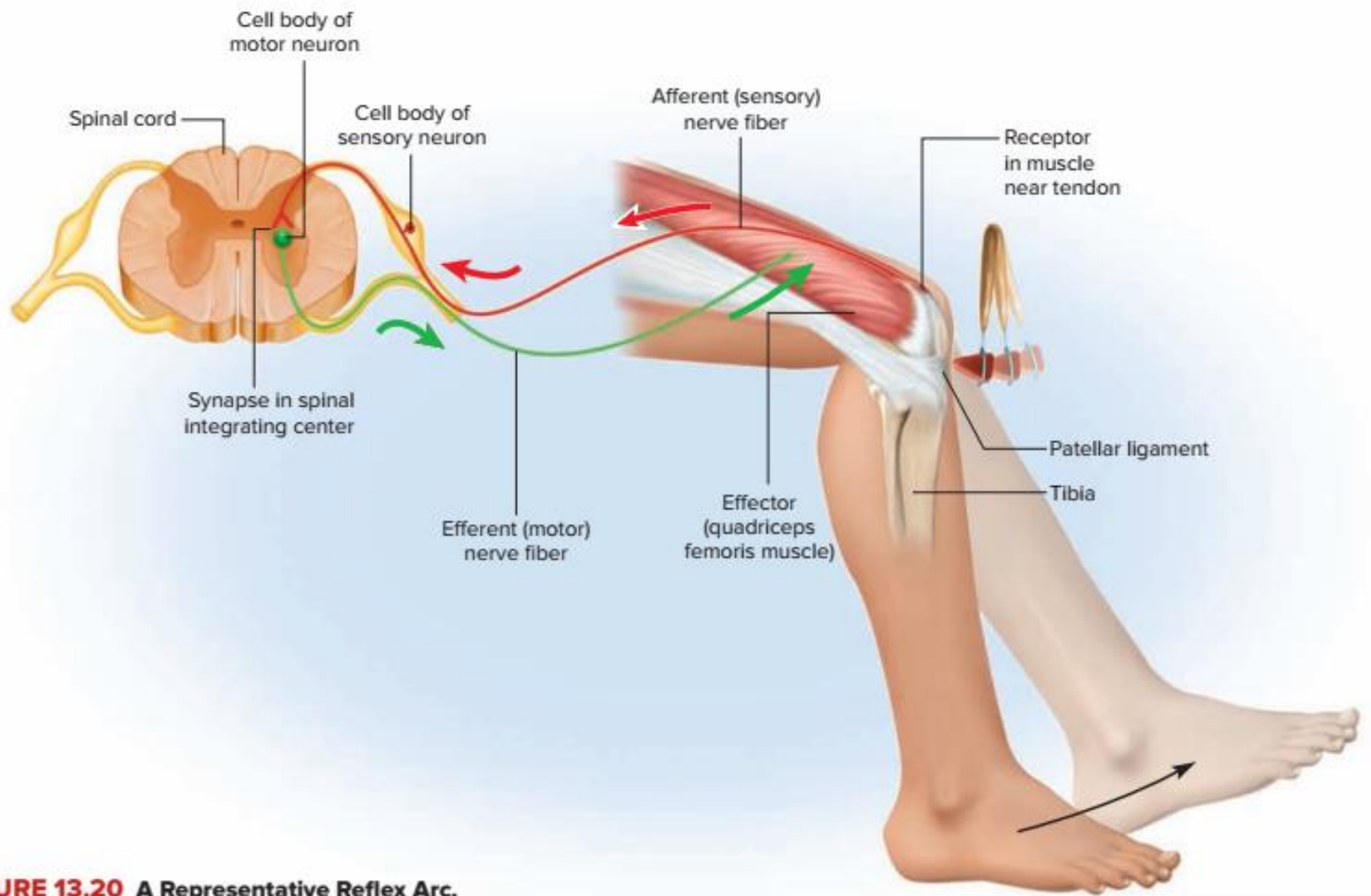


FIGURE 13.20 A Representative Reflex Arc.



In most reflex arcs, the integrating center includes one or more interneurons. Synaptic events in the integrating center determine whether the efferent neurons issue signals to the muscles.

The more interneurons there are, the more complex the information processing can be, but with more synapses, there is a longer delay between input and output.



◆ The Muscle Spindle

- Many somatic reflexes involve stretch receptors called **muscle spindles** embedded in the muscles.
- These are among the body's **proprioceptors**, sense organs specialized to monitor the position and movement of body parts.
- The function of muscle spindles is to *inform the brain of muscle length and body movements*. This enables the brain to send motor commands back to the muscles that control muscle tone, posture, coordinated movement, and corrective reflexes (for example, to keep one's balance).

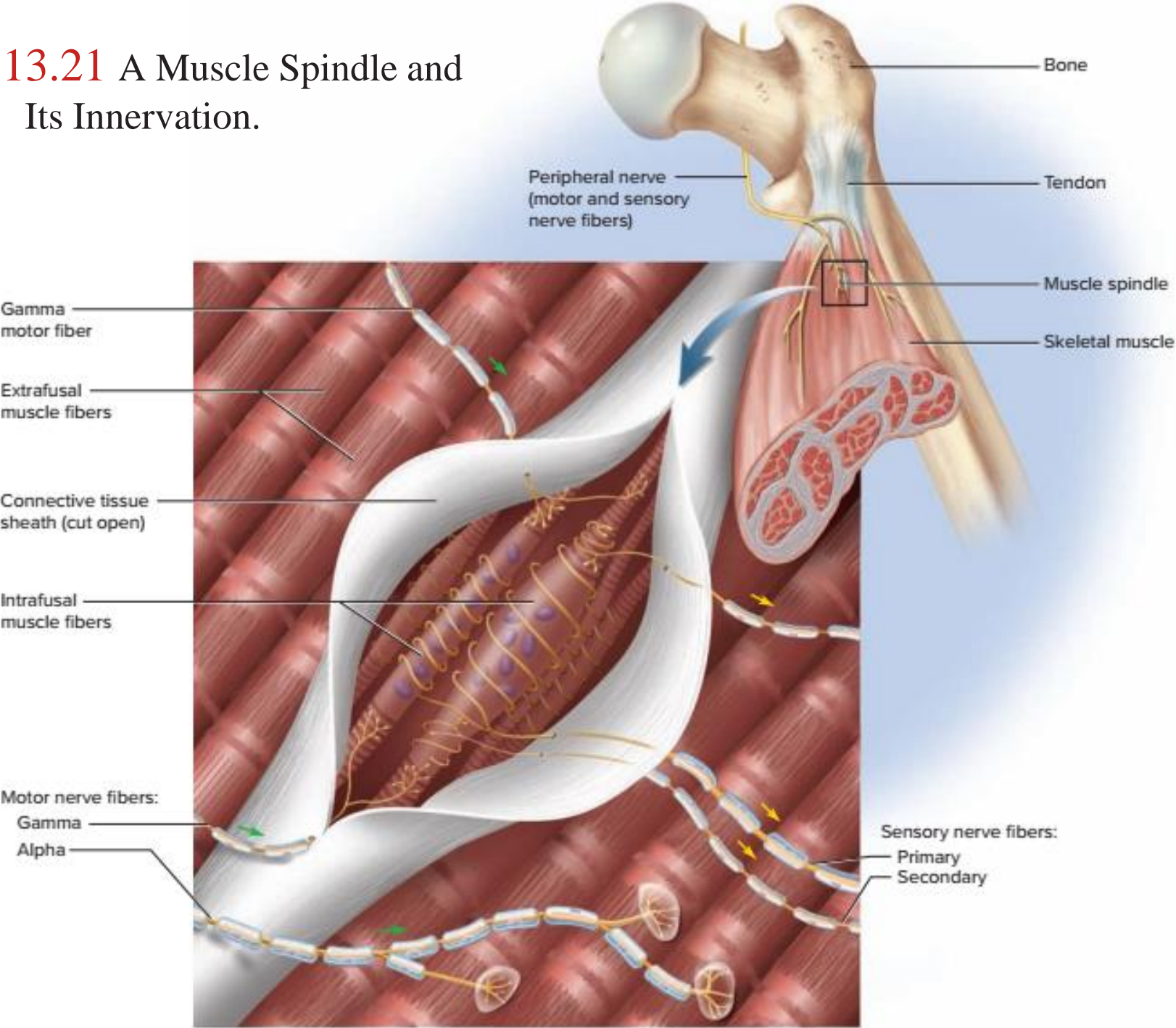
- Spindles are especially abundant in muscles that require *fine control*.
- Hand and foot muscles *have 100 or more spindles per gram of muscle*, whereas there are relatively few in large muscles with coarse movements, and none at all in the middle-ear muscles.



- A muscle spindle is a bundle of usually seven or eight small, modified muscle fibers enclosed in an elongated fibrous capsule about 5 to 10 mm long (fig. 13.21).
- Spindles are especially concentrated at the ends of a muscle, near its tendons.
- The modified muscle fibers within the spindle are called **intrafusals²⁶ fibers**, whereas those that make up the rest of the muscle and do its work are called **extrafusals fibers**.

²⁶*intra* = within; *fus* = spindle

FIGURE 13.21 A Muscle Spindle and Its Innervation.



- Each end of an intrafusal fiber has a few sarcomeres. A **gamma motor neuron** of the spinal cord innervates each end and stimulates its contraction. This maintains *tension* and *sensitivity* of the intrafusal fiber, *preventing* it from going slack like an unstretched rubber band when a muscle shortens.



- Spinal motorneurons that supply the extrafusal muscle fibers are called **alpha motor neurons**. Up to now, we have studied only that type and the neuromuscular junctions they form with muscle, but nearly one-third of all spinal motor neurons are the gamma type — evidence of the great importance of muscle spindles.



- The long midportion of an intrafusal fiber lacks sarcomeres and cannot contract, but is supplied by **two types of sensory nerve fibers**: *primary afferent fibers* that monitor muscle length and how rapidly it changes, which are therefore very responsive to sudden body movements; and *secondary afferent fibers* that monitor length only, not rate of change.



- Both of these sensory fiber types enter the posterior horn of the spinal cord, synapse on the alpha motor neurons and regulate their firing, and also send branches up the spinal cord to the brain. Through these fibers, the brain constantly but subconsciously monitors the length and tension of nearly every skeletal muscle throughout the body. This input is vital to the maintenance of posture, fine control of movements, and corrective reflexes.



- **FOR EXAMPLE**, you are standing on the deck of a boat that is gently rocking on the waves. At one moment, your body begins to tip forward. This stretches your calf muscles and their muscle spindles, setting off sensory signals to the spinal cord. The CNS responds to this by tensing your calf muscles to keep you from falling and to restore or maintain your upright posture. Then the boat rocks the other way and you begin to tip to the rear. The spindles in the calf muscles are now compressed and their signaling rate drops. Such input from the spindles inhibits the alpha motor neurons of the calf muscles, relaxing those muscles so they don't pull you farther backward. At the same time, your backward tilt stretches spindles in your anterior leg and thigh muscles, leading to their contraction and preventing you from falling over backward.



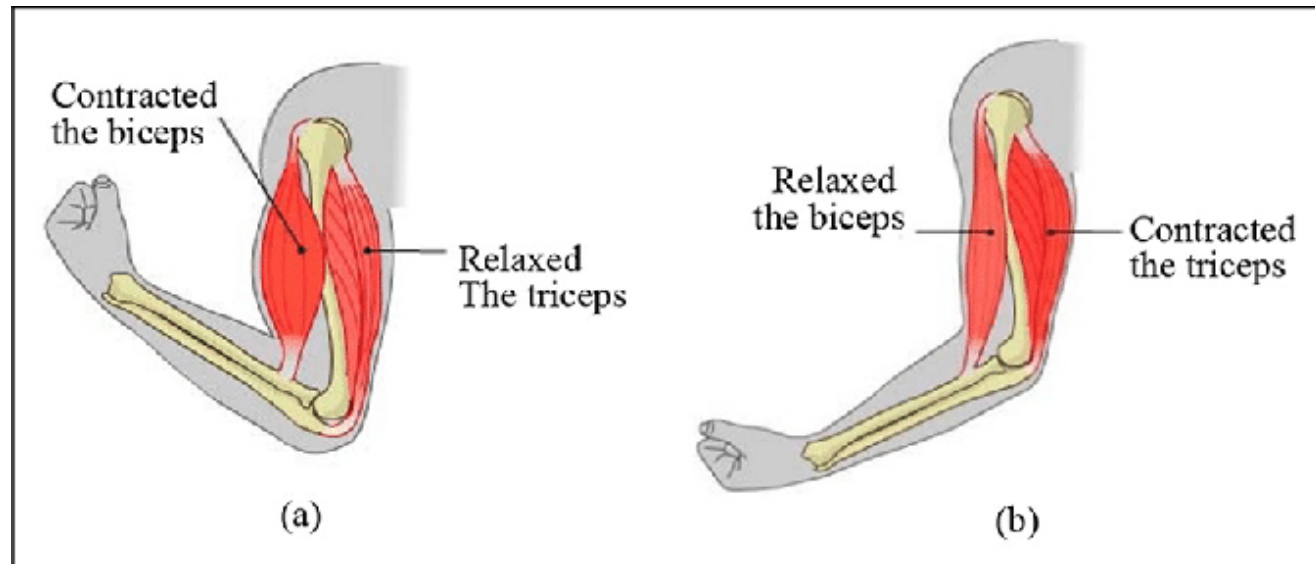
◆ The Stretch Reflex

- When a muscle is suddenly stretched, it “fights back”—it contracts, increases tone, and feels stiffer than an unstretched muscle. This response, called the **stretch (myotatic²⁷) reflex**, helps to maintain equilibrium and posture, as we just saw in the rocking boat example. To take another case, if your head starts to tip forward, it stretches muscles at the back of your neck. This stimulates their muscle spindles, which send signals to the cerebellum by way of the brainstem. The cerebellum integrates this information and relays it to the cerebral cortex, and the cortex sends signals back, via the brainstem, to the muscles. The muscles contract and raise your head.

²⁷myo = muscle; tat (from tasis) = stretch

- Stretch reflexes often feed back not to a single muscle but to a set of *synergists* and *antagonists*. Since the contraction of a muscle on one side of a joint stretches the antagonist on the other side, the flexion of a joint creates a stretch reflex in the extensors, and extension creates a stretch reflex in the flexors.

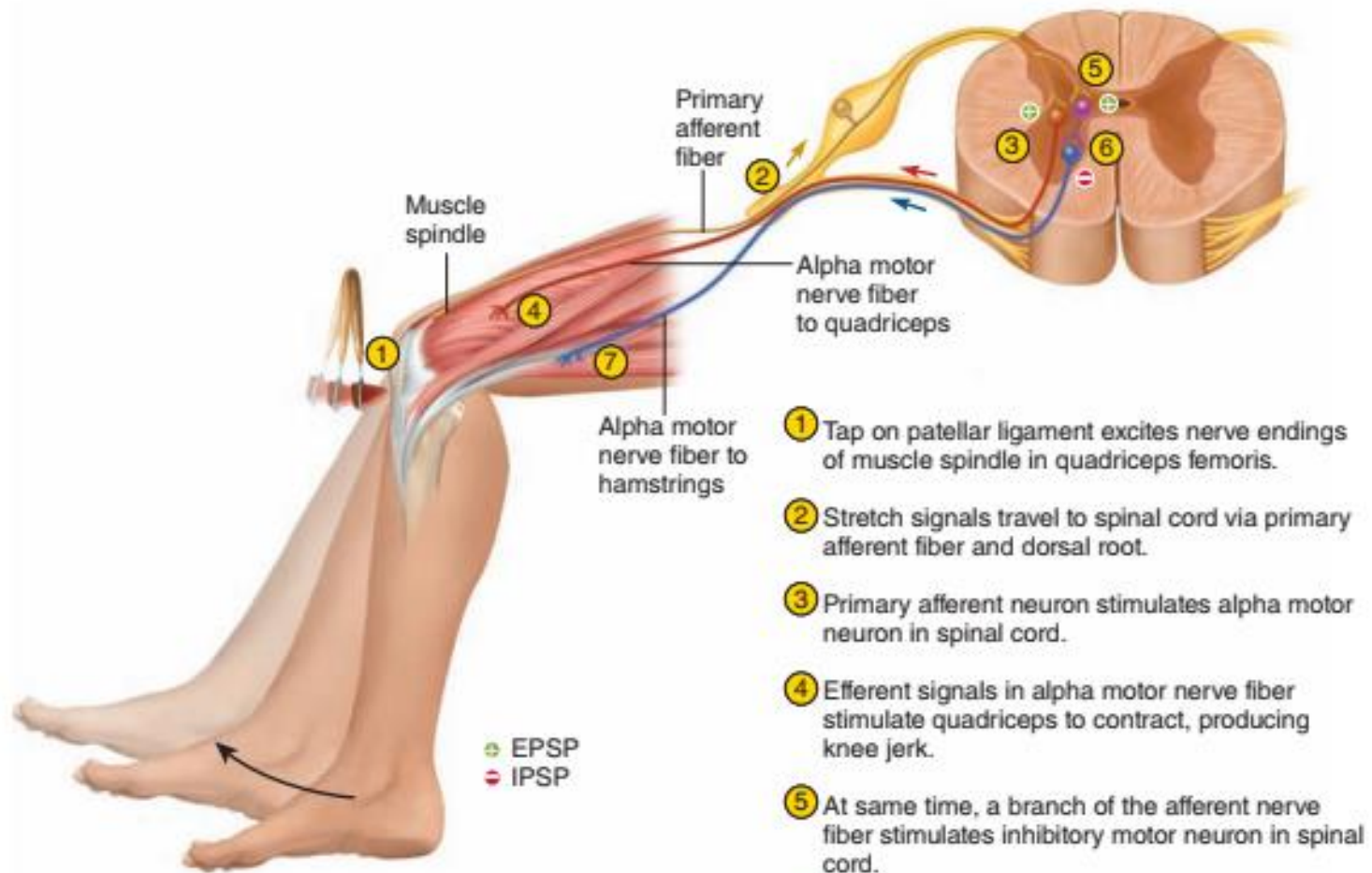
Think of the way your **biceps brachii** is stretched when you **extend your elbow**, for example.



- A stretch reflex is mediated primarily by the brain and is not, therefore, strictly a spinal reflex, but a weak component of it is spinal and occurs even if the spinal cord is severed from the brain. The spinal component can be more pronounced if a muscle is stretched very suddenly. This occurs in the reflexive contraction of a muscle when its tendon is tapped, as in the familiar **patellar (knee-jerk) reflex.**



- Tapping the patellar ligament with a reflex hammer abruptly stretches the *quadriceps femoris muscle* of the thigh (fig. 13.22). This stimulates numerous muscle spindles in the quadriceps and sends an intense volley of signals to the spinal cord, mainly by way of primary afferent fibers.
- In the spinal cord, these fibers synapse directly with the alpha motor neurons that return to the muscle, thus forming **monosynaptic reflex arcs**. That is, there is only one synapse between the afferent and efferent neuron, so there is little synaptic delay and a very prompt response. The alpha motor neurons excite the quadriceps, making it contract and creating the knee jerk.



- 1 Tap on patellar ligament excites nerve endings of muscle spindle in quadriceps femoris.
- 2 Stretch signals travel to spinal cord via primary afferent fiber and dorsal root.
- 3 Primary afferent neuron stimulates alpha motor neuron in spinal cord.
- 4 Efferent signals in alpha motor nerve fiber stimulate quadriceps to contract, producing knee jerk.
- 5 At same time, a branch of the afferent nerve fiber stimulates inhibitory motor neuron in spinal cord.
- 6 That neuron inhibits alpha motor neuron that supplies hamstring muscles.
- 7 Hamstring contraction is inhibited so hamstrings (knee flexors) do not antagonize quadriceps (knee extensor).

FIGURE 13.22 The Patellar Tendon Reflex Arc and Reciprocal Inhibition of the Antagonistic Muscle. Plus signs indicate excitation of a postsynaptic cell (EPSPs), and the minus sign indicates inhibition (IPSPs). The tendon reflex occurs in the quadriceps femoris muscle, while the hamstring muscles exhibit reciprocal inhibition so they don't contract and oppose the quadriceps.

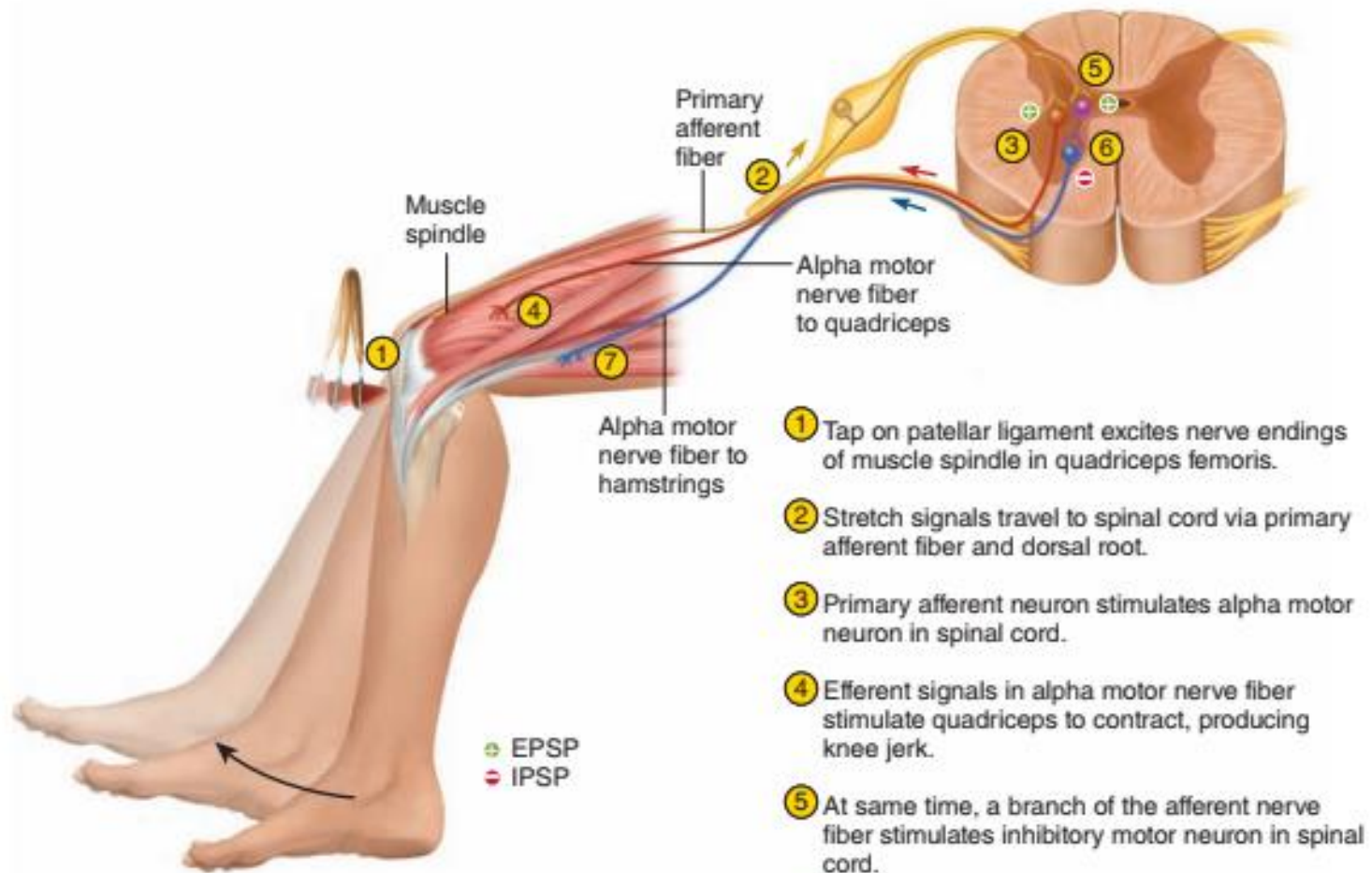
? Why is no IPSP shown at point 7 if the contraction of this muscle is being inhibited?

- There are many other tendon reflexes. A tap on the calcaneal tendon causes plantar flexion of the foot, a tap on the triceps brachii tendon causes extension of the elbow, and a tap on the masseter causes clenching of the jaw.
- Testing somatic reflexes is valuable in diagnosing many diseases that cause exaggeration, inhibition, or absence of reflexes—for example, *neurosyphilis* and *other infectious diseases, diabetes mellitus, multiple sclerosis, alcoholism, hormone and electrolyte imbalances, and lesions of the nervous system.*



Stretch reflexes and other muscle contractions often depend on **reciprocal inhibition**, a reflex that prevents muscles from working against each other by inhibiting antagonists. In the knee jerk, for example, the quadriceps would not produce much joint movement if its antagonists, the hamstring muscles, contracted at the same time. But reciprocal inhibition prevents that from happening. Some branches of the sensory fibers from the quadriceps muscle spindles stimulate spinal interneurons that, in turn, inhibit the alpha motor neurons of the hamstrings (fig. 13.22). The hamstrings remain relaxed and allow the quadriceps to extend the knee.





- ① Tap on patellar ligament excites nerve endings of muscle spindle in quadriceps femoris.
- ② Stretch signals travel to spinal cord via primary afferent fiber and dorsal root.
- ③ Primary afferent neuron stimulates alpha motor neuron in spinal cord.
- ④ Efferent signals in alpha motor nerve fiber stimulate quadriceps to contract, producing knee jerk.
- ⑤ At same time, a branch of the afferent nerve fiber stimulates inhibitory motor neuron in spinal cord.
- ⑥ That neuron inhibits alpha motor neuron that supplies hamstring muscles.
- ⑦ Hamstring contraction is inhibited so hamstrings (knee flexors) do not antagonize quadriceps (knee extensor).

FIGURE 13.22 The Patellar Tendon Reflex Arc and Reciprocal Inhibition of the Antagonistic Muscle. Plus signs indicate excitation of a postsynaptic cell (EPSPs), and the minus sign indicates inhibition (IPSPs). The tendon reflex occurs in the quadriceps femoris muscle, while the hamstring muscles exhibit reciprocal inhibition so they don't contract and oppose the quadriceps.

? Why is no IPSP shown at point 7 if the contraction of this muscle is being inhibited?

◆ The Flexor (Withdrawal) Reflex

- A **flexor reflex** is the quick contraction of flexor muscles resulting in the withdrawal of a limb from an injurious stimulus. For example, suppose you are wading in a lake and step on a broken bottle with your right foot (fig. 13.23). Even before you are consciously aware of the pain, you quickly pull your foot away before the glass penetrates any deeper. This action involves contraction of the flexors and relaxation of the extensors in that limb; the latter is another case of reciprocal inhibition.



- The protective function of this reflex requires more than a quick jerk like a tendon reflex, so it involves more complex neural pathways. Sustained contraction of the flexors is produced by a parallel after-discharge circuit in the spinal cord (see fig. 12.31).
- This circuit is part of a **polysynaptic reflex arc**—a pathway in which signals travel over many synapses on their way back to the muscle.



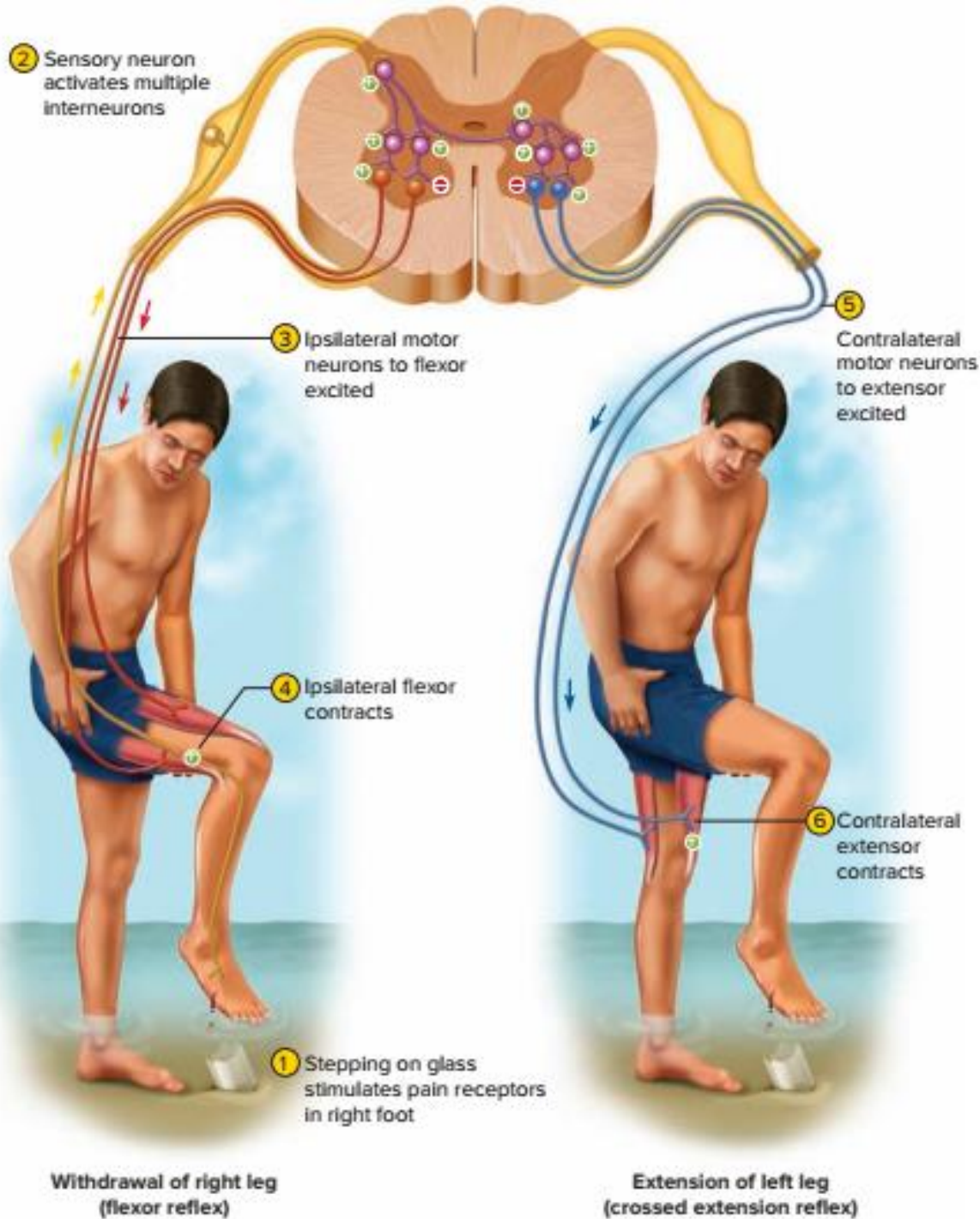


FIGURE 13.23 The Flexor and Crossed Extension Reflexes. A pain stimulus triggers a withdrawal reflex, which results in contraction of flexor muscles of the injured limb. At the same time, a crossed extension reflex results in contraction of extensor muscles of the opposite limb. The latter reflex aids in balance when the injured limb is raised. Note that for each limb, while the agonist contracts, the alpha motor neuron to its antagonist is inhibited, as indicated by the red minus signs in the spinal cord.

◆ The Crossed Extension Reflex

- In the preceding situation, if all you did was to quickly lift the injured leg from the lake bottom, you would fall over. To prevent this and maintain your balance, other reflexes shift your center of gravity over the leg that is still planted on the ground. The **crossed extension reflex** is the contraction of extensor muscles in the limb opposite from the one that is withdrawn (fig. 13.23). It extends and stiffens that limb and enables you to keep your balance.



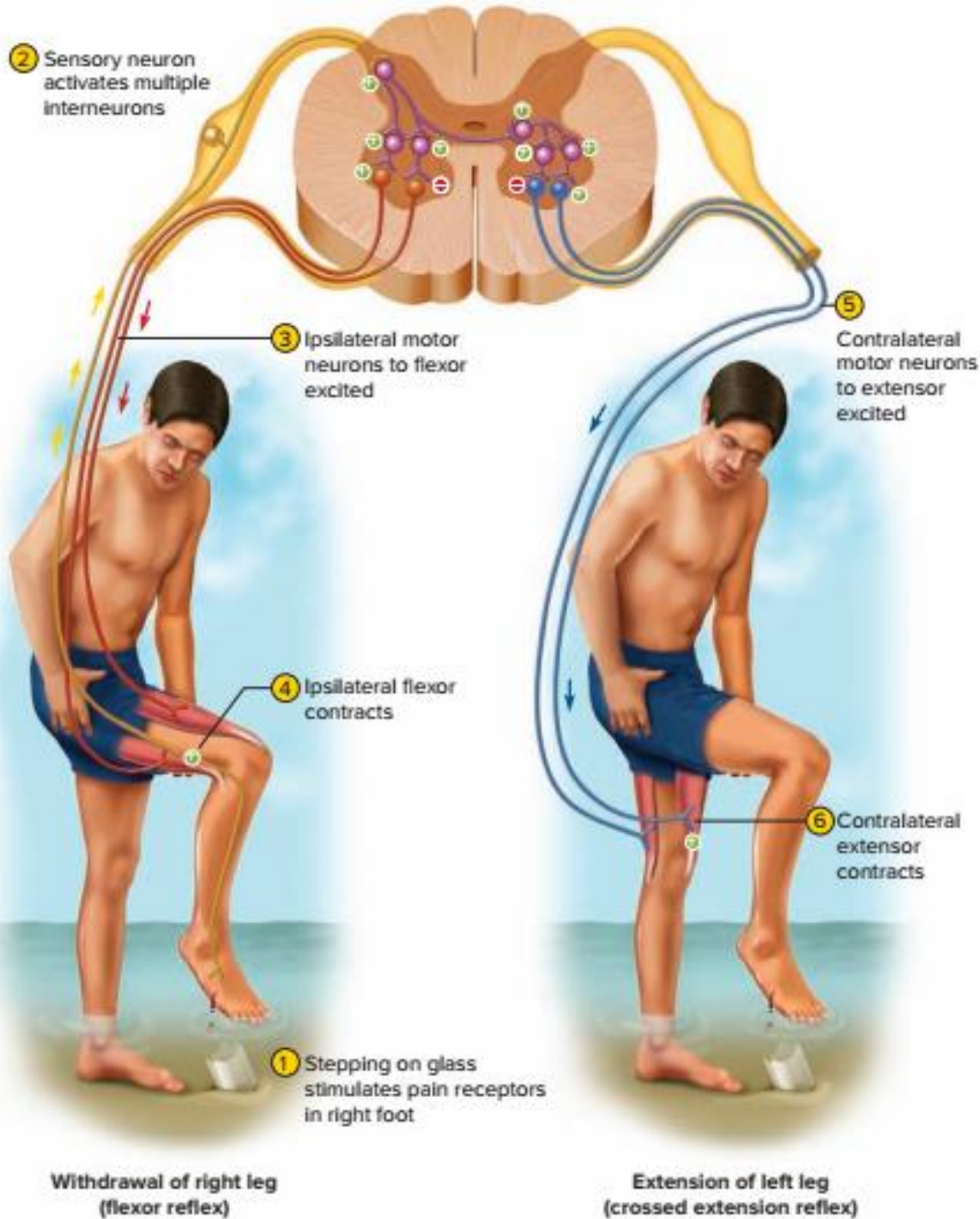


FIGURE 13.23 The Flexor and Crossed Extension Reflexes. A pain stimulus triggers a withdrawal reflex, which results in contraction of flexor muscles of the injured limb. At the same time, a crossed extension reflex results in contraction of extensor muscles of the opposite limb. The latter reflex aids in balance when the injured limb is raised. Note that for each limb, while the agonist contracts, the alpha motor neuron to its antagonist is inhibited, as indicated by the red minus signs in the spinal cord.

- To produce this reflex, branches of the afferent nerve fibers cross from the stimulated side of the body to the contralateral side of the spinal cord. There, they synapse with interneurons, which, in turn, excite or inhibit alpha motor neurons to the muscles of the contralateral limb.



- The flexor reflex employs an **ipsilateral reflex arc** — one in which the sensory input and motor output are on the same side of the spinal cord. The crossed extension reflex employs a **contralateral reflex arc**, in which the input and output are on opposite sides. An **intersegmental reflex arc** is one in which the input and output occur at different levels (segments) of the spinal cord—for example, when pain to the foot causes contractions of abdominal and hip muscles higher up the body. Note that all of these reflex arcs can function simultaneously to produce a coordinated protective response to pain



◆ The Tendon Reflex

- **Tendon organs** are proprioceptors located in a tendon near its junction with a muscle (fig. 13.24). A tendon organ is about *0.5 mm* long. It consists of an encapsulated bundle of small, loose collagen fibers and one or more nerve fibers that penetrate the capsule and end in flattened leaflike processes between the collagen fibers. As long as the tendon is slack, its collagen fibers are slightly spread and put little pressure on the nerve endings.
- When muscle contraction pulls on the tendon, the collagen fibers come together like the two sides of a stretched rubber band and squeeze the nerve endings between them. The nerve fiber sends signals to the spinal cord that provide the CNS with feedback on the degree of muscle tension at the joint.



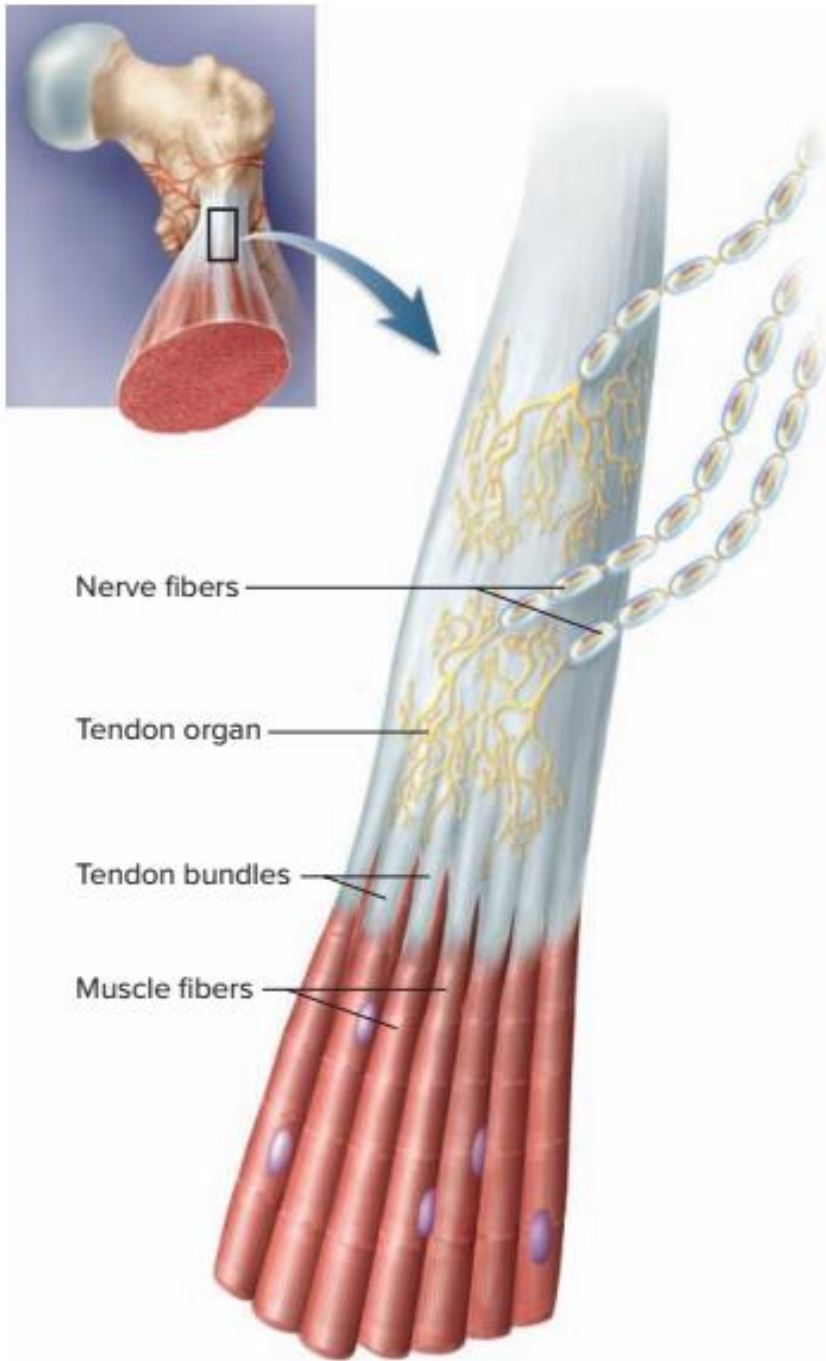


FIGURE 13.24 A Tendon Organ.

- The **tendon reflex** is a response to excessive tension on the tendon. It inhibits alpha motor neurons to the muscle so the muscle does not contract as strongly. This serves to moderate muscle contraction before it tears a tendon or pulls it loose from the muscle or bone. Nevertheless, strong muscles and quick movements sometimes damage a tendon before the reflex can occur, causing such athletic injuries as a ruptured calcaneal tendon.



- To produce this reflex, branches of the afferent nerve fibers cross from the stimulated side of the body to the contralateral side of the spinal cord. There, they synapse with interneurons, which, in turn, excite or inhibit alpha motor neurons to the muscles of the contralateral limb.
- The tendon reflex also functions when some parts of a muscle contract more than others. It inhibits the muscle fibers connected with overstimulated tendon organs so their contraction is more comparable to the contraction of the rest of the muscle. This spreads the workload more evenly over the entire muscle, which is beneficial in such actions as maintaining a steady grip on a tool.



TABLE
13.7

Some Disorders of the Spinal Cord and Spinal Nerves

<u>Guillain–Barré syndrome</u>	An acute demyelinating nerve disorder often triggered by viral infection, resulting in muscle weakness, elevated heart rate, unstable blood pressure, shortness of breath, and sometimes death from respiratory paralysis
<u>Neuralgia</u>	General term for nerve pain, often caused by pressure on spinal nerves from herniated intervertebral discs
<u>Paresthesia</u>	Abnormal sensations of prickling, burning, numbness, or tingling; a symptom of peripheral nerve disorders
<u>Peripheral neuropathy</u>	Any loss of sensory or motor function due to nerve injury; also called nerve palsy
<u>Rabies (hydrophobia)</u>	A disease usually contracted from animal bites, involving viral infection that spreads via somatic motor nerve fibers to the CNS and then autonomic nerve fibers; leads to seizures, coma, and death; invariably fatal if not treated before CNS symptoms appear
<u>Spinal meningitis</u>	Inflammation of the spinal meninges due to viral, bacterial, or other infection



Before You Go On

Answer these questions from memory. Reread the preceding section if there are too many you don't know.

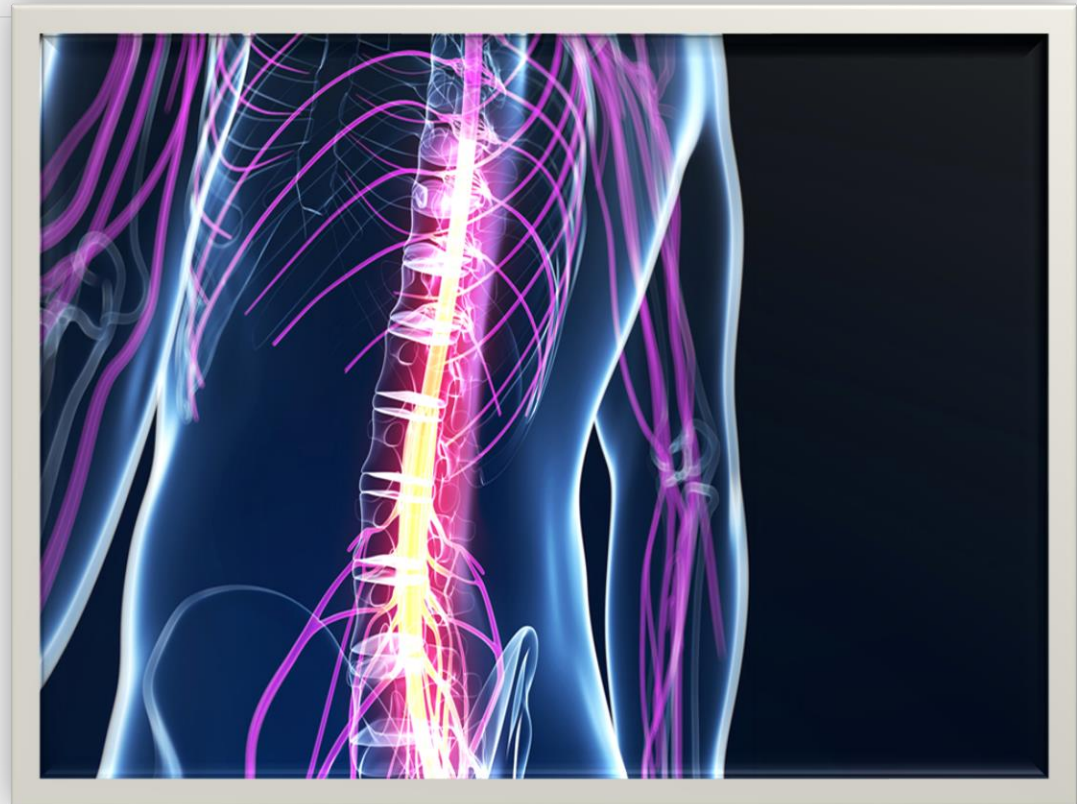
- 1. Name five structural components of a typical somatic reflex arc. Which of these is absent from a monosynaptic arc?*
- 2. State the function of each of the following in a muscle spindle: intrafusal fibers, gamma motor neurons, and primary afferent fibers.*
- 3. Explain how nerve fibers in a tendon sense the degree of tension in a muscle.*
- 4. Why must the withdrawal reflex, but not the stretch reflex, involve a polysynaptic reflex arc?*
- 5. Explain why the crossed extension reflex must accompany a withdrawal reflex of the leg*





**Al-Farabi Kazakh
National
University
Higher School of
Medicine**

The spinal cord



Overview of Nervous System

- endocrine and nervous system maintain internal coordination
 - endocrine system - communicates by means of chemical messengers (hormones) secreted into to the blood
 - nervous system - employs electrical and chemical means to send messages from cell to cell
- nervous system carries out its task in three basic steps:
 - sense organs receive information about changes in the body and the external environment, and transmits coded messages to the spinal cord and the brain
 - brain and spinal cord processes this information, relates it to past experiences, and determine what response is appropriate to the circumstances
 - brain and spinal cord issue commands to muscles and gland cells to carry out such a response

Two Major Anatomical Subdivisions of Nervous System

- central nervous system (CNS)
 - brain and spinal cord enclosed in bony coverings
 - enclosed by cranium and vertebral column
- peripheral nervous system (PNS)
 - all the nervous system except the brain and spinal cord
 - composed of nerves and ganglia
 - nerve – a bundle of nerve fibers (axons) wrapped in fibrous connective tissue
 - ganglion – a knot-like swelling in a nerve where neuron cell bodies are concentrated

Subdivisions of Nervous System

Anatomy & Physiology: The Unity of Form and Function McGraw-Hill Education; 8th Edition

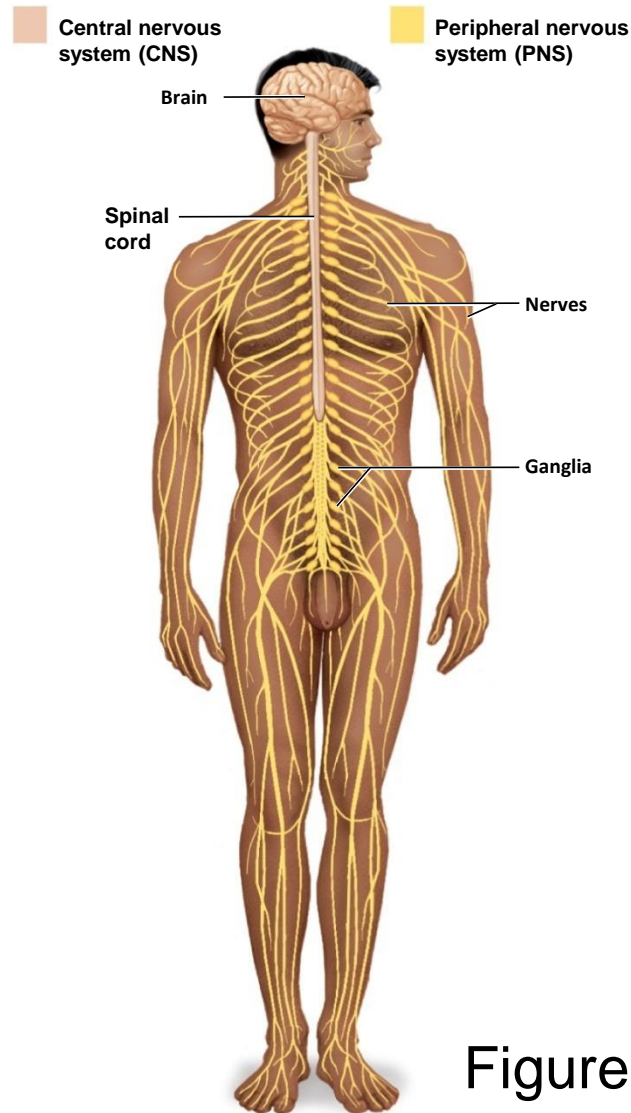


Figure 12.1

Sensory Divisions of PNS

- sensory (afferent) division – carries sensory signals from various receptors to the CNS
 - informs the CNS of stimuli within or around the body
 - somatic sensory division – carries signals from receptors in the skin, muscles, bones, and joints
 - visceral sensory division – carries signals from the viscera of the thoracic and abdominal cavities
 - heart, lungs, stomach, and urinary bladder

Motor Divisions of PNS

- motor (efferent) division – carries signals from the CNS to gland and muscle cells that carry out the body's response
 - effectors – cells and organs that respond to commands from the CNS
 - somatic motor division – carries signals to skeletal muscles
 - output produces muscular contraction as well as somatic reflexes – involuntary muscle contractions
 - visceral motor division (autonomic nervous system) - carries signals to glands, cardiac muscle, and smooth muscle
 - involuntary, and responses of this system and its receptors are visceral reflexes
 - sympathetic division
 - tends to arouse body for action
 - accelerating heart beat and respiration, while inhibiting digestive and urinary systems
 - parasympathetic division
 - tends to have calming effect
 - slows heart rate and breathing
 - stimulates digestive and urinary systems

Subdivisions of Nervous System

Anatomy & Physiology: The Unity of Form and Function McGraw-Hill Education; 8th Edition

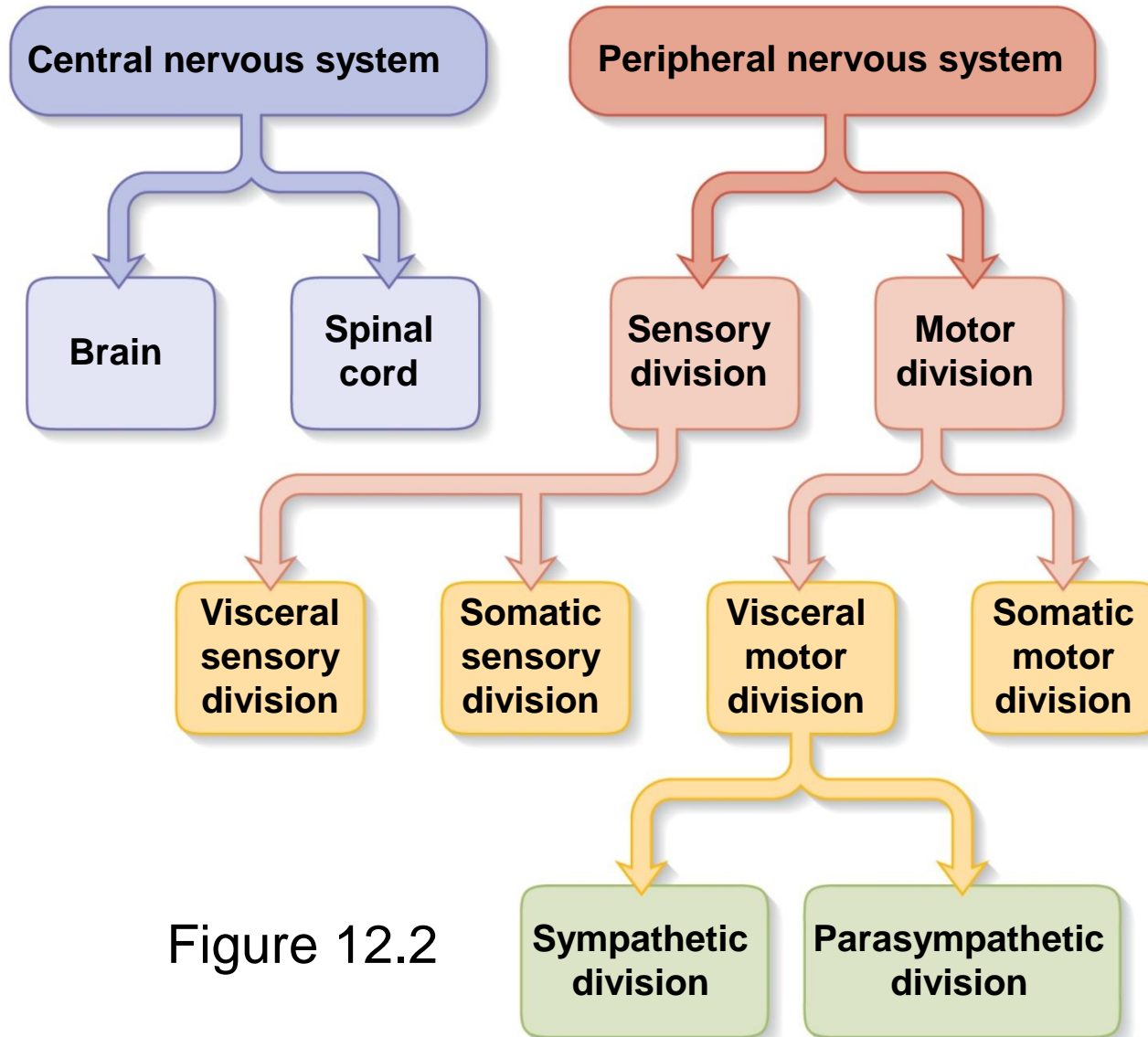


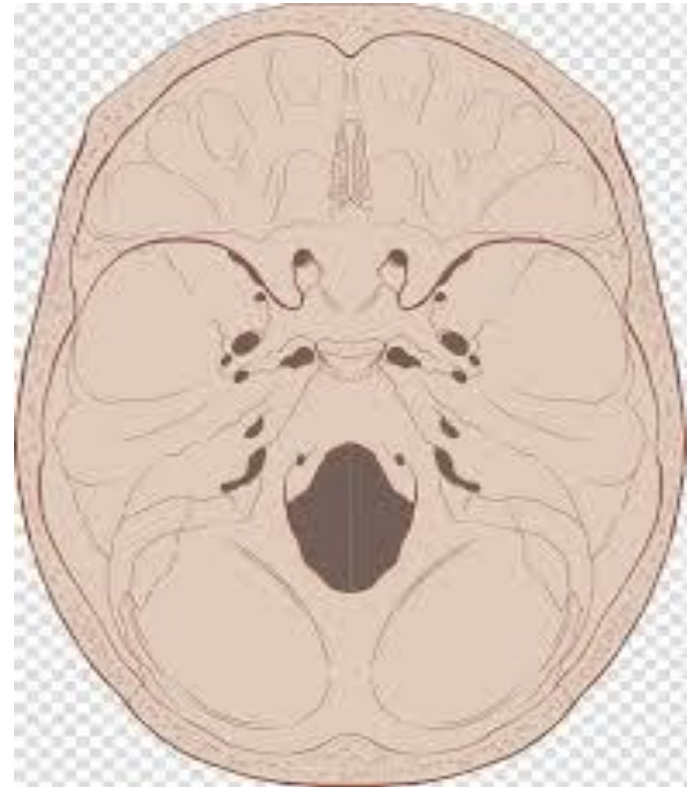
Figure 12.2

LEARNING OUTCOMES

- As a result of the lesson you will be able to:
 - ✓ *Identify the parts of spinal cord in the model;*
 - ✓ *Identify the innervation of the spinal cord's branches;*
 - ✓ *State the three principal functions of the spinal cord;*
 - ✓ *Describe its gross and microscopic structure;*
 - ✓ *Trace the pathways followed by nerve signals travelling up and down the spinal cord.*

1. Identify the parts of spinal cord in the model

- The *spinal cord* is an organ of the central nervous system located in the vertebral canal.
- It has cylinder-like shape and arises from the brainstem at the foramen magnum of the skull.
- At the top it goes into medulla oblongata



https://favpng.com/png_view/image-of-skull-base-of-skull-foramen-magnum-bone-anatomy-png/St3Nvg22

- In adults, it averages about 45 cm long and 1.8 cm thick (about as thick as one's little finger).
- Early in fetal development, the cord extends for the full length of the vertebral column.
 - However, the vertebral column grows faster than the spinal cord, so the cord extends only to L3 by the time of birth and to L1 in an adult.

Lower limit of spinal cord

- In fetus**

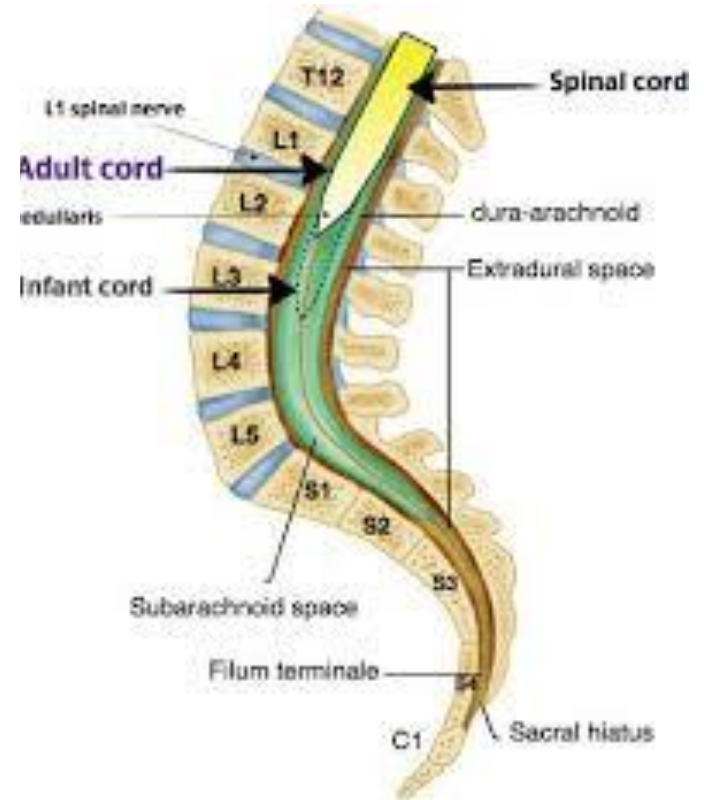
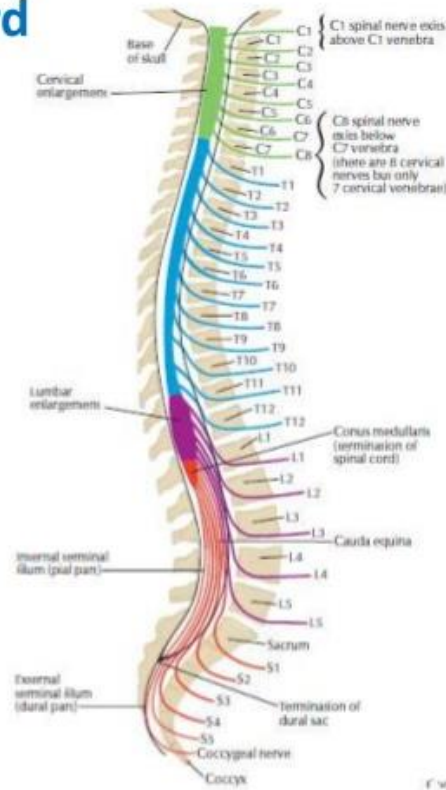
- conus medularis (lower limit of spinal cord) = S2
- Spinal dura mater = S2

- At birth**

- Conus medularis = L3
- Spinal dura mater = S2

- In Adults**

- Conus medularis = L1 or L2
- Spinal dura mater = S2
- Subarachnoid space = S2



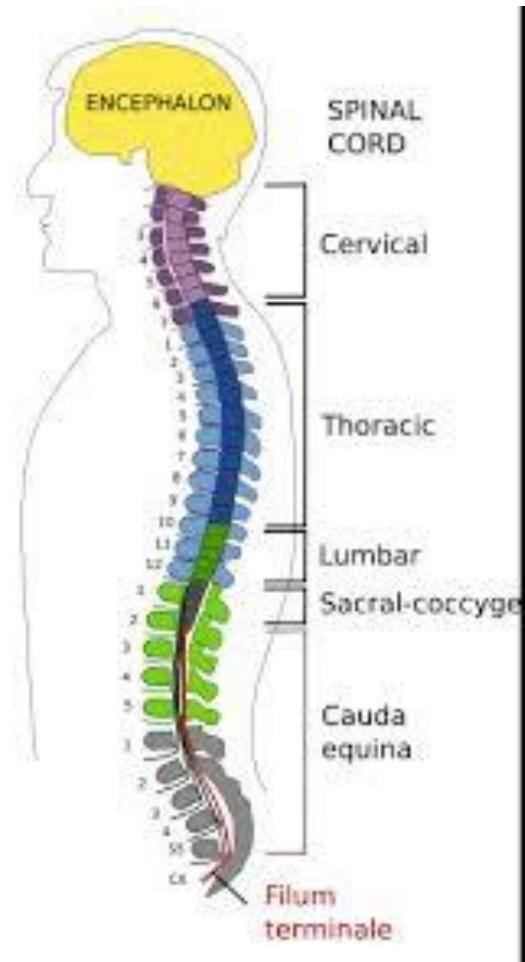- The spinal cord is a continuation of the *brainstem*.
 - It extends from the *foramen magnum* at the base of the skull to the *L1/L2 vertebra* where it terminates as the *conus medullaris (medullary cone)*.
 - A thin thread called *filum terminale* extends from the tip of the conus medullaris all the way to the 1st coccygeal vertebra (Co1) and anchors the spinal cord in place.
- You can easily remember the extent of the spinal cord with a mnemonic '**SCULL**', which stands for '**Spinal Cord Until L2 (LL)**'.

- Throughout its length, the spinal cord shows two well defined enlargements to accommodate for innervation of the upper and lower limbs: one at the cervical level (upper limbs), and one at the lumbosacral level (lower limbs).



The spinal cord is divided into:

- cervical, thoracic, lumbar, and sacral regions.
- (!) These regions, however, are named for the level of the vertebral column from which the spinal nerves emerge, not for the vertebrae that contain the cord itself.
- Inferior to the lumbar enlargement, the cord appears to a point called the *medullary cone*.
 - Arising from the lumbar enlargement and medullary cone is a bundle of nerve roots that occupy the vertebral canal from L2 to S5.
 - This bundle, named the *cauda equina* for its resemblance to a horse's tail, innervates the pelvic organs and lower limbs.



2. Identify the innervation of the spinal cord

Spinal cord regions subdivided into segments.

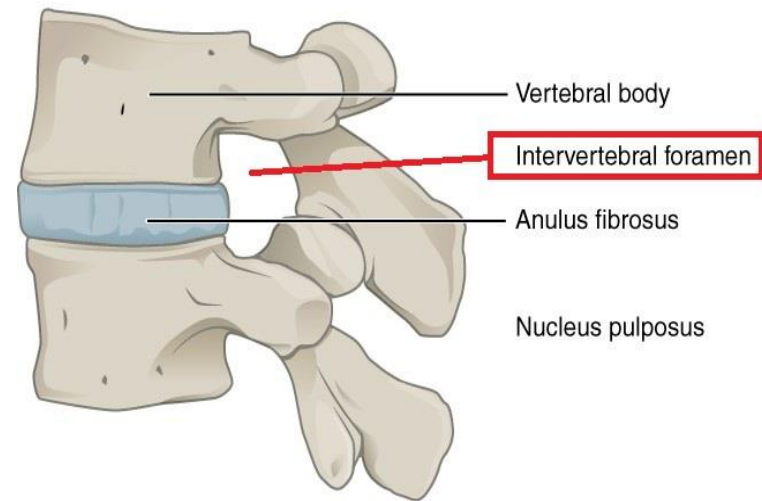
Although the spinal cord is not visibly segmented, the part supplied by each pair of nerves is called a *segment*.

- *Segment* – section of the spinal cord, appropriate to two couples of roots (2 anterior and 2 posterior).
- **There are next groups of segments:**
 - cervical, thoracic, lumbar, sacral, and coccygeal.
- Each segment of the spinal cord provides several pairs of **spinal nerves**, which exit from vertebral canal through the *intervertebral foramina*.
- There are 8 pairs of cervical, 12 thoracic, 5 lumbar, 5 sacral, and 1 coccygeal pair of spinal nerves (a total of 31 pairs).

Divisions of spinal nerve pairs

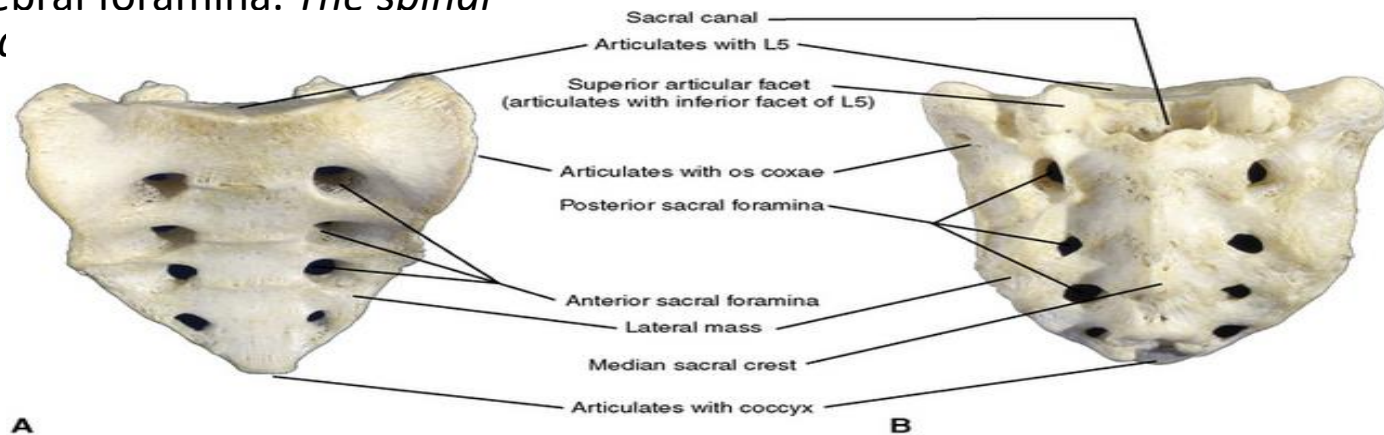
Cervical	8
Thoracic	12
Lumbar	5
Sacral	5
Coccygeal	1
Total	31

- Dorsal and ventral roots enter and leave the vertebral column respectively through *intervertebral foramen* at the vertebral segments corresponding to the spinal segment.
- The cervical spinal nerves differ from others.
 - *C1-C7 spinal nerves emerge from the vertebral canal above the corresponding vertebra, with an eighth pair of cervical spinal nerves emerging below the C7 vertebra, meaning there are a total of 8 pairs of cervical spinal nerves while there are only 7 cervical vertebrae.*
- The sacrum differs from the rest of the vertebral column in that its individual vertebrae are fused together, thus there are no intervertebral foramina. *The spinal nerves instead pass through foramina.*

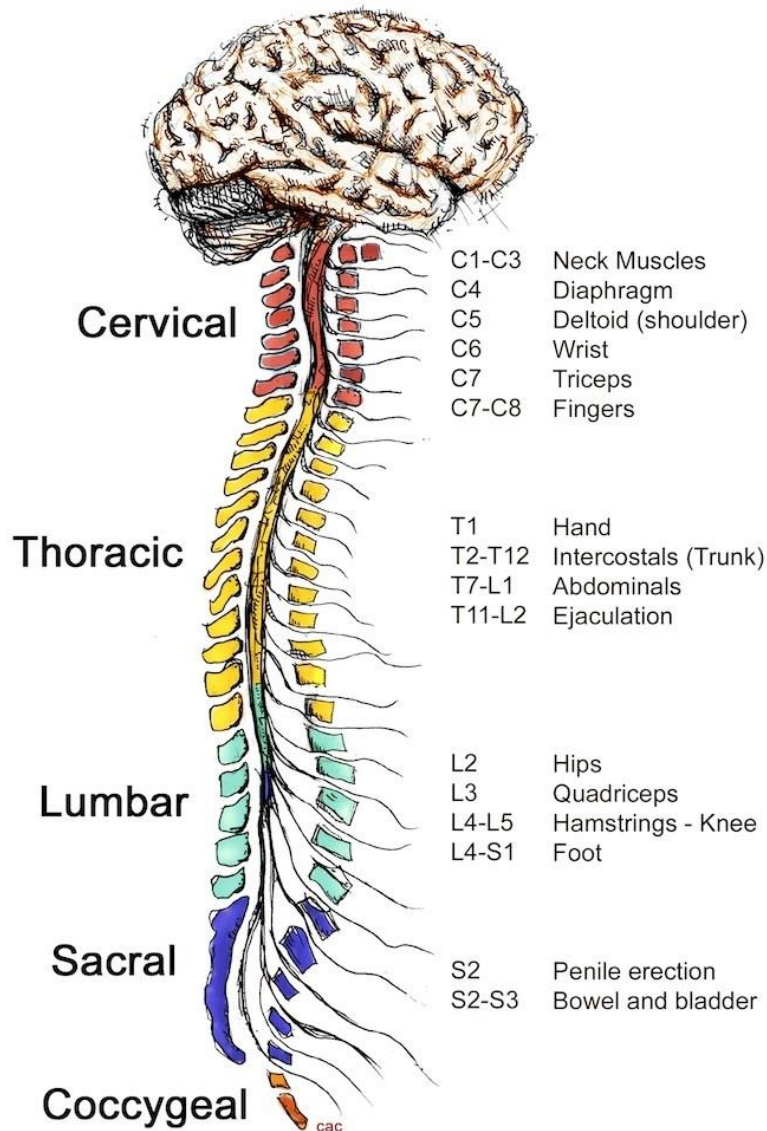


Lateral view

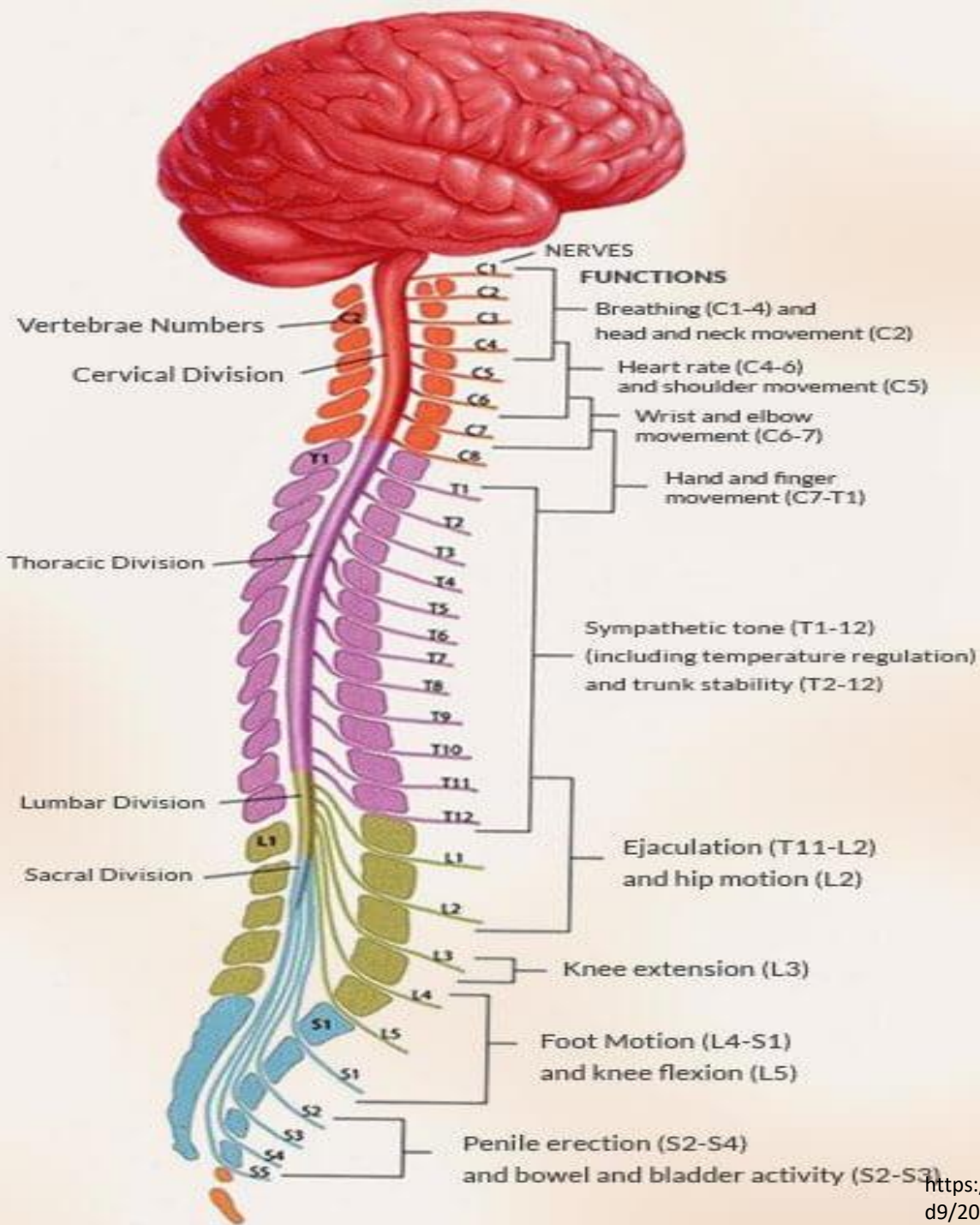
<https://radiopaedia.org/articles/intervertebral-foramen-1?lang=us>

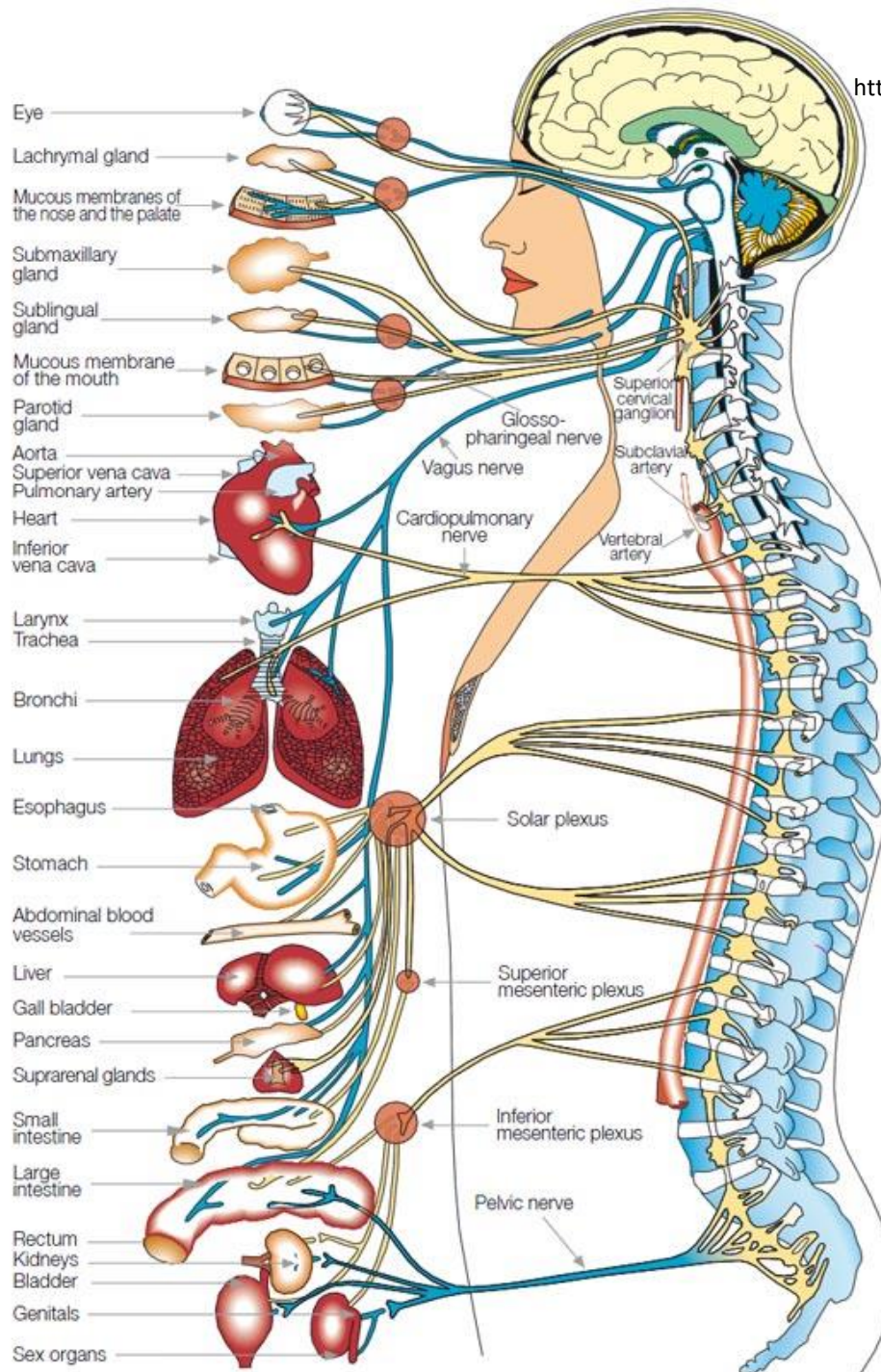


<https://pocketdentistry.com/2-the-back/>



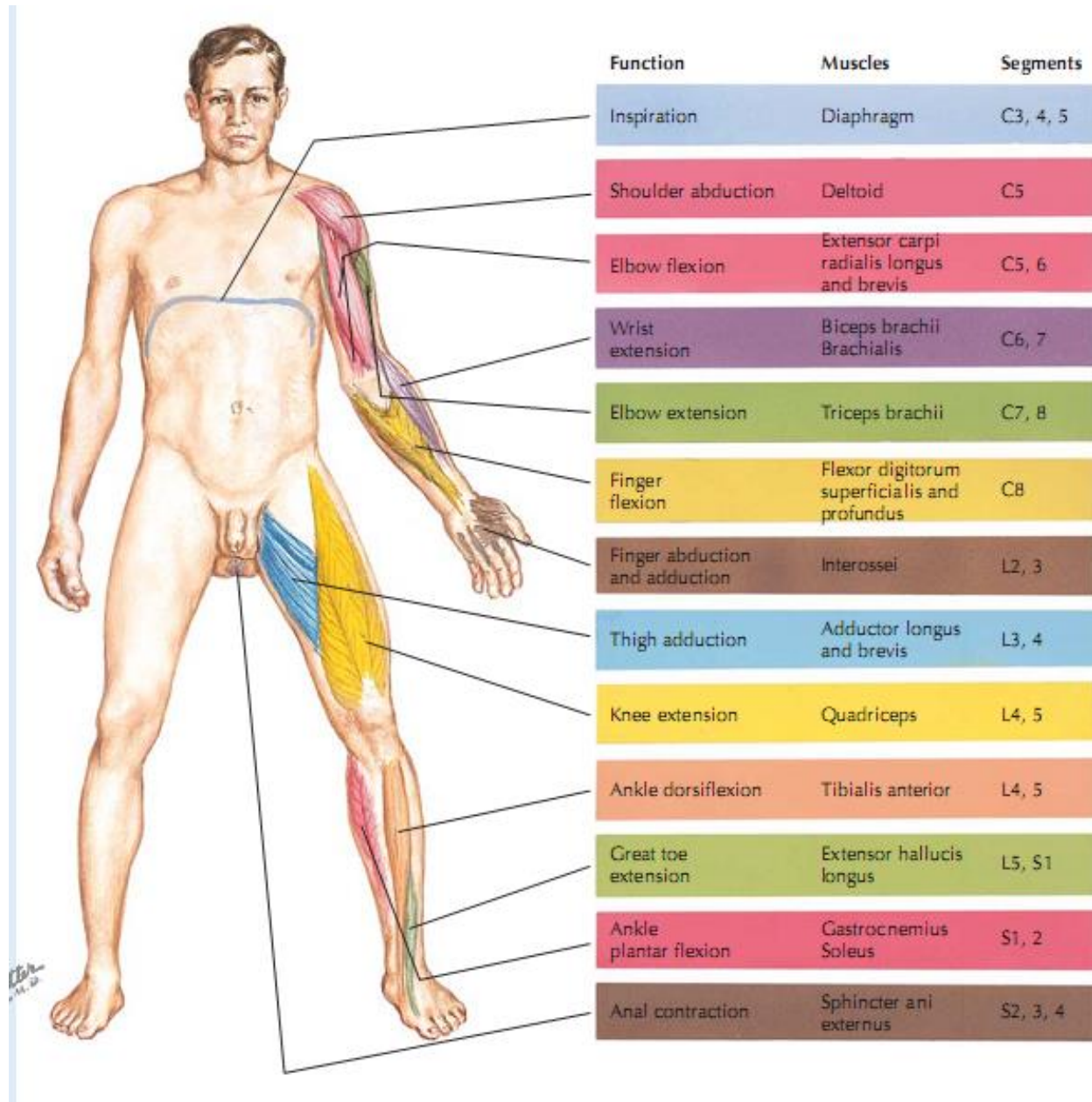
<https://www.google.com/imgres?imgurl=https%3A%2F%2Fimg.go-homework.com%2Fimg%2Fbiology%2Fhow-is-the-central-nervous-system-protected-from-mechanical-damage.jpg&imgrefurl=https%3A%2F%2Fru.howtodoiteasy.com%2F71156-how-is-the-central-nervous-system-protected-from-external-and-internal-injury-26&tbnid=YokScfPtQLvCrM&vet=12ahUKEwIj46z2ouPrAhWQzaYKHQeACuMQMygDegUIARCAAQ..i&docid=HSngss1iRPZ1DM&w=910&h=1239&itg=1&q=c5%20spinal%20cord%20injury&hl=ru&ved=2ahUKEwIj46z2ouPrAhWQzaYKHQeACuMQMygDegUIARCAAQ>





VERTEBRAE	AREAS AND PARTS OF THE BODY	POSSIBLE SYMPTOMS	
CERVICAL			
C 1	• Back of the head	Headaches (including migraines, aches or pain at the back of the head, behind the eyes or in the temples), tension across the forehead, throbbing or pulsating discomfort at the top or back of head)	
C 2	• Various areas of the head		
C 3	• Side and front of the neck		
C 4	• Upper back of the neck		
C 5	• Middle of neck and upper part of arms		Jaw muscle, or joint aches or pains
C 6	• Lower part of neck, arms and elbows		Dizziness, nervousness, vertigo
C 7	• Lower part of arms, shoulders		Soreness, tension and tightness felt in back of neck and throat area
DORSAL			
D 1	• Hands, wrists, fingers, thyroid	Pain, soreness, and restriction in the shoulder area	
D 2	• Heart, its valves and coronary arteries		
D 3	• Lungs, bronchial tubes, pleura, chest	Pain and soreness in arms, hands, elbows and /or fingers	
D 4	• Gall bladder, common duct		
D 5	• Liver, solar plexus	Chest pains, tightness or constriction, asthma, difficulty breathing	
D 6	• Stomach, mid-back area		
D 7	• Pancreas, duodenum	Middle or lower mid-back pain, discomfort and soreness	
D 8	• Spleen, lower mid-back		
D 9	• Adrenal glands	Various and numerous symptoms from trouble or malfunctioning of:	
D 10	• Kidneys		
D 11	• Ureters	- Thyroid - Heart - Lungs - Gall bladder - Liver - Stomach - Pancreas - Spleen	
D 12	• Small intestine, upper/lower back	- Adrenal glands - Kidneys	
LUMBAR			
L 1	• Ileocecal valve, large intestine	- Small and large intestines - Sex organs - Uterus - Bladder - Prostate glands	
L 2	• Appendix, abdomen, upper leg		
L 3	• Sex organs, uterus, bladder, knees	Low back pain, aches and soreness	
L 4	• Prostate gland, lower back		
L 5	• Sciatic nerve, lower legs, ankles, feet	Trouble walking	
SACRO			
• Hip bones, buttocks		Sciatica, pain or soreness in the hip and buttocks	
COXIS			
• Rectum, anus		Rectal trouble	

- *Spinal cord injuries commonly result from fractures of vertebrae C5 to C6, but never from fractures of L3 to L5.*
- *Explain both observations.*



Motor Impairment Related to Level of Spinal Injury

3. State the three principal functions of the spinal cord

1. Conduction

It contains bundles of nerve fibers that conduct information up and down the cord, connecting different levels of the trunk with each other and with the brain.

- This enables sensory information to reach the brain, motor commands to reach the effectors, and input received at one level of the cord to affect output from another level.

2. Neural integration

- *Pools of spinal neurons receive input from multiple sources, integrate the information, and execute an appropriate output.*
 - For example, the spinal cord can integrate the stretch sensation from a full bladder with cerebral input concerning the appropriate time and place to urinate and execute control of the bladder accordingly

3. Locomotion

- Walking involves repetitive, coordinated contractions of several muscle groups in the limbs.
 - *Motorneurons* in the brain initiate walking and determine its speed, distance, and direction, but the simple repetitive muscle contractions that put one foot in front of another, over and over, are coordinated by groups of neurons called *central pattern generators in the cord*.
 - These neural circuits produce the sequence of outputs to the extensor and flexor muscles that cause alternating movements of the lower limbs.

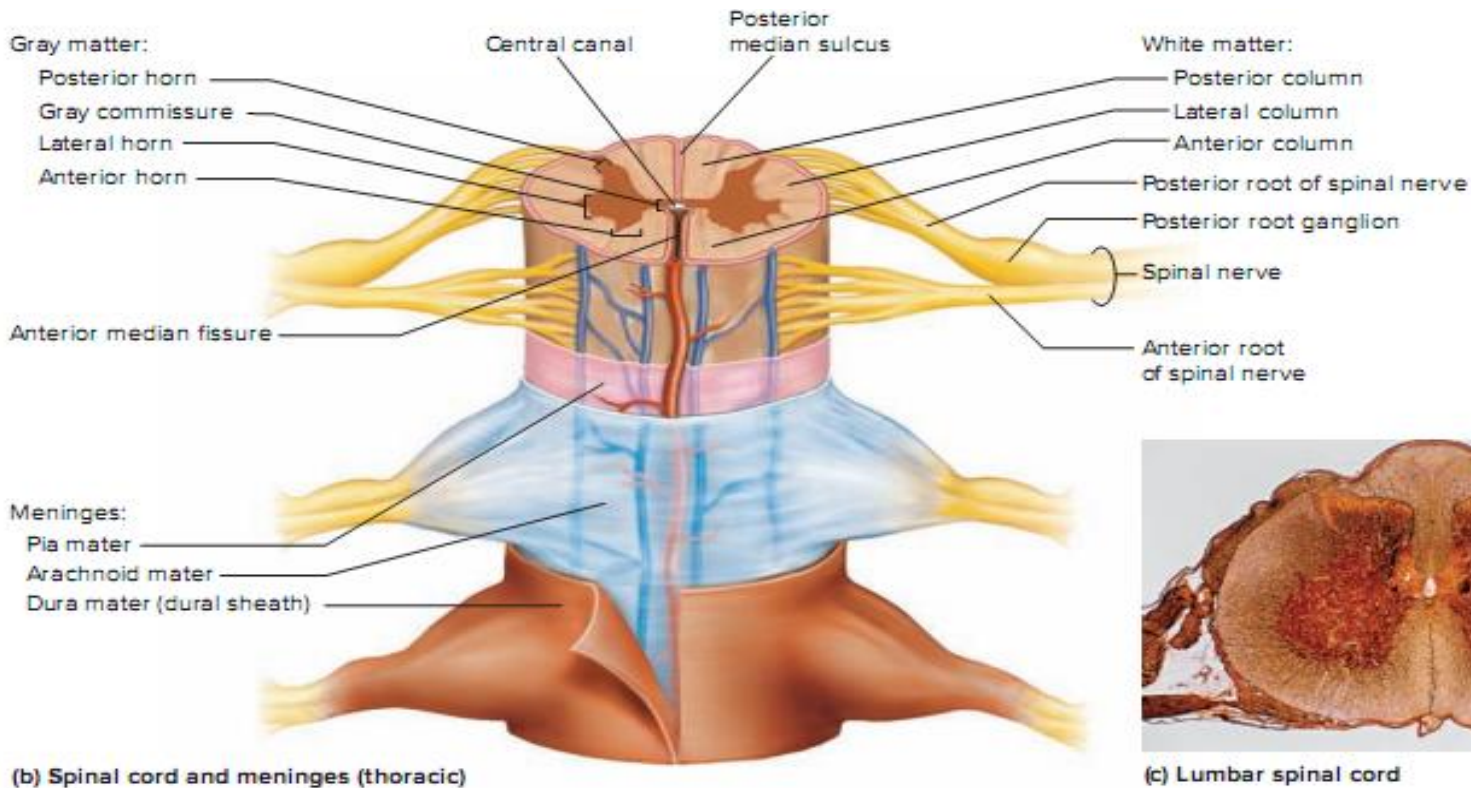
Plus

4. Reflexes

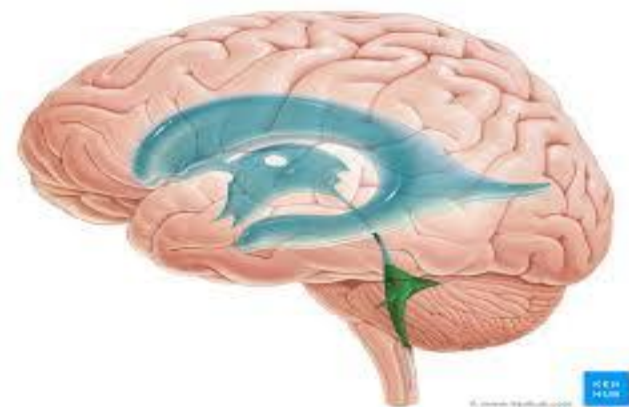
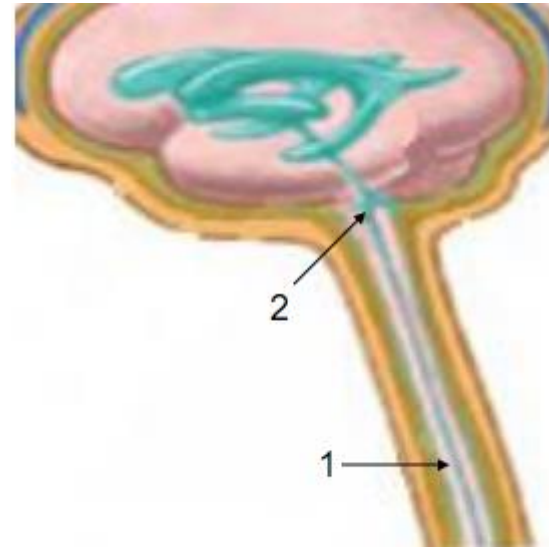
Spinal reflexes play vital roles in posture, motor coordination, and protective responses to pain or injury.

4. Describe its gross and microscopic structure

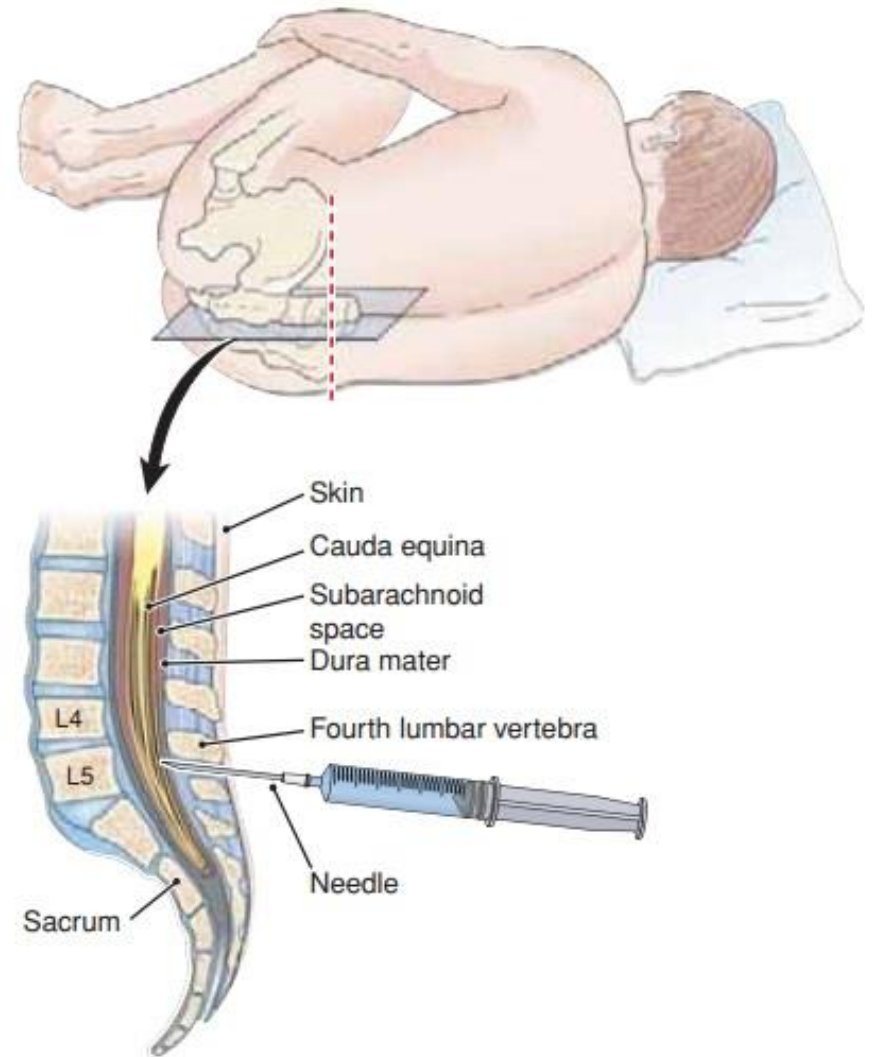
- The cord exhibits longitudinal grooves on its anterior and posterior *sides—the anterior median fissure and posterior median sulcus*, respectively



- Inside the spinal cord there is a narrow cavity - *central channel* (1), which is full *cerebrospinal fluid*.
 - The upper end of it communicates with the 4th ventricle (2).
 - The lower end expands and forms a terminal ventricle.
 - The **terminal ventricle** (ventriculus terminalis, fifth **ventricle** or ampulla caudalis) is the widest part of the central canal of the **spinal cord** that is located at or near the conus medullaris.



- When a sample of CSF is needed for clinical purposes, it is taken from the lumbar cistern by a procedure called *lumbar puncture* (or colloquially, spinal tap).
 - A spinal needle is inserted between two vertebrae at level L3/L4 or L4/L5, where there is no risk of accidental injury to the spinal cord (which ends at L1 to L2).
 - CSF drips from the spinal needle into a collection tube; usually 3 to 4 mL of CSF is collected

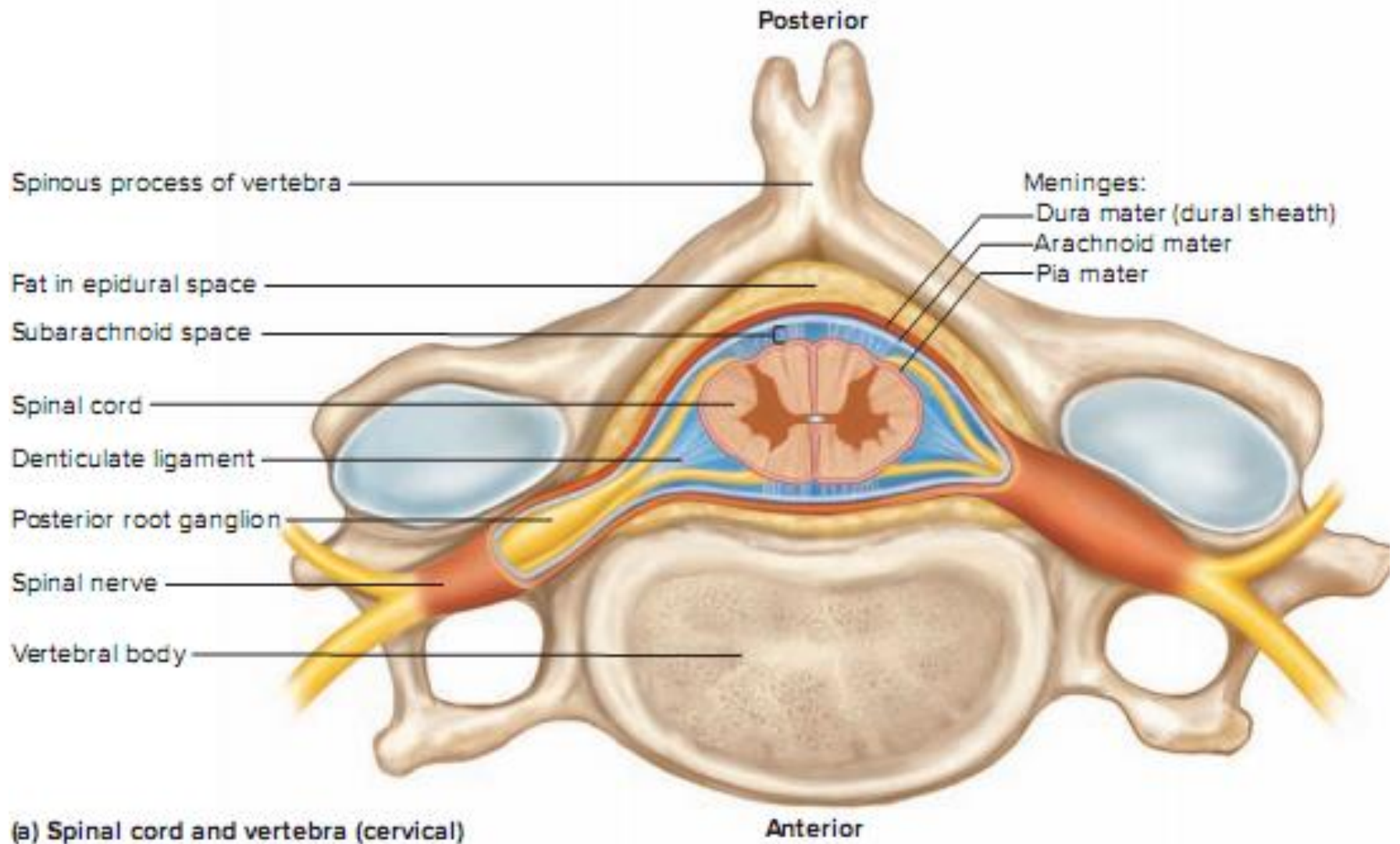


<https://www.tuyenlab.net/2018/02/haematology-cerebrospinal-fluid.html>

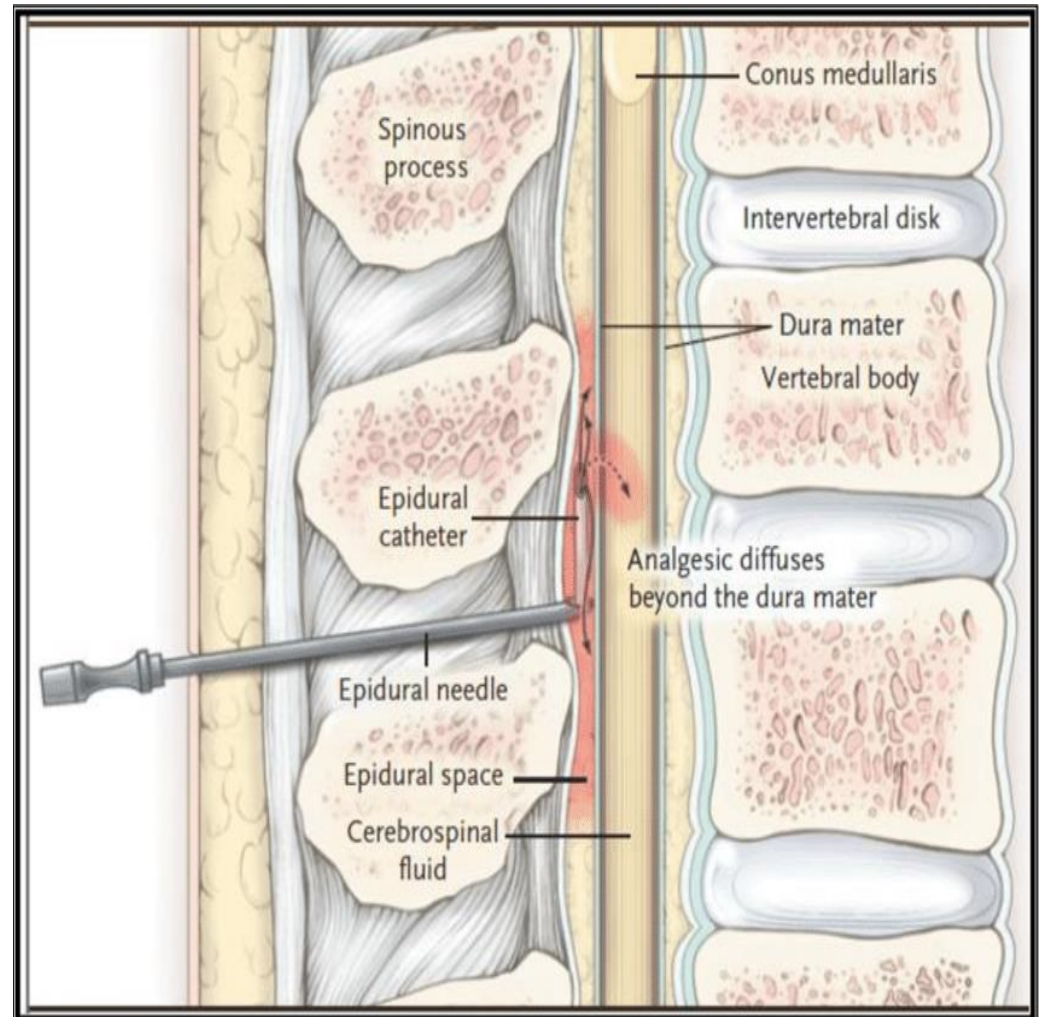
In which cases sample of CSF is needed?

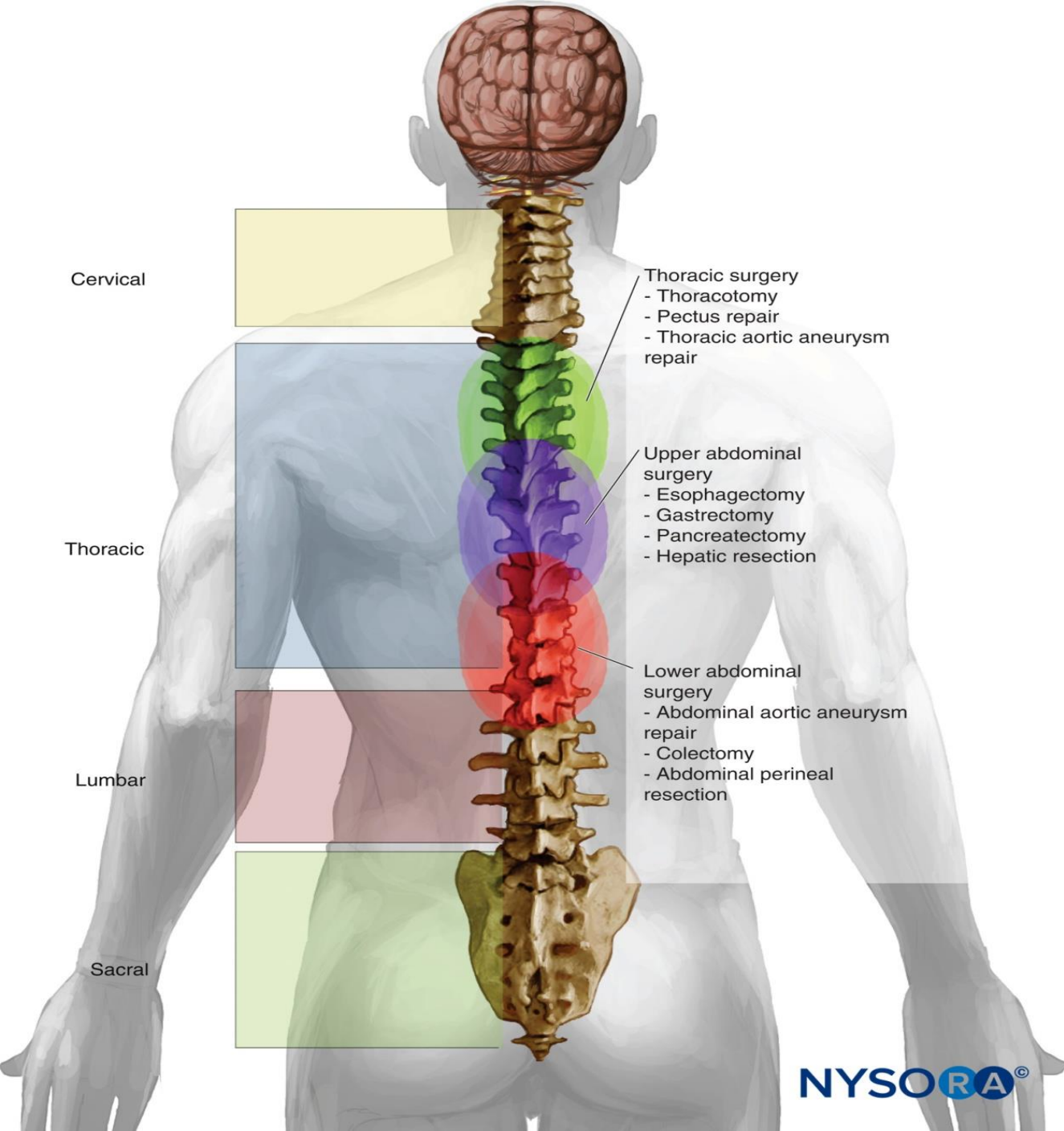
Meninges of the Spinal Cord

- The spinal cord and brain are enclosed in three fibrous membranes called:
 - *meninges* - singular, meninx .
 - These membranes separate the soft tissue of the central nervous system from the bones of the vertebrae and skull.
- From superficial to deep, they are the *dura mater*, *arachnoid mater*, and *pia mater*.
- **The *dura mater*** forms a loose-fitting sleeve called the *dural sheath* around the spinal cord.
 - It is a tough membrane about as thick as a rubber kitchen glove, composed of multiple layers of dense irregular connective tissue.
 - The space between the sheath and vertebral bones, called the epidural space, is occupied by blood vessels, adipose tissue, and loose connective tissue.



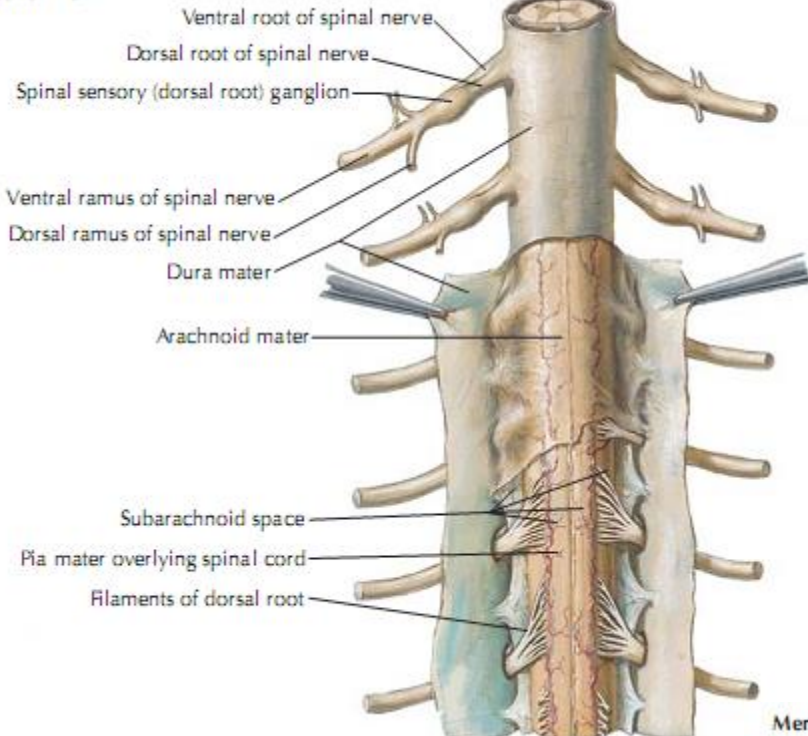
- *Anesthetics are sometimes introduced to this space to block pain signals during childbirth or surgery; this procedure is called **epidural anesthesia**.*





- The **arachnoid mater** consists of the
 - *arachnoid membrane*— five or six layers of squamous to cuboidal cells adhering to the inside of the dura—
 - and a looser array of cells and collagenous and elastic fibers spanning the gap between the arachnoid membrane and the pia mater.
 - This gap, the subarachnoid space, is filled with cerebrospinal fluid (CSF). Inferior to the medullary cone, the subarachnoid space is called the lumbar cistern and is occupied by the cauda equina and CSF.

Posterior view



Membranes removed: anterior view (greatly magnified)

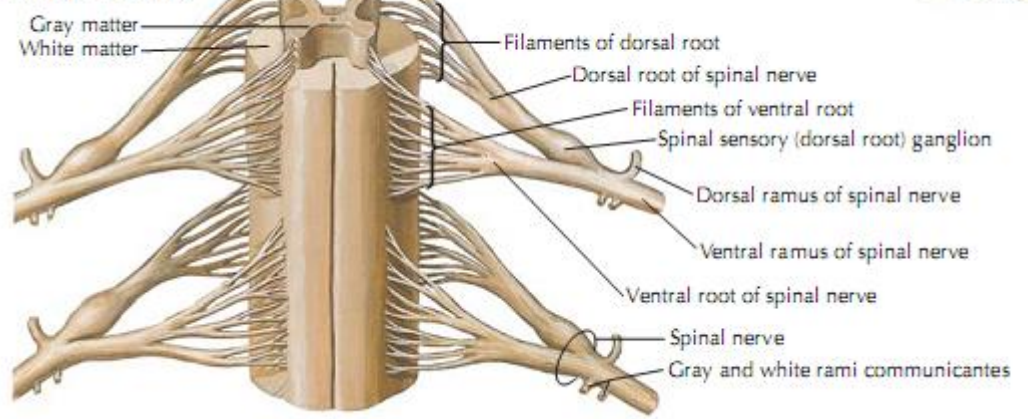


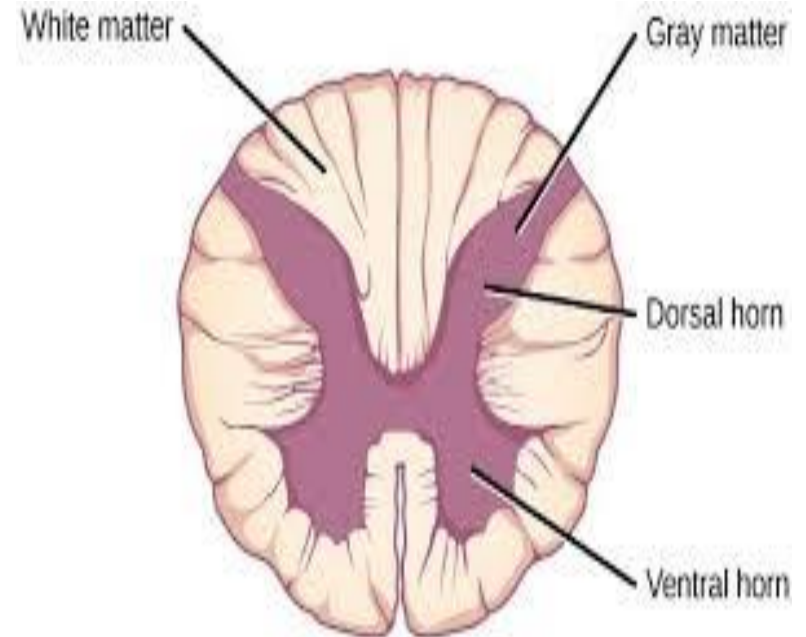
Figure 4.8 Spinal Membranes and Nerve Roots Motor fibers and sensory fibers pass through 31 pairs of spinal nerves. The outer dura mater, arachnoid mater, and inner pia mater are the three coverings of the spinal cord, with CSF circulating in the subarachnoid space.

The *pia mater* is a delicate, transparent membrane composed of one or two layers of squamous to cuboidal cells and delicate collagenous and elastic fibers.

- It closely follows the contours of the spinal cord.
- It continues beyond the medullary cone as a fibrous strand, the terminal filum, within the lumbar cistern.
- At the level of vertebra S2, it exits the lower end of the cistern and fuses with the dura mater, and the two form a *coccygeal ligament* that anchors the cord and meninges to vertebra Co1.
 - At regular intervals along the cord, extensions of the pia called *denticulate ligaments* extend through the arachnoid to the dura, anchoring the cord and limiting side-to-side movements.

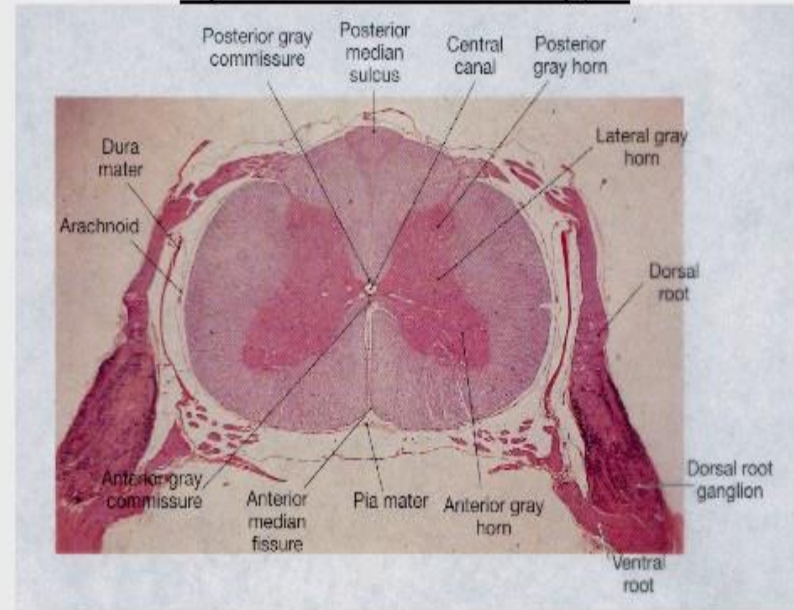
Cross-Sectional Anatomy

- The spinal cord, like the brain, consists of two kinds of nervous tissue called *gray and white matter*.
- *Gray matter*
 - has a relatively dull color because it contains *little myelin*.
 - It contains the somas, dendrites, and proximal parts of the axons of neurons.
 - It is the site of synaptic contact between neurons, and therefore the site of all neural integration in the spinal cord.
- *White matter*, by contrast,
 - has a bright, pearly white appearance due to an *abundance of myelin*.
 - It is composed of bundles of axons, called tracts, that carry signals from one level of the CNS to another.
- Both gray and white matter also have an abundance of *glial cells*.

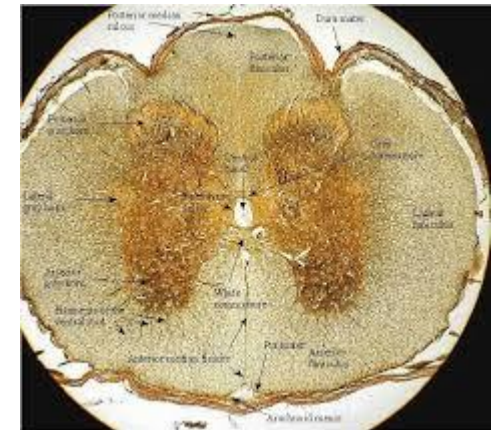


- Nervous tissue is often histologically stained with silver compounds, which give the gray matter a brown or golden color and white matter a lighter tan to amber color.

Spinal Cord w/ Ganglion



<https://www.pinterest.com/pin/521080619362459888/>

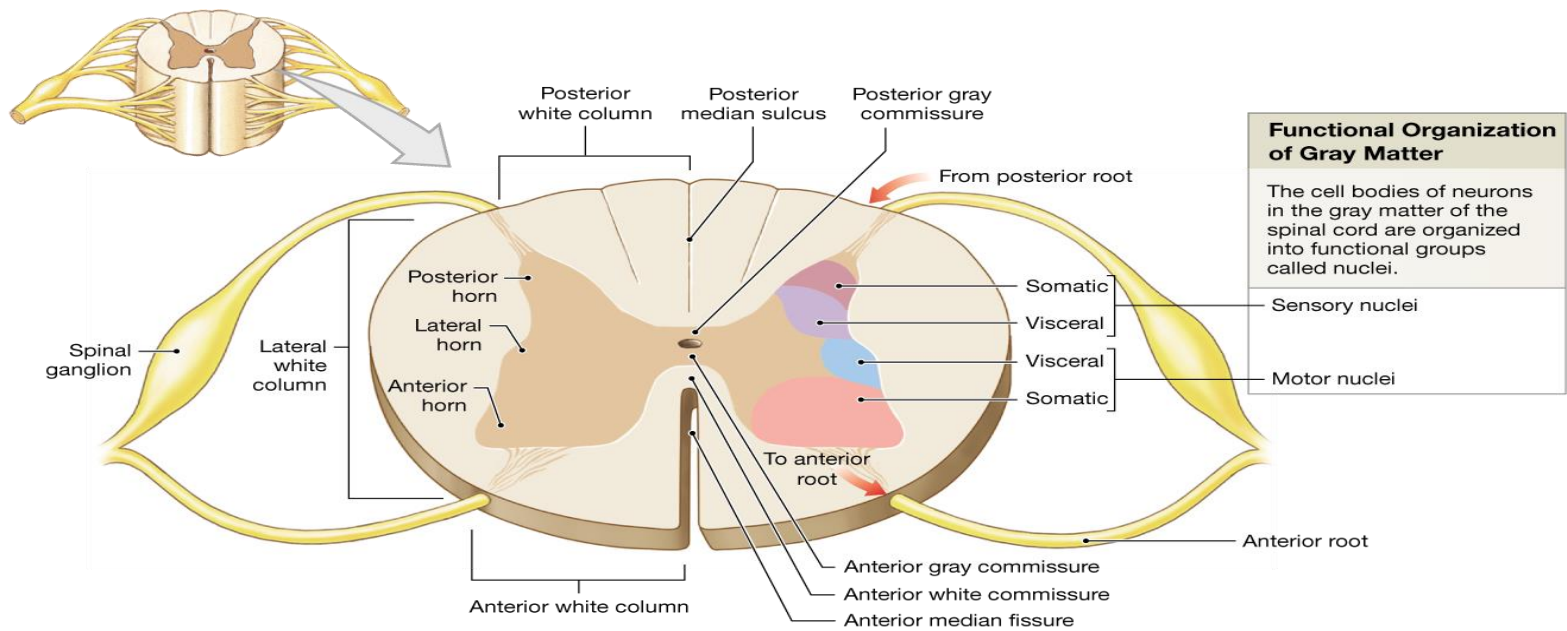


<http://anatomiahumanaust2012.blogspot.com/2012/11/>

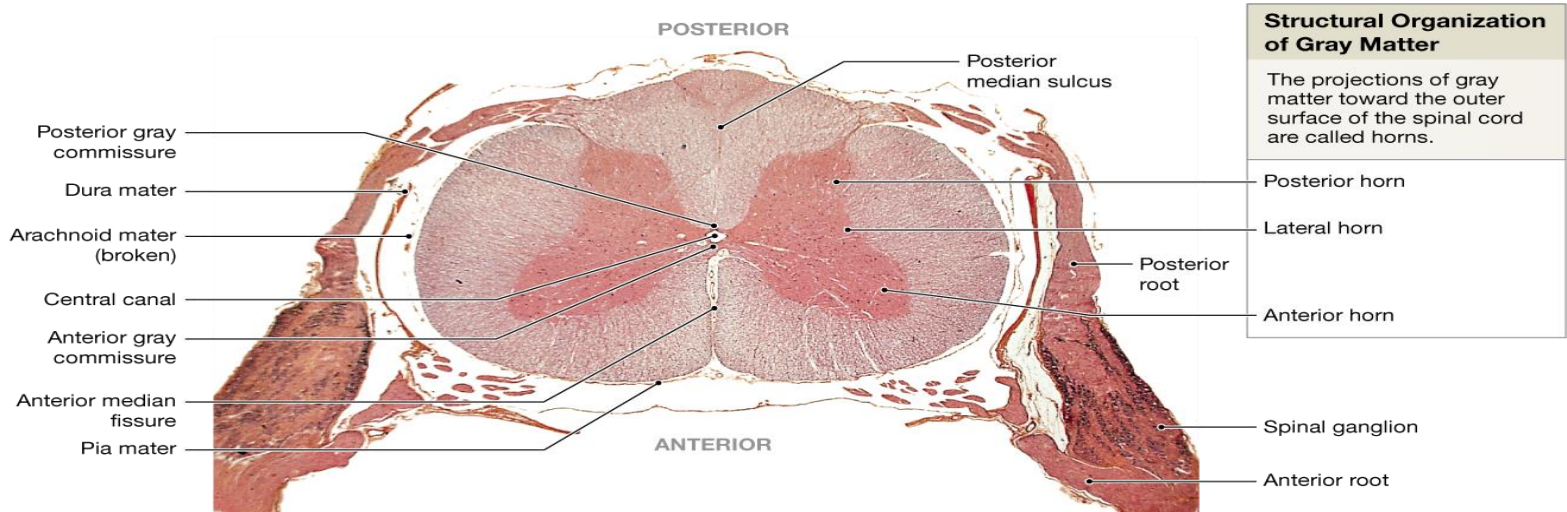
- **Gray Matter**
- The spinal cord has a central core of gray matter that looks somewhat butterfly- or H-shaped in cross sections.
 - The core consists mainly of *two posterior (dorsal) horns* , which extend toward the *posterolateral surfaces* of the cord,
 - and *two thicker anterior (ventral) horns*, which extend toward the *anterolateral surfaces* .
- The right and left sides of the gray matter are connected by a *median bridge* called the *gray commissure*.
 - In the middle of the commissure is the central canal, which is collapsed in most areas of the adult spinal cord, but in some places (and in young children) remains open, lined with ependymal cells, and filled with CSF.

- *The posterior horn receives sensory nerve fibers from the spinal nerves, which usually synapse with networks of interneurons in the horn.*
- *The anterior horn contains the large neurosomas of motor neurons whose axons lead out to the skeletal muscles.*

- *The interneurons* and *motor neurons* are especially *abundant in the cervical and lumbar enlargements* and are quite conspicuous in histological sections from these levels.
 - The high density of neurons in these regions is related to motor control and sensation in the upper and lower limbs.
- *An additional lateral horn is visible on each side of the gray matter from segments T2 through L1 of the cord.*
 - It contains *neurons of the sympathetic nervous system*, which send their axons out of the cord by way of the anterior root along with the somatic efferent fibers.



a The left half of this sectional view shows important anatomical landmarks, including the three columns of white matter. The right half indicates the functional organization of the nuclei in the anterior, lateral, and posterior horns. The red arrows represent sensory input from the posterior root and motor output to the anterior root.



Structural Organization of Gray Matter
The projections of gray matter toward the outer surface of the spinal cord are called horns.

b A micrograph of a transverse section through the spinal cord, showing major landmarks in and surrounding the cord.


- What will be if we cut anterior horn?
- Posterior?

- The functions of the spinal roots were found out using cutting methods and irritation.
- **Prominent Scottish Anatomist and physiologist Bell and French researcher Magendie found that if he one-sided cut the anterior spinal roots there would be paralysis of the limbs on the same side, sensitivity remains completely.**
- **Cutting the posterior roots results in the loss of sensation, motor function is retained.**



 alamy stock photo

François Magendie (1783-1855)



 alamy stock photo

Charles Bell (1774-1842)

- Thus, it was shown that afferent impulses enter spinal cord through the posterior roots(sensitive), efferent impulses come out through the anterior roots(motor).

White Matter

- The white matter of the spinal cord surrounds the gray matter.
 - *It consists of bundles of axons* that course up and down the cord and provide avenues of communication between different levels of the CNS.
- These bundles are arranged in three pairs called *columns or funiculi*—
 - *a posterior (dorsal),*
 - *lateral,*
 - *and anterior (ventral)* column on each side.
 - Each column consists of subdivisions called tracts or fasciculi.

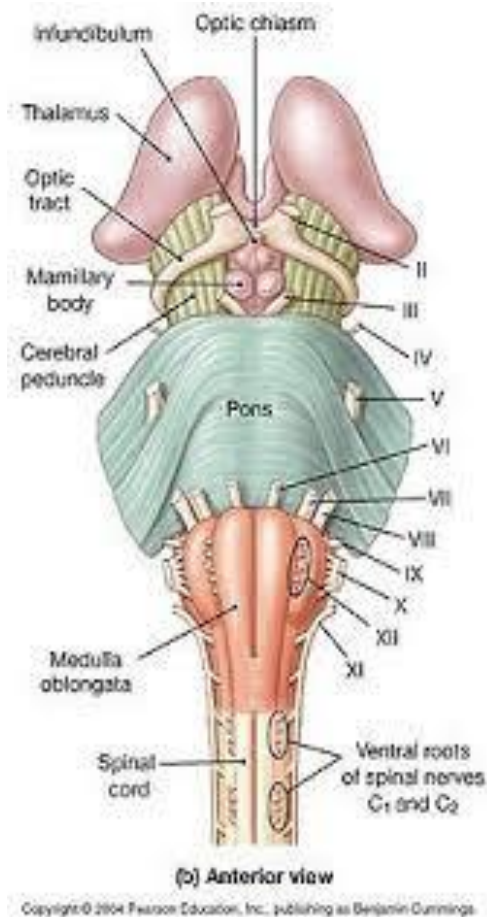
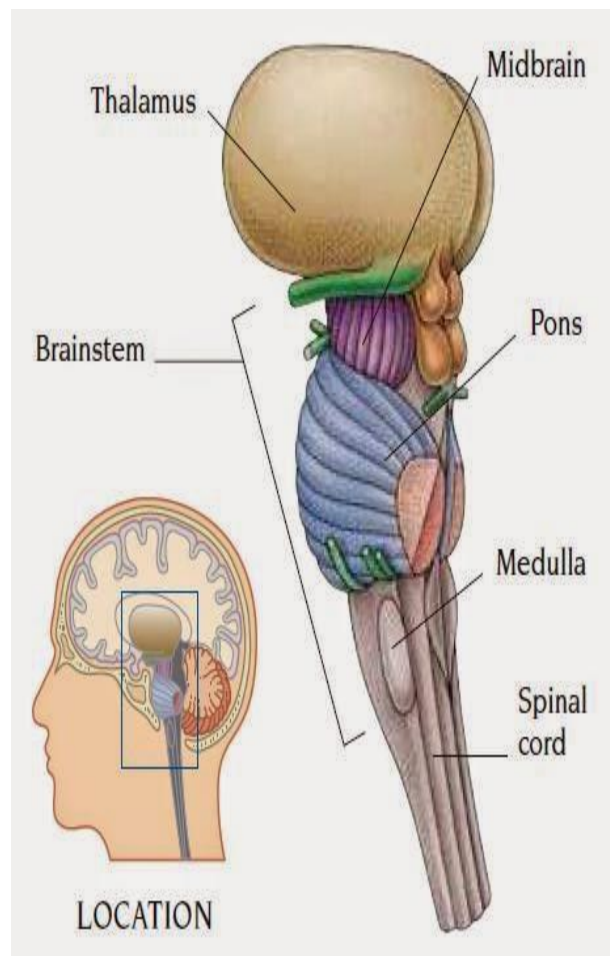
5. Trace the pathways followed by nerve signals travelling up and down the spinal cord

Spinal Tracts

- Knowledge of the locations and functions of the spinal tracts is essential in diagnosing and managing spinal cord injuries.
- *Spinal cord neural pathways are found within the spinal cord white matter.*
 - As we said before on the each side, the white matter is divided into three funiculi: anterior, lateral, and posterior.
- *Ascending tracts* convey information from the periphery to the brain.
- *Descending tracts* carry information from the brain to the periphery.
- The spinal cord is more than just a conduit, as it also modifies and integrates the information that pass through it.

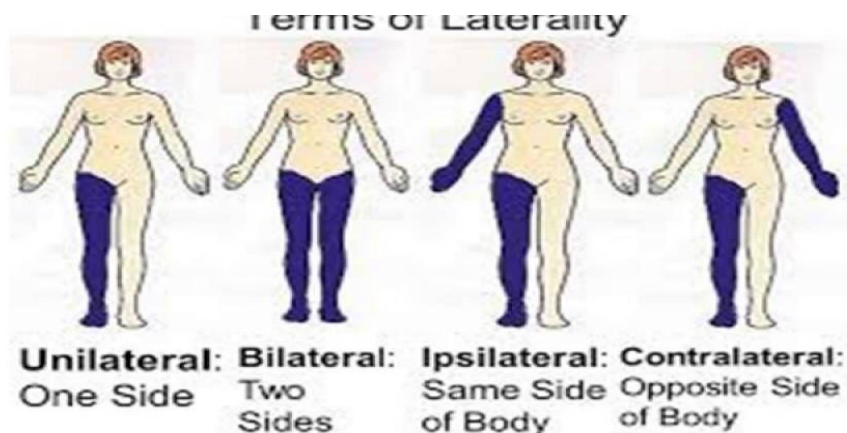
- *All nerve fibers in a given tract have a similar origin, destination, and function.*
- *Many of these fibers have their origin or destination in a region called the **brainstem**.*

- **Brainstem** is a vertical stalk that supports the large cerebellum at the rear of the head and, even larger, two cerebral hemispheres that dominate the brain.



- Several of these tracts undergo *decussation* as they pass up or down the brainstem and spinal cord— *meaning that they cross over from the left side of the body to the right, or vice versa.*
 - As a result, the left side of the brain receives sensory information from the right side of the body and sends motor commands to that side,
 - while the right side of the brain senses and controls the left side of the body.
 - Therefore, *a stroke that damages motor centers of the right side of the brain can cause paralysis of the left limbs and vice versa.*

- When the origin and destination of a tract are on *opposite sides of the body*, we say they are ***contralateral*** to each other.
- When a tract *does not decussate*, its origin and destination are on the same side of the body and we say they are ***ipsilateral***.



<https://www.pinterest.com.mx/pin/784400460082586499/>



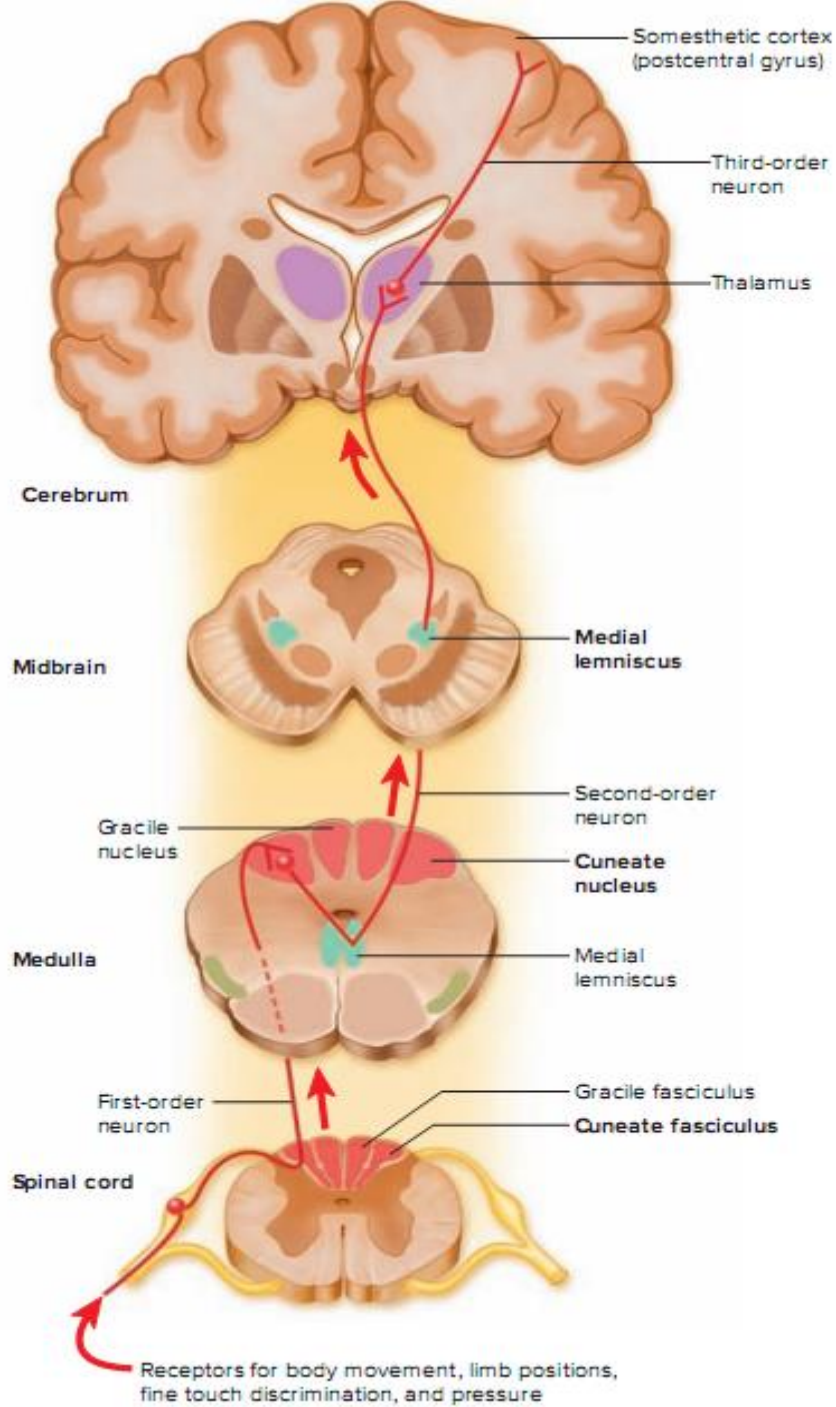
Medically Speaking Radio

Ascending Tracts

- Ascending tracts carry sensory signals up the spinal cord.
- Sensory signals typically travel across *three neurons* from their origin in the receptors to their destination in the brain:
 - *a first-order neuron* that detects a stimulus and transmits a signal to the spinal cord or brainstem;
 - *a second-order neuron* that continues as far as a “gateway” called the thalamus at the upper end of the brainstem;
 - and *a third-order neuron* that carries the signal the rest of the way to the cerebral cortex.
- The axons of these neurons are called the first- through third-order nerve fibers
- *The names of most of them consist of the prefix spino- followed by a root denoting the destination of its fibers in the brain*

The major ascending tracts

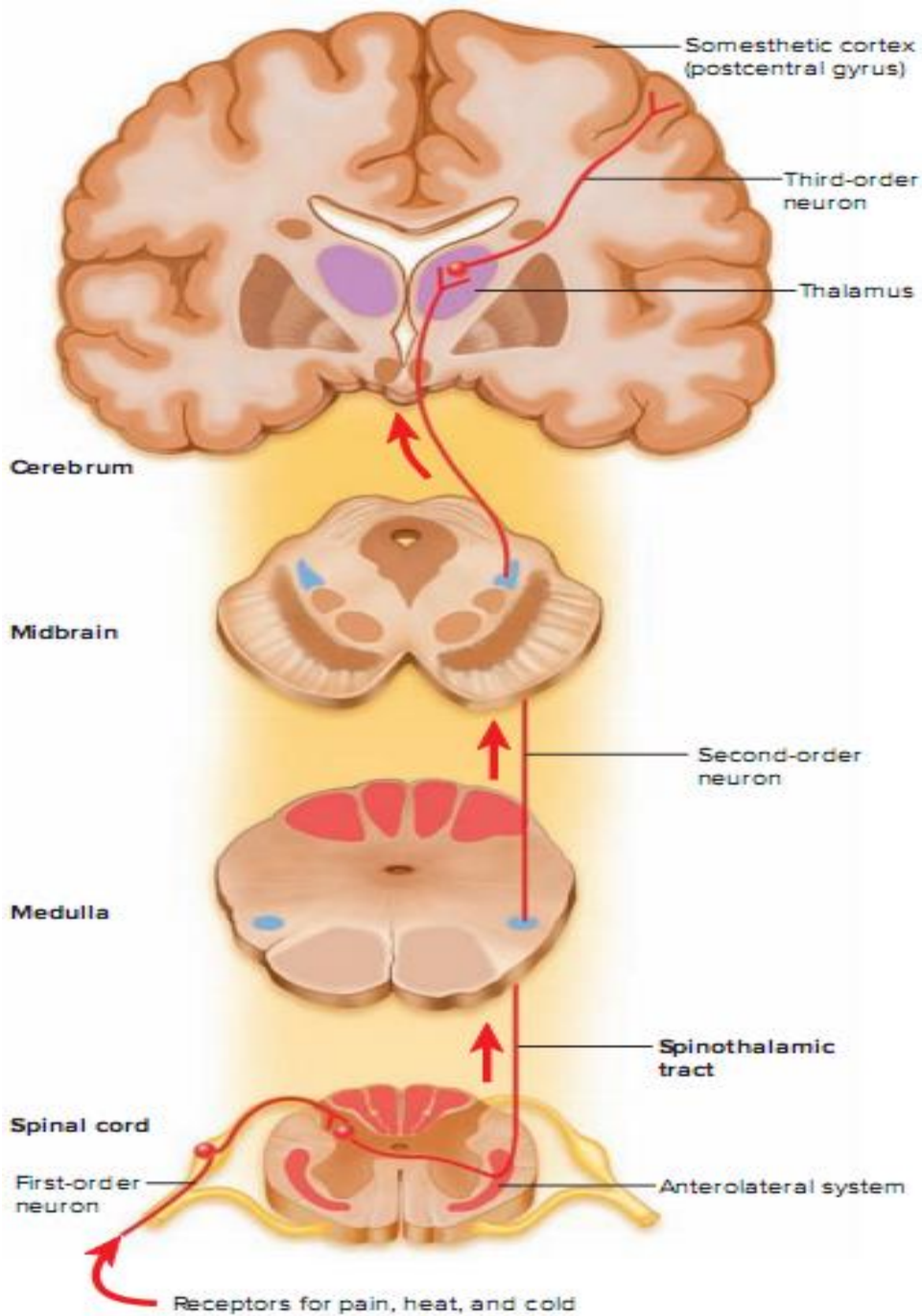
- *The gracile fasciculus* carries signals from the midthoracic and lower parts of the body.
 - Below vertebra T6, it composes the entire posterior column.
 - At T6, it is joined by the *cuneate fasciculus*.
 - It consists of *first-order nerve* fibers that travel up the ipsilateral side of the spinal cord and terminate at the gracile nucleus in the medulla oblongata of the brainstem.
 - *These fibers carry signals for vibration, visceral pain, deep and discriminative touch (touch whose location one can precisely identify), and especially proprioception from the lower limbs and lower trunk.*
- *Proprioception* is the nonvisual sense of the position and movements of the body.



- *The cuneate fasciculus* joins the gracile fasciculus at the T6 level.
- It occupies the lateral portion of the posterior column and forces the *gracile fasciculus* medially.
- It carries the same type of sensory signals, originating from T6 and up (from the upper limbs brainstem to the thalamus).
 - *Third-order fibers* go from the thalamus to the cerebral cortex.
 - *Because of decussation, the signals carried by the gracile and cuneate fasciculi ultimately go to the contralateral cerebral hemisphere.*

The spinothalamic tract and some smaller tracts form the *anterolateral system*, which passes up the anterior and lateral columns of the spinal cord.

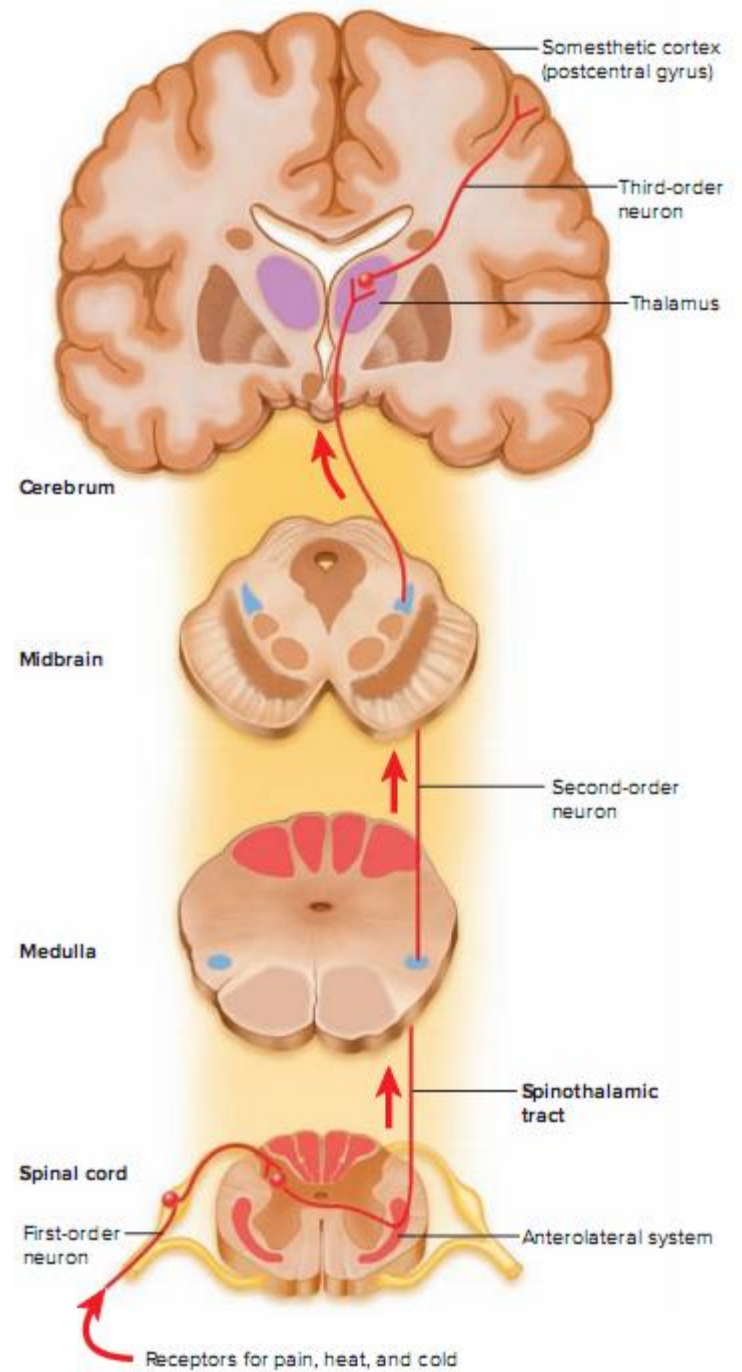
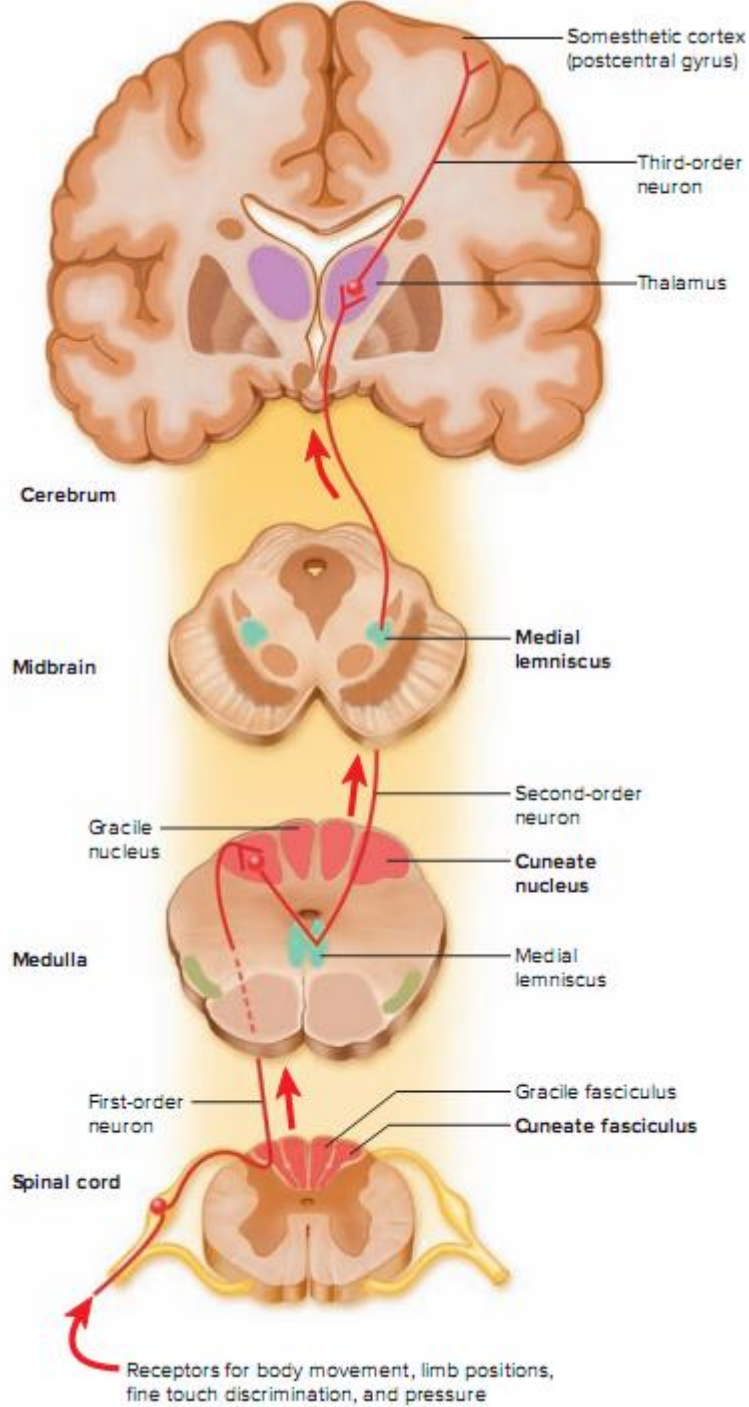
- *The spinothalamic tract* carries signals for pain, temperature, pressure, tickle, itch, and light or crude touch.
 - Light touch is the sensation produced by stroking hairless skin with a feather or cotton wisp, without indenting the skin;
 - crude touch is touch whose location one can only vaguely identify.
- In this pathway,
 - *first-order neurons* end in the posterior horn of the spinal cord near the point of entry.
 - Here they synapse with *second-order neurons*, which decussate and form the contralateral ascending spinothalamic tract. These fibers lead all the way to the thalamus.
 - *Third-order neurons* continue from there to the cerebral cortex.
- *Because of decussation, sensory signals in this tract arrive in the cerebral hemisphere contralateral to their point of origin.*



The spinothalamic tract also travels up the *anterolateral system*.

- It carries pain signals resulting from tissue injury, as will be discussed later in “Projection Pathways for Pain” .
- *The first-order sensory neurons* enter the posterior horn
- and immediately synapse with *second-order neurons*. These decussate to the opposite *anterolateral system*, ascend the cord, and end in a loosely organized core of gray matter called the *reticular formation* in the medulla and pons.
- *Third-order neurons* continue from the pons to the thalamus, and *fourth-order neurons* complete the path from there to the cerebral cortex.

- *The posterior and anterior spinocerebellar tracts* travel through the lateral column and carry proprioceptive signals from the limbs and trunk to the cerebellum at the rear of the brain.
 - Their *first-order neurons* originate in muscles and tendons and end in the posterior horn of the spinal cord.
 - *Second-order neurons* send their fibers up the spinocerebellar tracts and end in the cerebellum.
- Fibers of the *posterior tract* travel up the ipsilateral side of the spinal cord.
 - Those of the anterior tract cross over and *travel up the contralateral side but then cross back in the brainstem to enter the ipsilateral side of the cerebellum.*
- Both tracts provide the cerebellum with feedback needed to coordinate muscle action



Descending Tracts

- Descending tracts carry motor signals down the brainstem and spinal cord.
- A descending motor pathway typically *involves two neurons called the upper and lower motor neurons.*
 - *The upper motor neuron* begins with a soma in the cerebral cortex or brainstem and has an axon that terminates on a *lower motor neuron* in the brainstem or spinal cord.
 - The axon of the *lower motor neuron* then leads the rest of the way to the muscle or other target organ.
- The names of most descending tracts consist of a word root denoting the point of origin in the brain, followed by the suffix -spinal.

The corticospinal tracts *carry motor signals from the cerebral cortex for precise, finely coordinated limb movements.*

- The fibers of this system form ridges called pyramids on the anterior surface of the medulla oblongata, so these tracts were once called *pyramidal tracts*.
 - Most corticospinal fibers decussate in the lower medulla and form the *lateral corticospinal tract* on the contralateral side of the spinal cord.
 - A few fibers remain uncrossed and form *the anterior corticospinal tract* on the ipsilateral side.
- Fibers of the anterior tract decussate lower in the cord, however, so even they control contralateral muscles.
 - This tract gets smaller as it descends and gives off nerve fibers, and usually disappears by the midthoracic level.

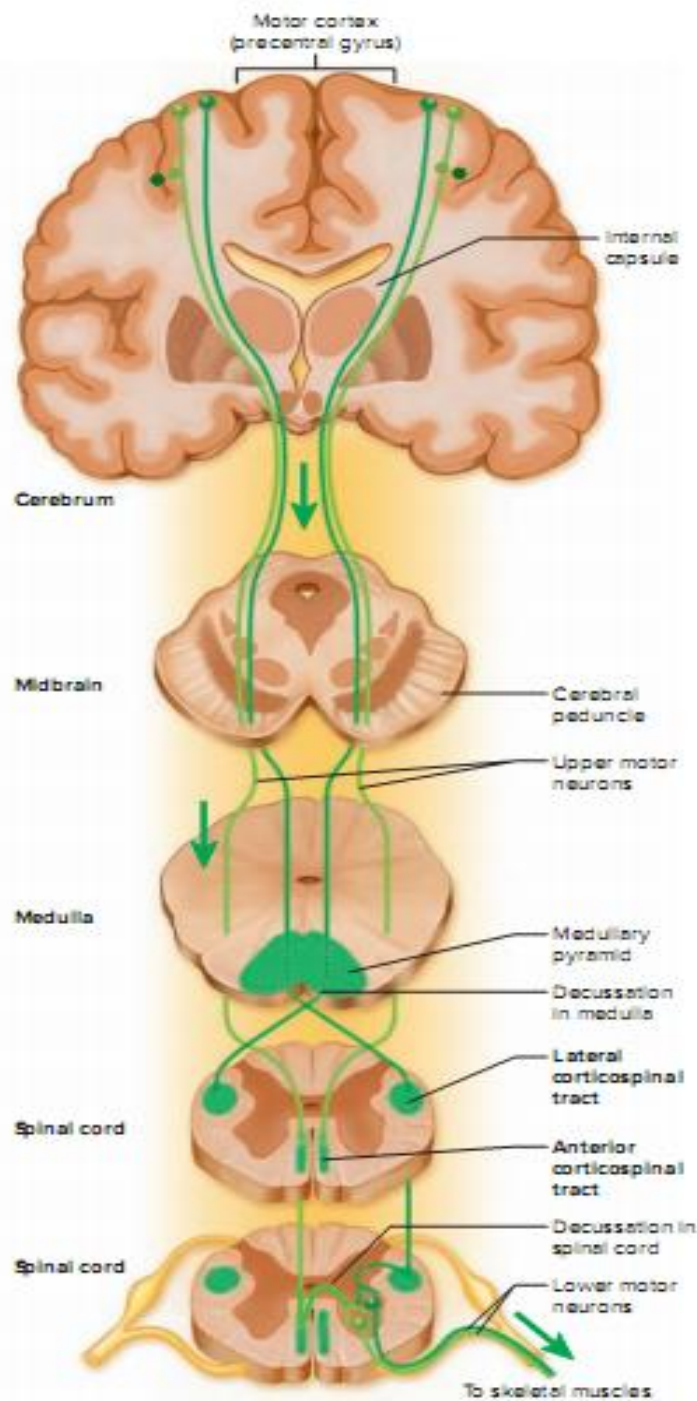


FIGURE 13.6 Two Descending Pathways of the CNS. The lateral and anterior corticospinal tracts, which carry signals for voluntary muscle contraction. Nerve signals originate in the cerebral cortex at the top of the figure and carry motor commands down the spinal cord.

The tectospinal tract begins in a midbrain region called the *tectum* and crosses to the contralateral side of the midbrain.

- It descends through the brainstem to the upper spinal cord on that side, going only as far as the neck.
- It is involved in reflex turning of the head, especially in response to sights and sounds.

- **The lateral and medial reticulospinal tracts** *originate in the reticular formation* of the brainstem.
 - They control muscles of the upper and lower limbs, especially to maintain posture and balance.
 - They also contain descending analgesic pathways that reduce the transmission of pain signals to the brain

The lateral and medial vestibulospinal tracts begin in the brainstem vestibular nuclei, which receive signals for balance from the inner ear.

- *The lateral vestibulospinal tract* passes down the anterior column of the spinal cord and facilitates neurons that control extensor muscles of the limbs, thus inducing the limbs to stiffen and straighten.
 - This is an important reflex in responding to body tilt and keeping one's balance.
- *The medial vestibulospinal tract* splits into ipsilateral and contralateral fibers that descend through the anterior column on both sides of the cord and terminate in the neck.
 - It plays a role in the control of head position.

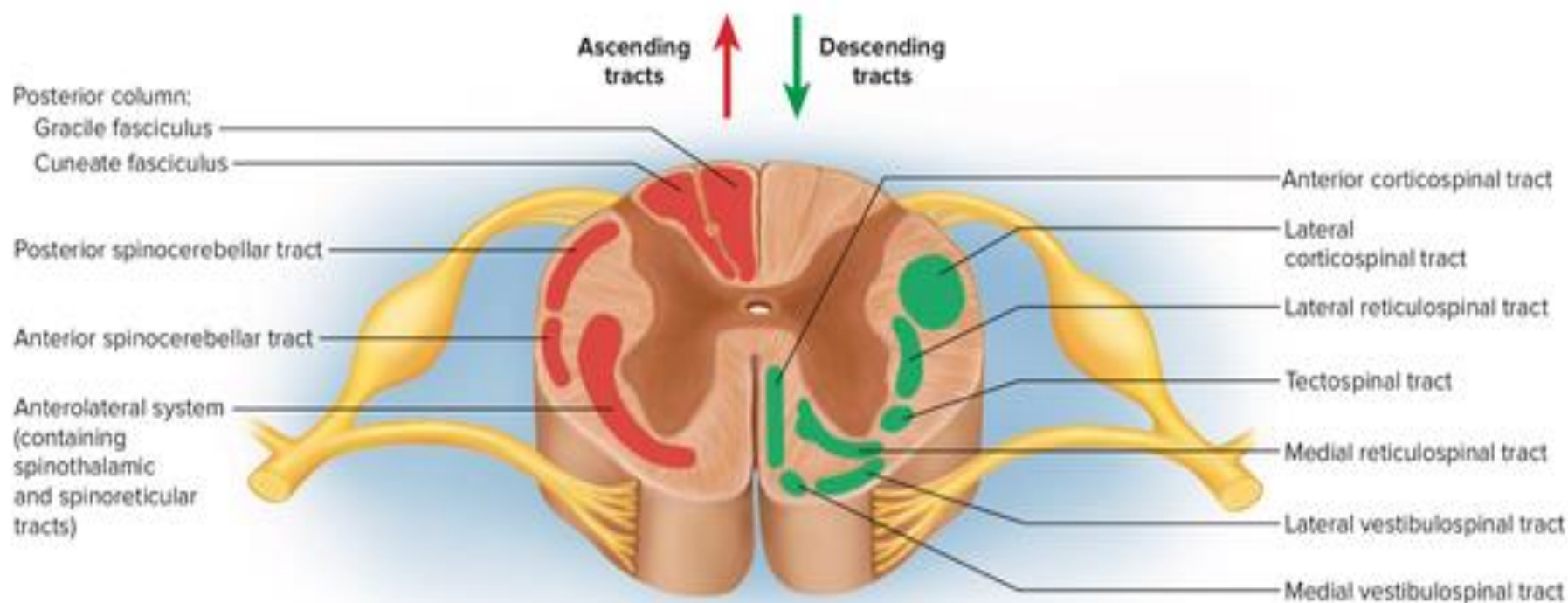


FIGURE 13.4 Tracts of the Spinal Cord. All of the illustrated tracts occur on both sides of the cord, but only the ascending sensory tracts are shown on the left (red), and only the descending motor tracts on the right (green).

Motor and descending (efferent) pathways (red)

Pyramidal tracts

- Lateral corticospinal tract
- Anterior corticospinal tract

Extrapyramidal Tracts

- Rubrospinal tract
- Reticulospinal tracts
- Olivospinal tract
- Vestibulospinal tract

Sensory and ascending (afferent) pathways (blue)

Dorsal Column Medial Lemniscus System

- Gracile fasciculus
- Cuneate fasciculus

Spinocerebellar Tracts

- Posterior spinocerebellar tract
- Anterior spinocerebellar tract

Anterolateral System

- Lateral spinothalamic tract
- Anterior spinothalamic tract

Spino-olivary fibers

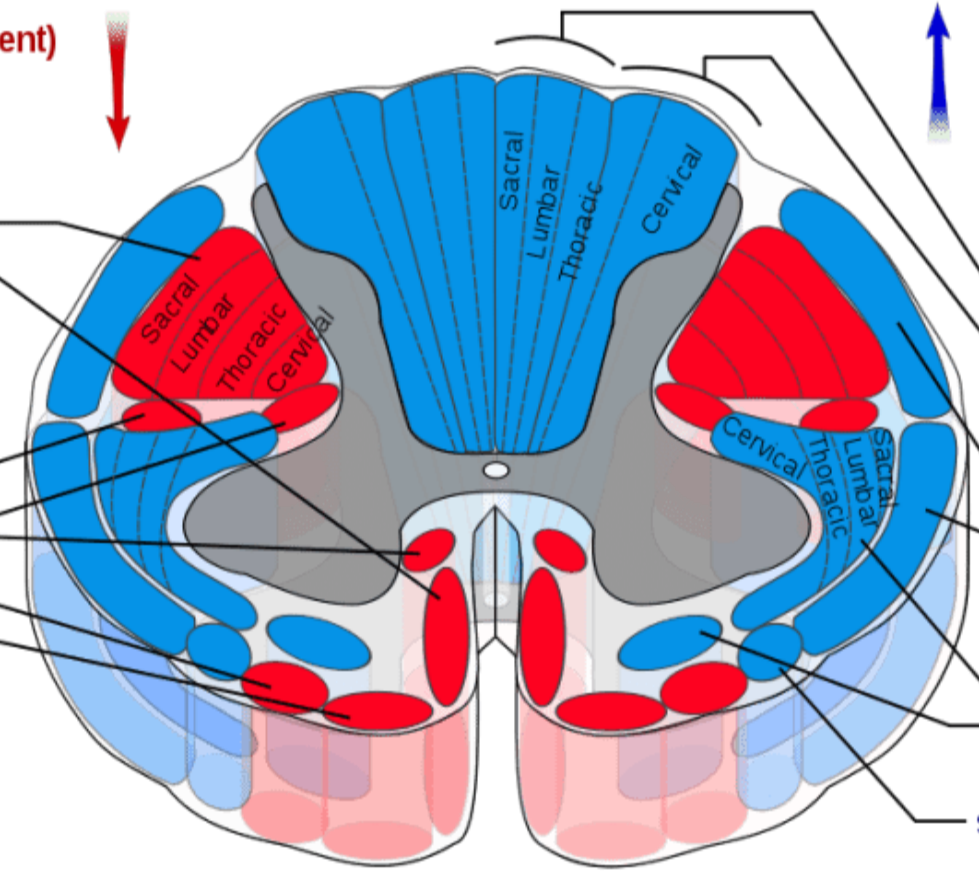


TABLE 13.1**Major Spinal Tracts**

Tract	Column	Decussation	Functions
Ascending (Sensory) Tracts			
Gracile fasciculus	Posterior	In medulla	Sensations of limb and trunk position and movement, deep touch, visceral pain, and vibration, below level T6 touch, visceral pain, and vibration, below level T6
Cuneate fasciculus	Posterior	In medulla	Same as gracile fasciculus, from level T6 up
Spinothalamic	Lateral and anterior	In spinal cord	Sensations of light touch, tickle, itch, temperature, pain, and pressure
Spinoreticular	Lateral and anterior	In spinal cord (some fibers) (some fibers)	Sensation of pain from tissue injury
Posterior spinocerebellar	Lateral	None	Feedback from muscles (proprioception)
Anterior spinocerebellar	Lateral	In spinal cord	Same as posterior spinocerebellar
Descending (Motor) Tracts			
Lateral corticospinal	Lateral	In medulla	Fine control of limbs
Anterior corticospinal	Anterior	In spinal cord	Fine control of limbs
Tectospinal	Anterior	In midbrain	Reflexive head turning in response to visual and auditory stimuli
Lateral reticulospinal	Lateral	None	Balance and posture; regulation of awareness of pain
Medial reticulospinal	Anterior	None	Same as lateral reticulospinal
Lateral vestibulospinal	Anterior	None	Balance and posture
Medial vestibulospinal	Anterior	In medulla (some fibers) (some fibers)	Control of head position

Anterior funiculus

Ascending tract:

- Anterior spinothalamic tract

Descending tracts:

- Anterior corticospinal tract
- Vestibulospinal tract
- Tectospinal tract
- Reticulospinal tract

Lateral funiculus

Ascending tracts:

- Posterior spinocerebellar tract
- Anterior spinocerebellar tract
- Lateral spinothalamic tract
- Spinotectal tract
- Posterolateral tract of Lissauer
- Spinoreticular tract
- Spino-olivary tract

Descending tracts:

- Lateral corticospinal tract
- Rubrospinal tract
- Lateral reticulospinal tract
- Descending autonomic tracts
- Olivospinal tract

Posterior funiculus

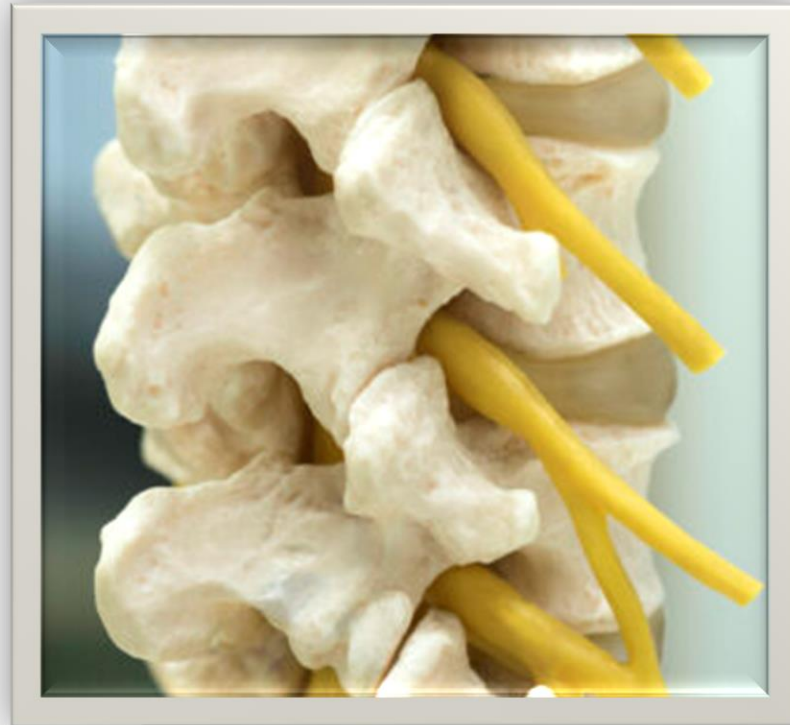
Ascending tracts:

- Gracile fasciculus of Gol
- Cuneate fasciculus of Burdach



**Al-Farabi Kazakh
National
University
Higher School of
Medicine**

The spinal nerves



<https://drdavidchangmd.com/how-to-treat-compressed-spinal-nerves/>

LEARNING OUTCOMES

As a result of the lesson you will be able to:

- ✓ ***Describe the anatomy of nerves and ganglia in general;***
- ✓ ***Describe the attachments of a spinal nerve to a spinal cord;***
- ✓ ***Trace the branches of a spinal nerve distal to its attachments;***
- ✓ ***Name the five plexuses of a spinal nerves and describe their general anatomy;***
- ✓ ***Name some major nerves that arise from each plexus;***
- ✓ ***Explain the relationship of dermatomes to the spinal nerves.***

1. Describe the anatomy of nerves and ganglia in general

- ***A nerve***

- is a cordlike organ composed of numerous nerve fibers (axons) bound together by connective tissue.

- *If we compare a nerve fiber to a wire carrying an electrical current in one direction, a nerve would be comparable to an electrical cable composed of thousands of wires carrying currents in opposite directions.*

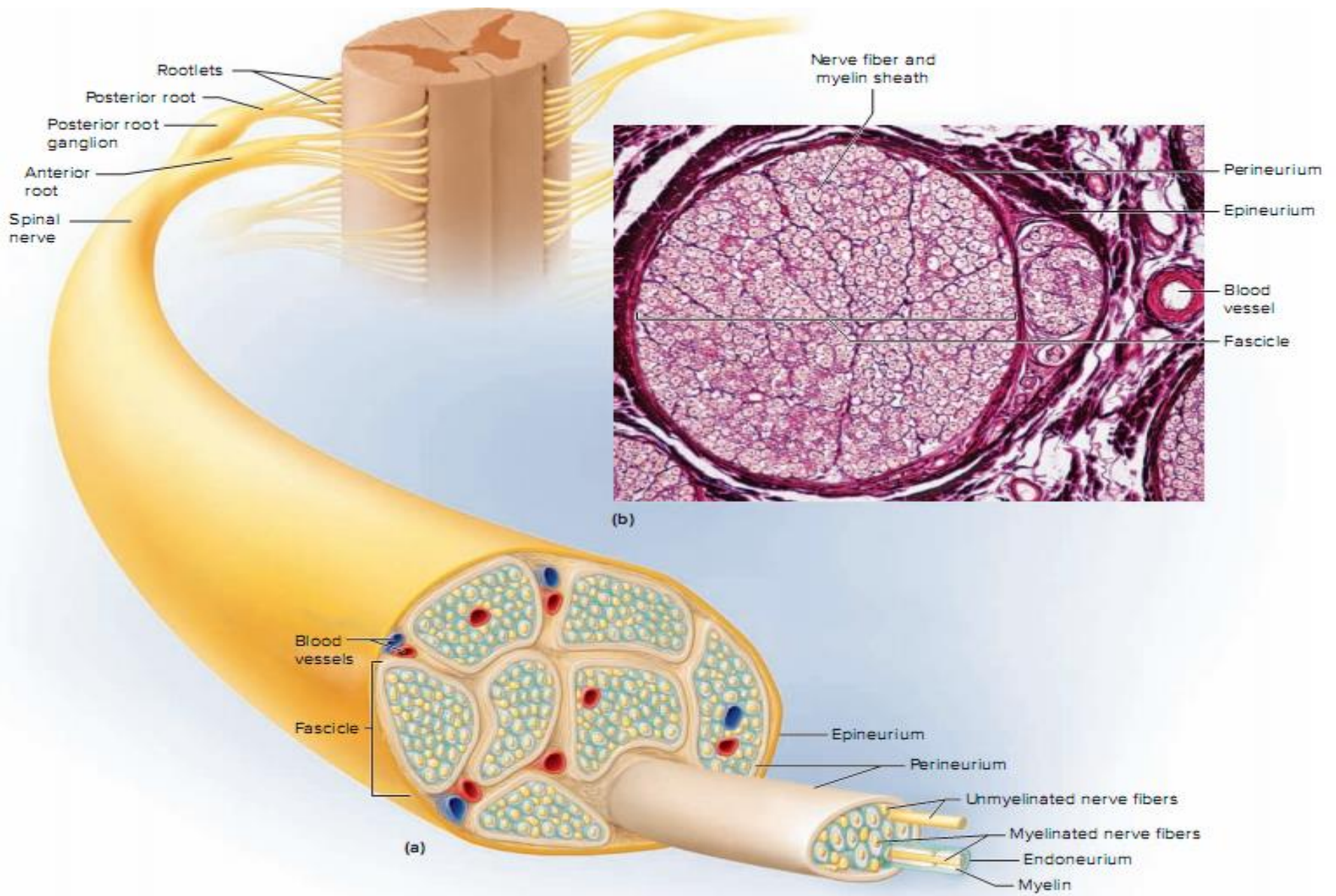


FIGURE 13.8 Anatomy of a Nerve. (a) A spinal nerve and its association with the spinal cord. (b) Cross section of a nerve. Individual nerve fibers show as tiny red dots, each surrounded by a light ring of myelin. b: © ISM/Phototake

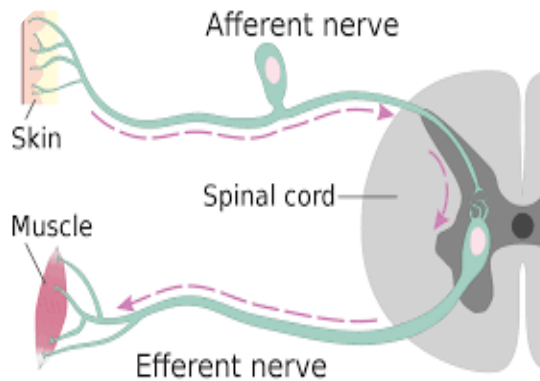
- *A **nerve** contains anywhere from a few nerve fibers to (in the optic nerve) a million.*
- Nerves usually have a pearly white color and resemble frayed string as they divide into smaller and smaller branches.
- *As we move away from the spinal nerves proper, the smaller branches are called peripheral nerves, and their disorders are collectively called peripheral neuropathy*

- Nerve fibers of the peripheral nervous system are ensheathed in Schwann cells, which form a *neurilemma* and often a myelin sheath around the axon.
- External to the *neurilemma*, each fiber is surrounded by a basal lamina and then a thin sleeve of loose connective tissue called the *endoneurium*.
- In most nerves, the fibers are gathered in bundles called fascicles, each wrapped in a sheath called the *perineurium*.
 - The perineurium is composed of up to 20 layers of overlapping, squamous, epithelium like cells. Several fascicles are then bundled together and wrapped in an outer *epineurium* to compose the nerve as a whole.
 - The *epineurium* consists of dense irregular connective tissue and protects the nerve from stretching and injury.
- Nerves have a high metabolic rate and need a plentiful blood supply, which is furnished by blood vessels that penetrate these connective tissue coverings

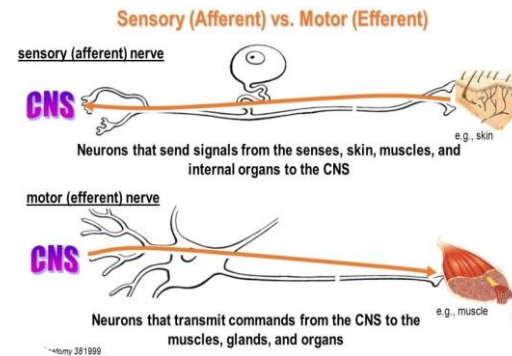
- ❖ How does the structure of a nerve compare to that of a skeletal muscle?

- ❖ Which of the descriptive terms for nerves have similar counterparts in muscle histology?

- As we know, peripheral nerve fibers are of two kinds:



sensory (afferent) fibers carrying signals from sensory receptors to the CNS, and motor (efferent) fibers carrying signals from the CNS to muscles and glands.



https://da.wikipedia.org/wiki/Fil:Afferent_and_efferent_neurons_en.svg

<https://www.pinterest.com/pin/782641241468613248/>

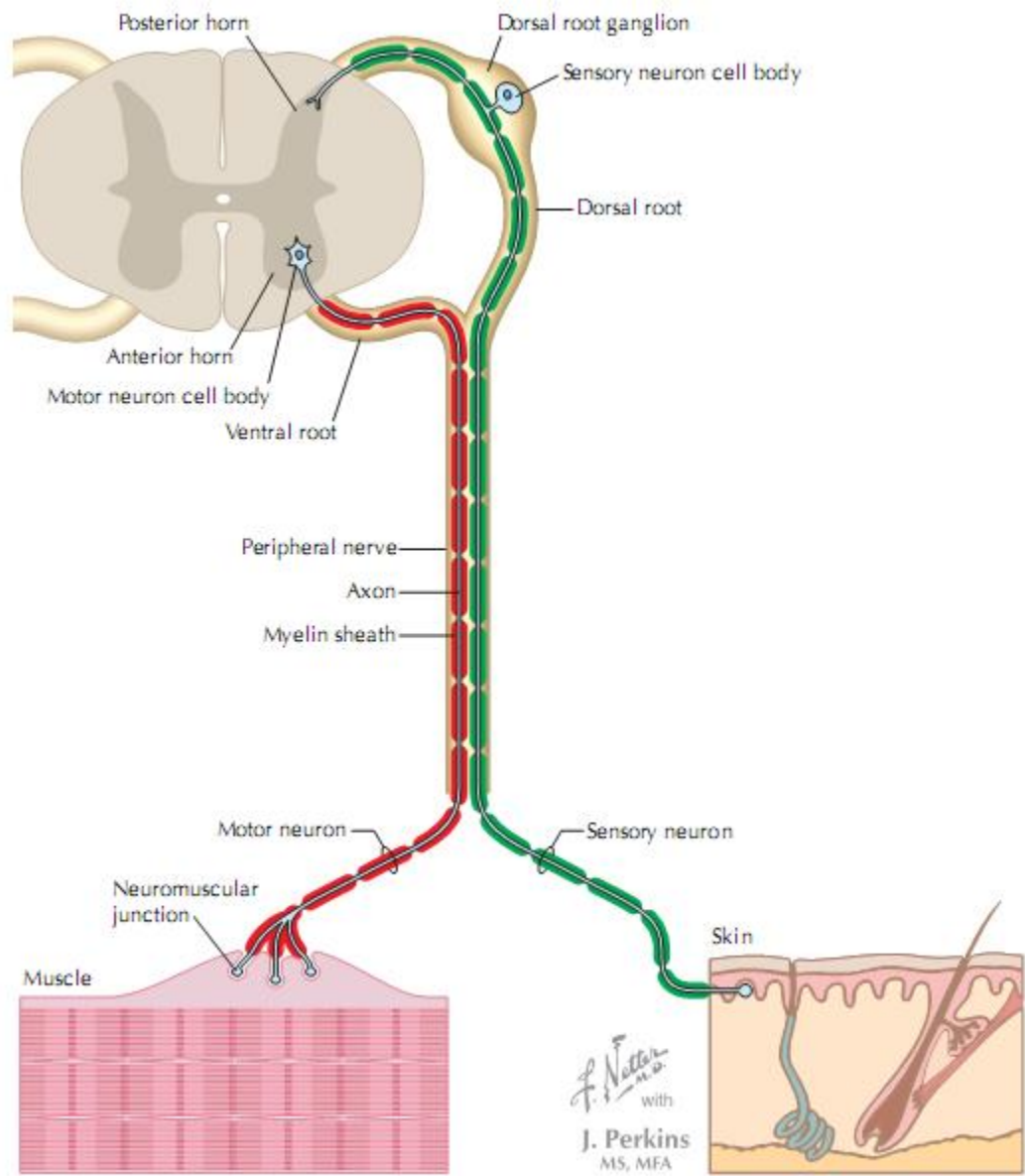


Figure 4.9 Somatic Component of the Peripheral Nervous System The peripheral nervous system can be subdivided into somatic and autonomic components. The somatic nervous system contains motor nerves and sensory nerves innervating skin and muscle. The soma (cell bodies) of motor nerves and sensory nerves are located in the gray matter of the anterior horn of the spinal cord and in the dorsal root ganglia, respectively.

Both types can be classified as somatic or visceral and as general or special depending on the organs they innervate

TABLE 13.2	
The Classification of Nerve Fibers	
Class	Description
Afferent fibers	Carry sensory signals from receptors to the CNS
Efferent fibers	Carry motor signals from the CNS to effectors
Somatic fibers	Innervate skin, skeletal muscles, bones, and joints
Visceral fibers	Innervate blood vessels, glands, and viscera
General fibers	Innervate widespread organs such as muscles, skin, glands, viscera, and blood vessels
Special fibers	Innervate more localized organs in the head, including the eyes, ears, olfactory and taste receptors, and muscles of chewing, swallowing, and facial expression

- Purely *sensory nerves*, composed only of afferent fibers, are rare;
 - they include nerves for smell and vision.
- *Motor nerves carry only efferent fibers.*
- Most nerves, however, are mixed nerves,
 - which consist of both afferent and efferent fibers and therefore conduct signals in two directions.
- *However, any one fiber in the nerve conducts signals in one direction only.*
- Many nerves commonly described as motor are actually mixed because they carry sensory signals of proprioception from the muscle back to the CNS.

- If a nerve resembles a thread, a *ganglion* resembles a knot in the thread.
- A ganglion is a cluster of *neurosomas* outside the CNS.
 - It is enveloped in an *epineurium* continuous with that of the nerve.
 - Among the neurosomas are bundles of nerve fibers leading into and out of the ganglion.

? Where are the somas of the neurons that give rise to the motor nerve fibers seen here?

type of ganglion associated with the spinal nerves

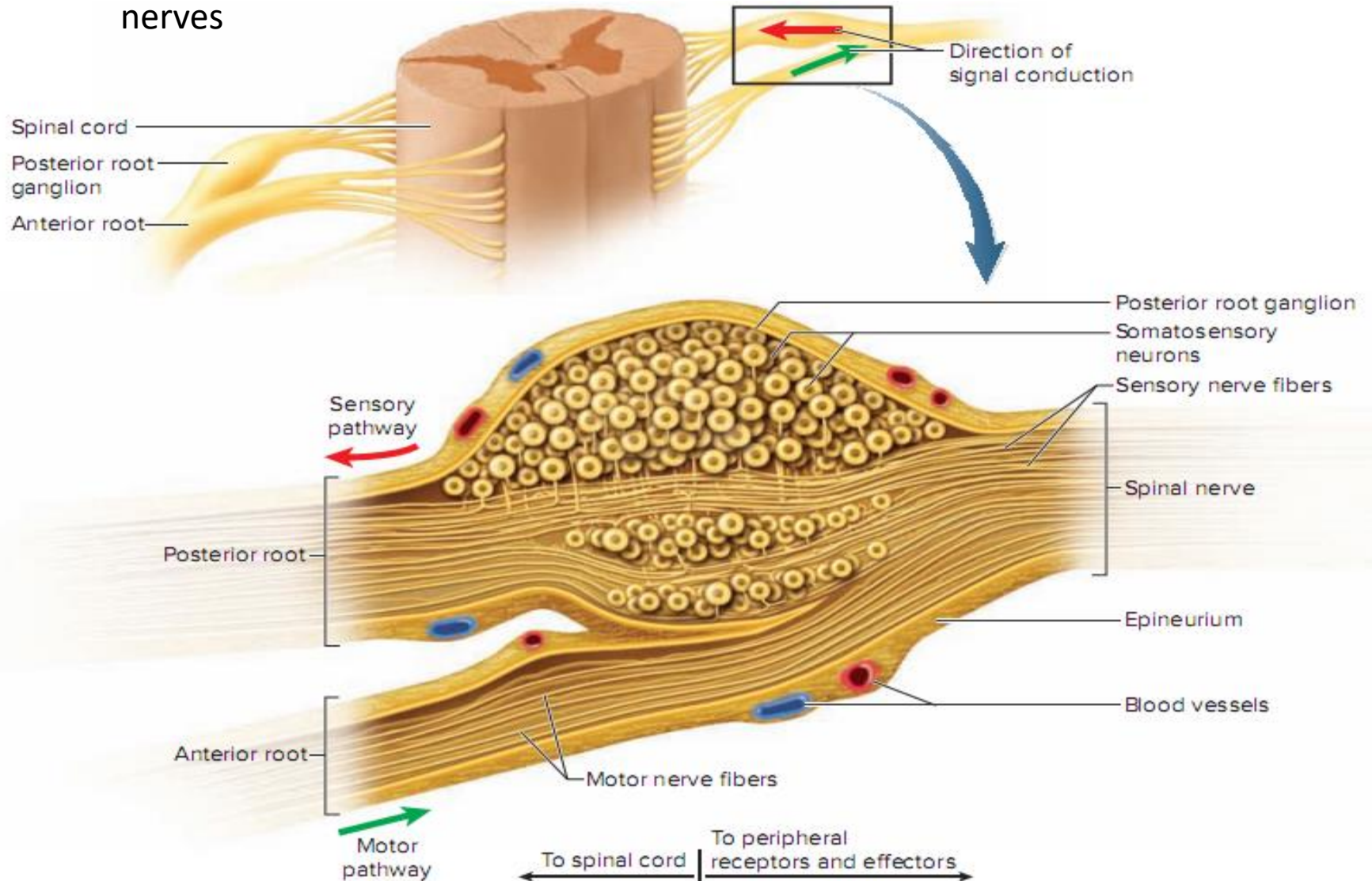
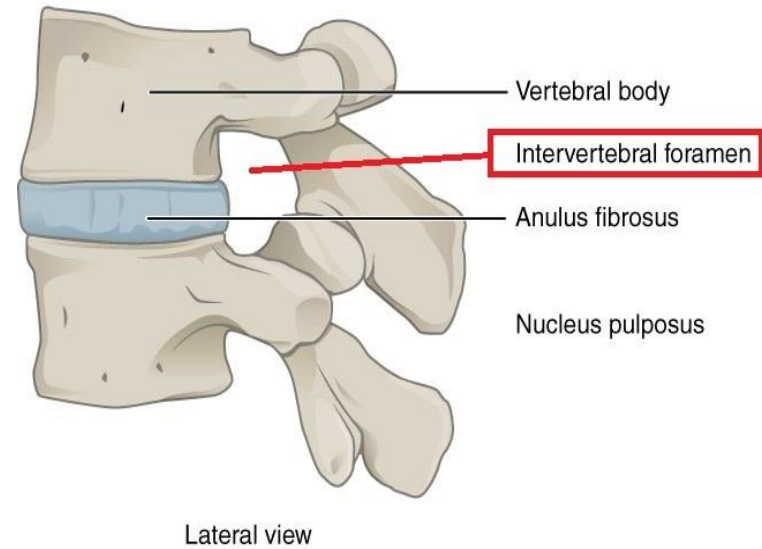


FIGURE 13.9 Anatomy of a Ganglion (Longitudinal Section). The posterior root ganglion contains the somas of unipolar sensory neurons conducting signals from peripheral sense organs toward the spinal cord. Below this is the anterior root of the spinal nerve, which conducts motor signals away from the spinal cord, toward peripheral effectors. (The anterior root is not part of the ganglion.)

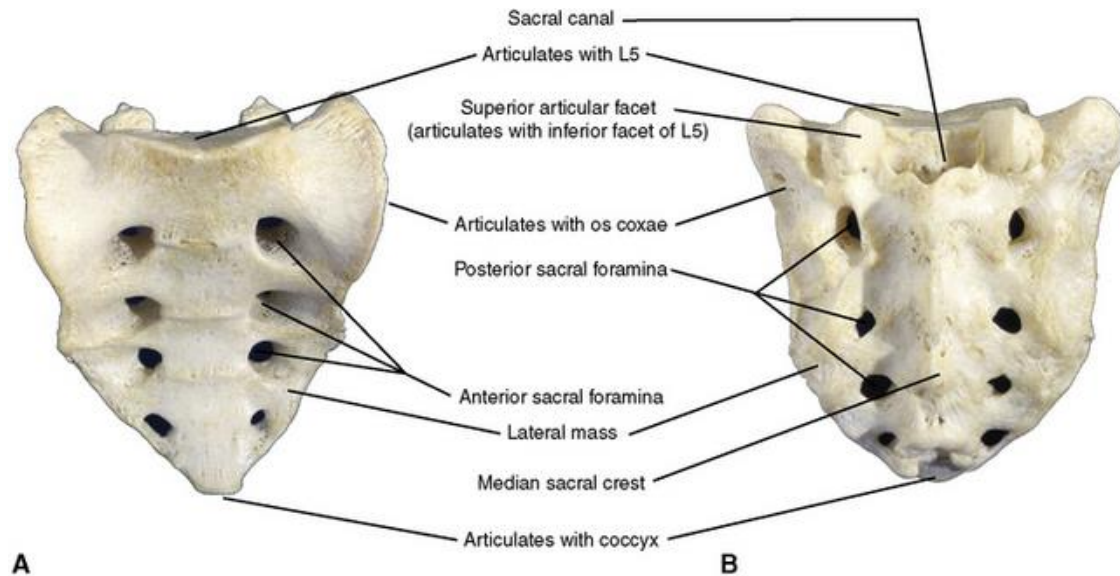
2. Describe the attachments of a spinal nerve to the spinal cord

- **Spinal Nerves**
- There are 31 pairs of spinal nerves:
 - 8 cervical (C1–C8),
 - 12 thoracic (T1–T12),
 - 5 lumbar (L1–L5),
 - 5 sacral (S1–S5),
 - and 1 coccygeal (Co1).

- *The first cervical nerve emerges between the skull and atlas, and the others emerge through intervertebral foramina, including the anterior and posterior foramina of the sacrum and the sacral hiatus.*



<https://radiopaedia.org/articles/intervertebral-foramen-1?lang=us>



<https://pocketdentistry.com/2-the-back/>

- Thus,
 - spinal nerves C1 through C7 emerge superior to the correspondingly numbered vertebrae (nerve C5 above vertebra C5, for example);
 - nerve C8 emerges inferior to vertebra C7; and below this,
 - all the remaining nerves emerge inferior to the correspondingly numbered vertebrae (nerve L3 inferior to vertebra L3, for example).

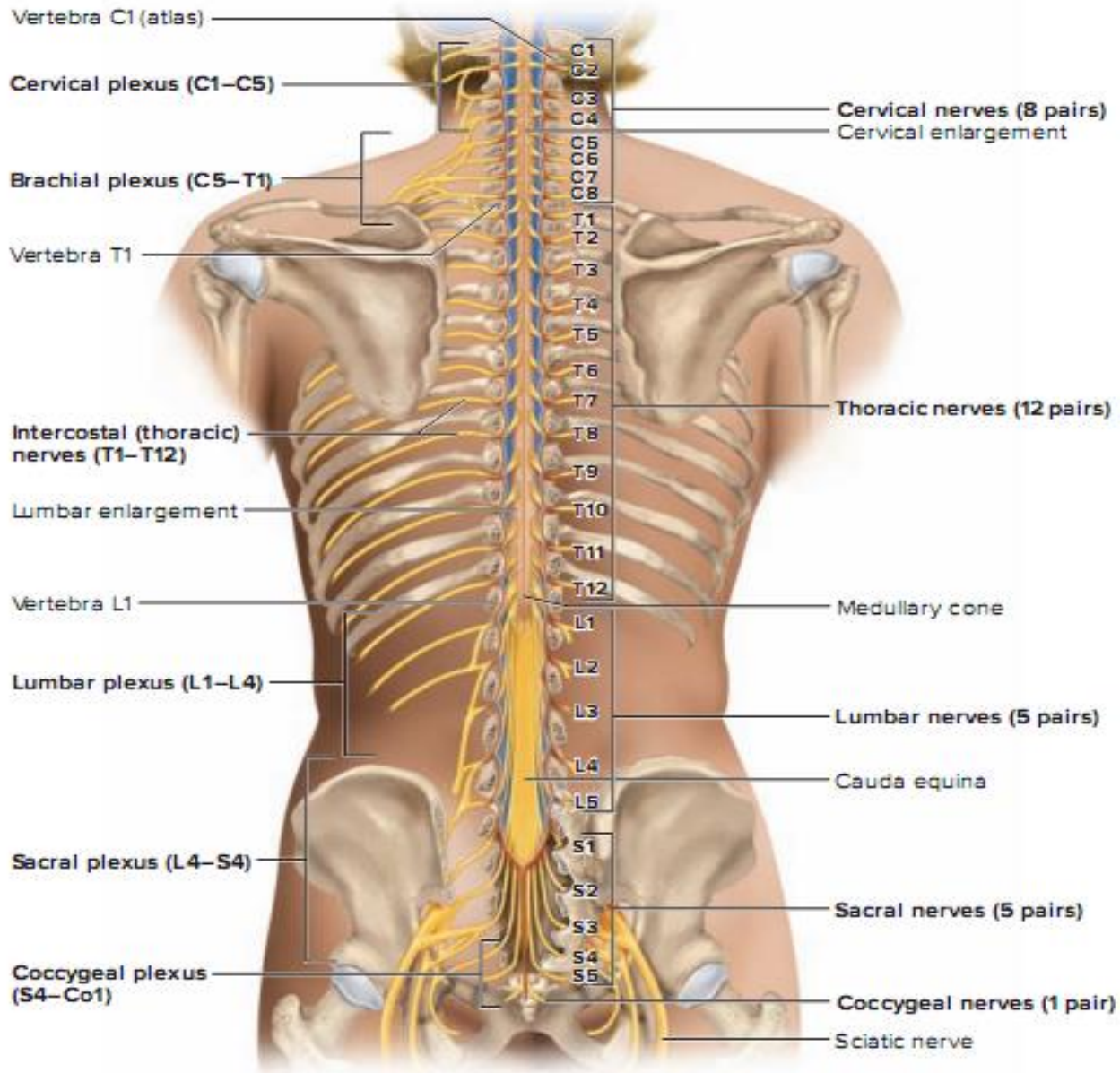


FIGURE 13.10 The Spinal Nerve Roots and Plexuses, Posterior View.

Proximal Branches

- Each spinal nerve arises from two points of attachment to the spinal cord.
 - In each segment of the cord, six to eight nerve rootlets emerge from the anterior surface and converge to form the anterior (ventral) root of the spinal nerve.
 - Another six to eight rootlets emerge from the posterior surface and converge to form the posterior (dorsal) root.
 - A short distance away from the spinal cord, the posterior root swells into a posterior (dorsal) root ganglion, which contains the somas of sensory neurons.
 - *There is no corresponding ganglion on the anterior root.*

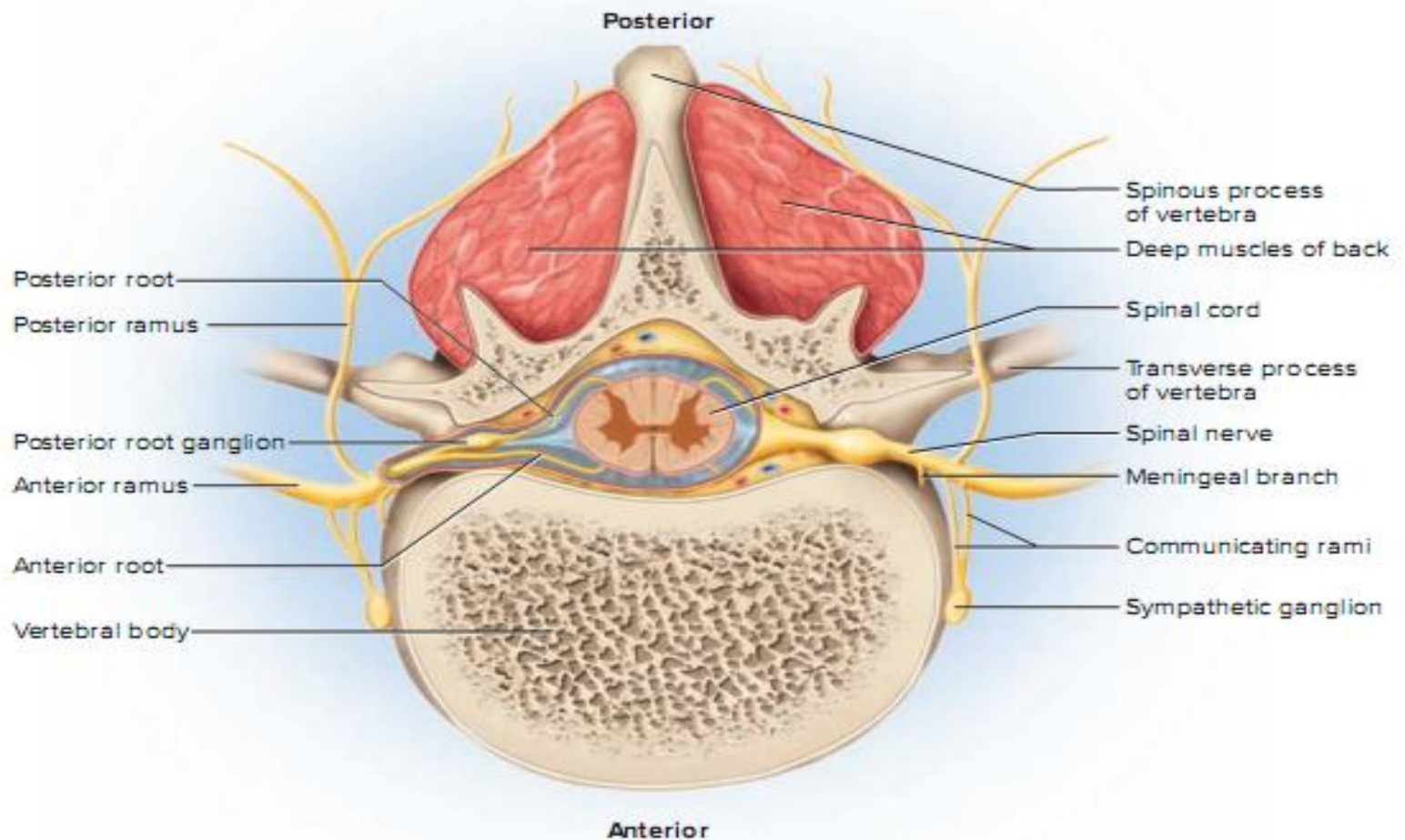


FIGURE 13.11 Branches of a Spinal Nerve in Relation to the Spinal Cord and Vertebra (Cross Section).

? In the labeled rootlets of spinal nerve C5, are the nerve fibers afferent or efferent? How do you know?

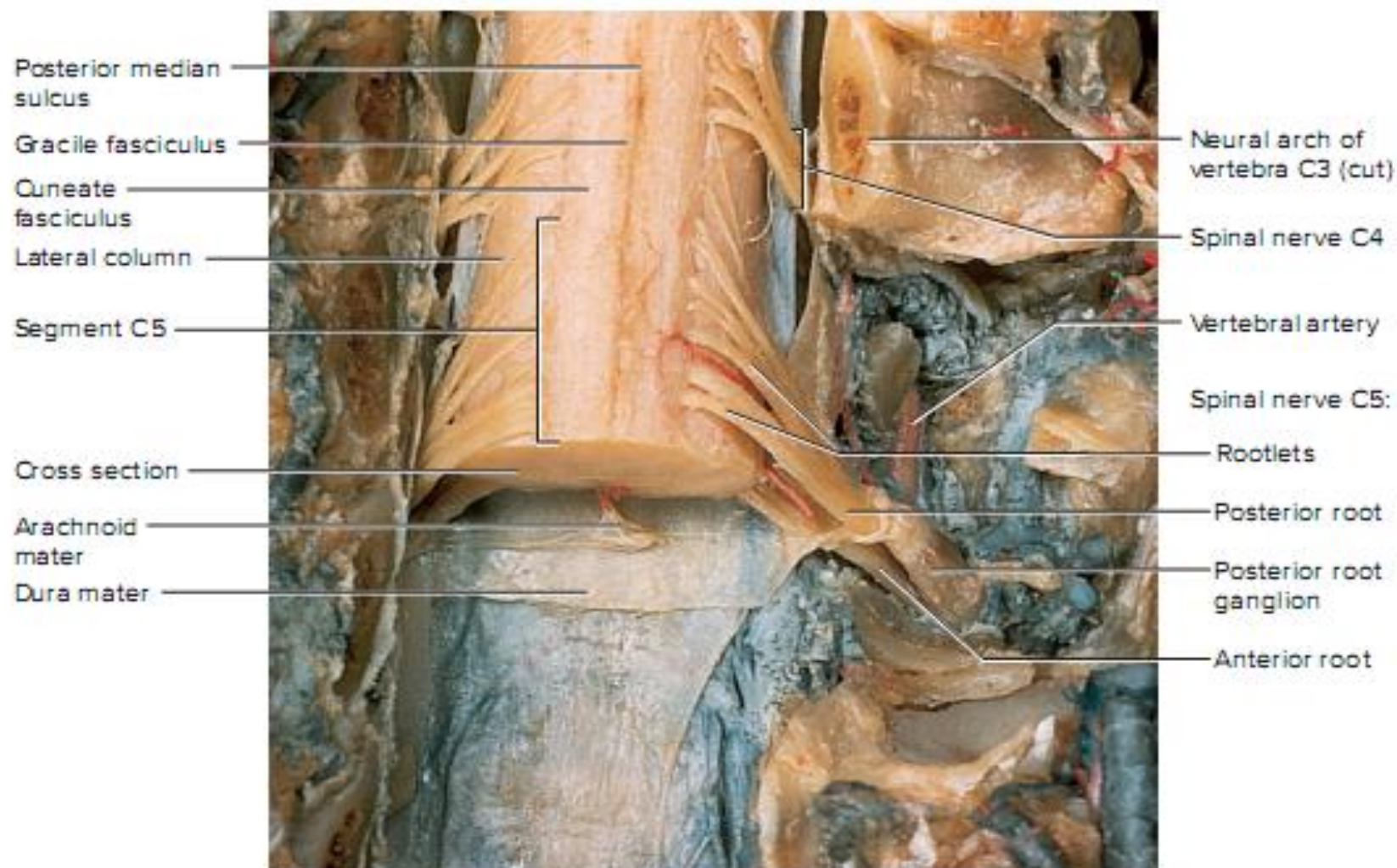

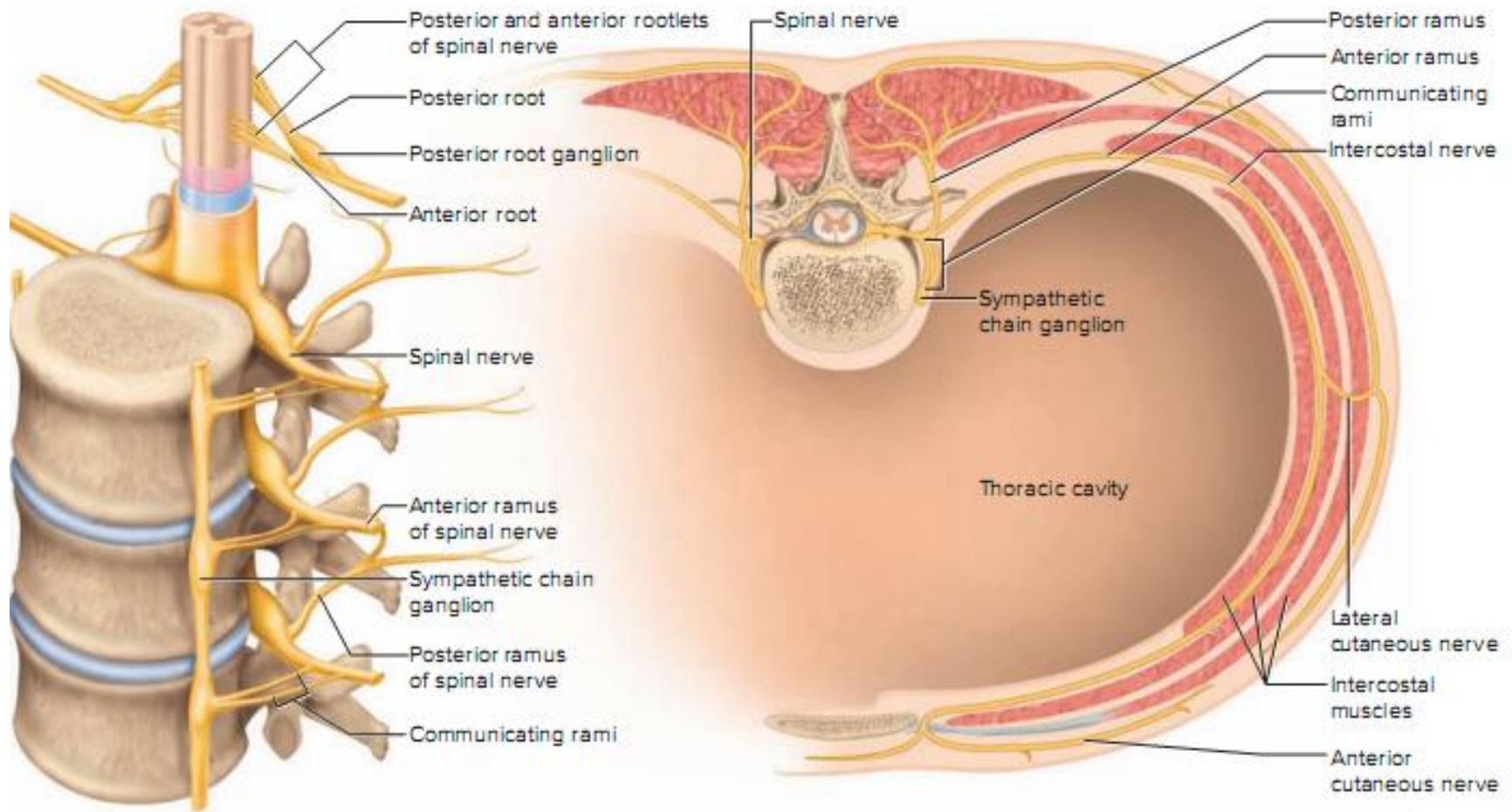
FIGURE 13.12 The Point of Entry of Two Spinal Nerves into the Spinal Cord. Posterior (dorsal) view with vertebrae cut away. Note that each posterior root divides into several rootlets that enter the spinal cord. A segment of the spinal cord is the portion receiving all the rootlets of one spinal nerve.

- Slightly distal to the ganglion, the *anterior and posterior roots merge*, leave the dural sheath, and *form the spinal nerve proper*.
 - The nerve then exits the vertebral canal through the intervertebral foramen.
- The spinal nerve is a mixed nerve,
 - carrying sensory signals to the spinal cord by way of the posterior root and ganglion,
 - and motor signals out to more distant parts of the body by way of the anterior root.
- The anterior and posterior roots are shortest in the cervical region and become longer inferiorly. The roots that arise from segments L2 to Co1 of the cord form the cauda equina. Some viruses invade the CNS by way of the spinal nerve roots.

3. Trace the branches of a spinal nerve distal to its attachments

Distal Branches

- Distal to the vertebrae, the branches of a spinal nerve are more complex .
 - Immediately after emerging from the intervertebral foramen, the nerve divides into an anterior ramus, posterior ramus, and a small meningeal branch.
- Thus, each spinal nerve branches on both ends—into anterior and posterior roots approaching the spinal cord, and anterior and posterior rami leading away from the vertebral column.



a) Anterolateral view

(b) Cross section

FIGURE 13.13 Rami of the Spinal Nerves. (a) Anterolateral view of the spinal nerves and their subdivisions in relation to the spinal cord and vertebrae. (b) Cross section of the thorax showing innervation of muscles and skin of the chest and back. This section is cut through the intercostal muscles between two ribs.

- The *meningeal branch* reenters the vertebral canal and
 - *innervates the meninges, vertebrae, and spinal ligaments with sensory and motor fibers.*
- The *posterior ramus*
 - *innervates the muscles and joints in that region of the spine and the skin of the back.*
- The larger *anterior ramus*
 - *innervates the anterior and lateral skin and muscles of the trunk, and gives rise to nerves of the limbs.*

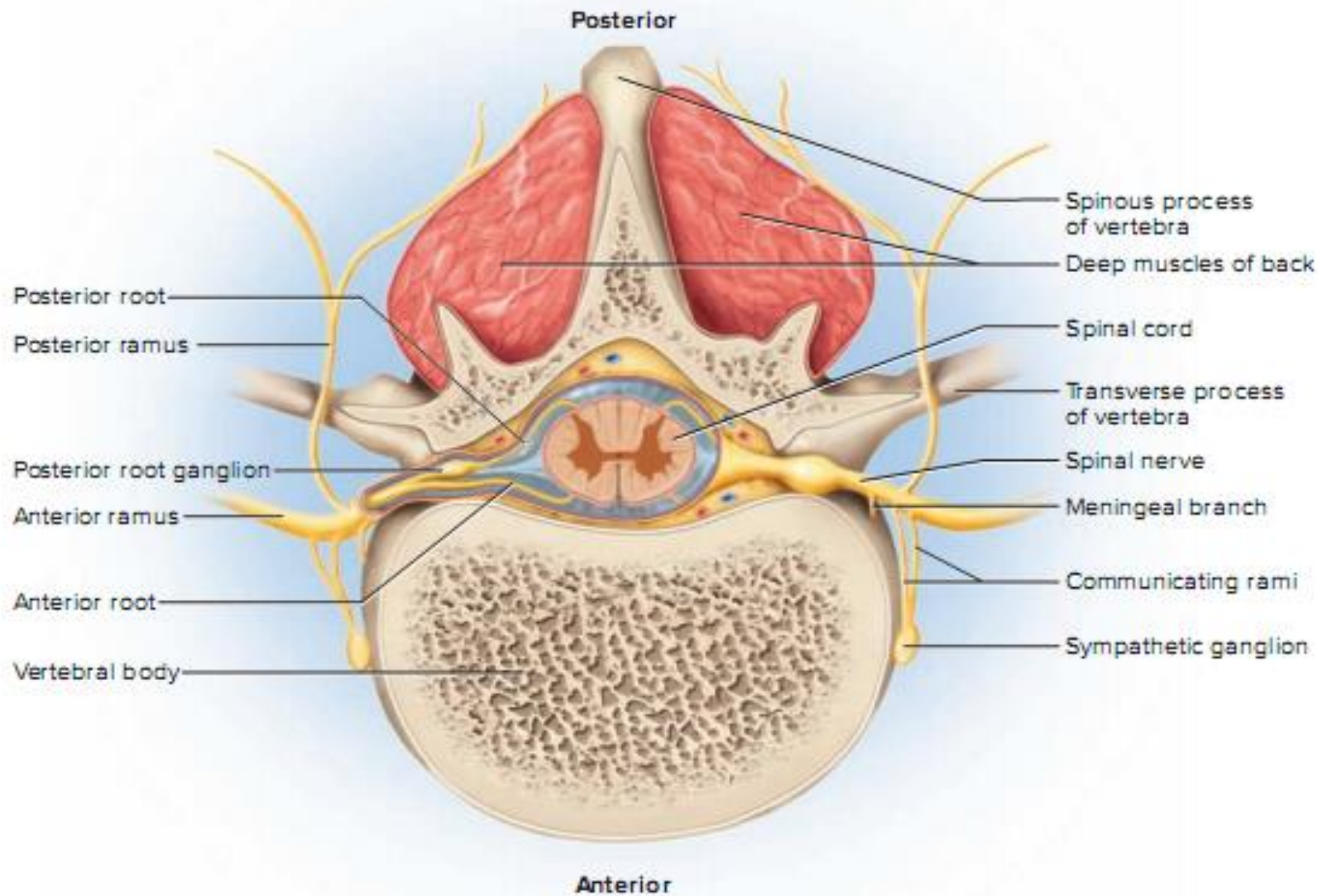


FIGURE 13.11 Branches of a Spinal Nerve in Relation to the Spinal Cord and Vertebra (Cross Section).

- The anterior ramus differs from one region of the trunk to another.
 - *In the thoracic region*, it forms an *intercostal nerve*, which travels along the inferior margin of a rib and innervates the skin and intercostal muscles (thus contributing to breathing).
 - Sensory fibers of the intercostal nerve branches to the skin are the most common routes of viral migration in the painful disease known as shingles.
 - Motor fibers of the intercostal nerves innervate the internal oblique, external oblique, and transverse abdominal muscles.
- **All other anterior rami form the nerve plexuses.**

- As shown in figure 13.13, the anterior ramus also gives off a pair of *communicating rami*,
 - which connect with a string of sympathetic chain ganglia alongside the vertebral column.
- **These are seen only in spinal nerves T1 through L2.** They are components of the sympathetic nervous system and are discussed more fully later.

4. Name the five plexus of spinal nerves and describe their general anatomy

- Except in the thoracic region, *the anterior rami branch and anastomose* (merge) repeatedly to form five webs called *nerve plexuses*:
 - the small cervical plexus in the neck,
 - the brachial plexus near the shoulder,
 - the lumbar plexus of the lower back,
 - the sacral plexus immediately inferior to this,
 - and finally, the tiny coccygeal plexus adjacent to the lower sacrum and coccyx.

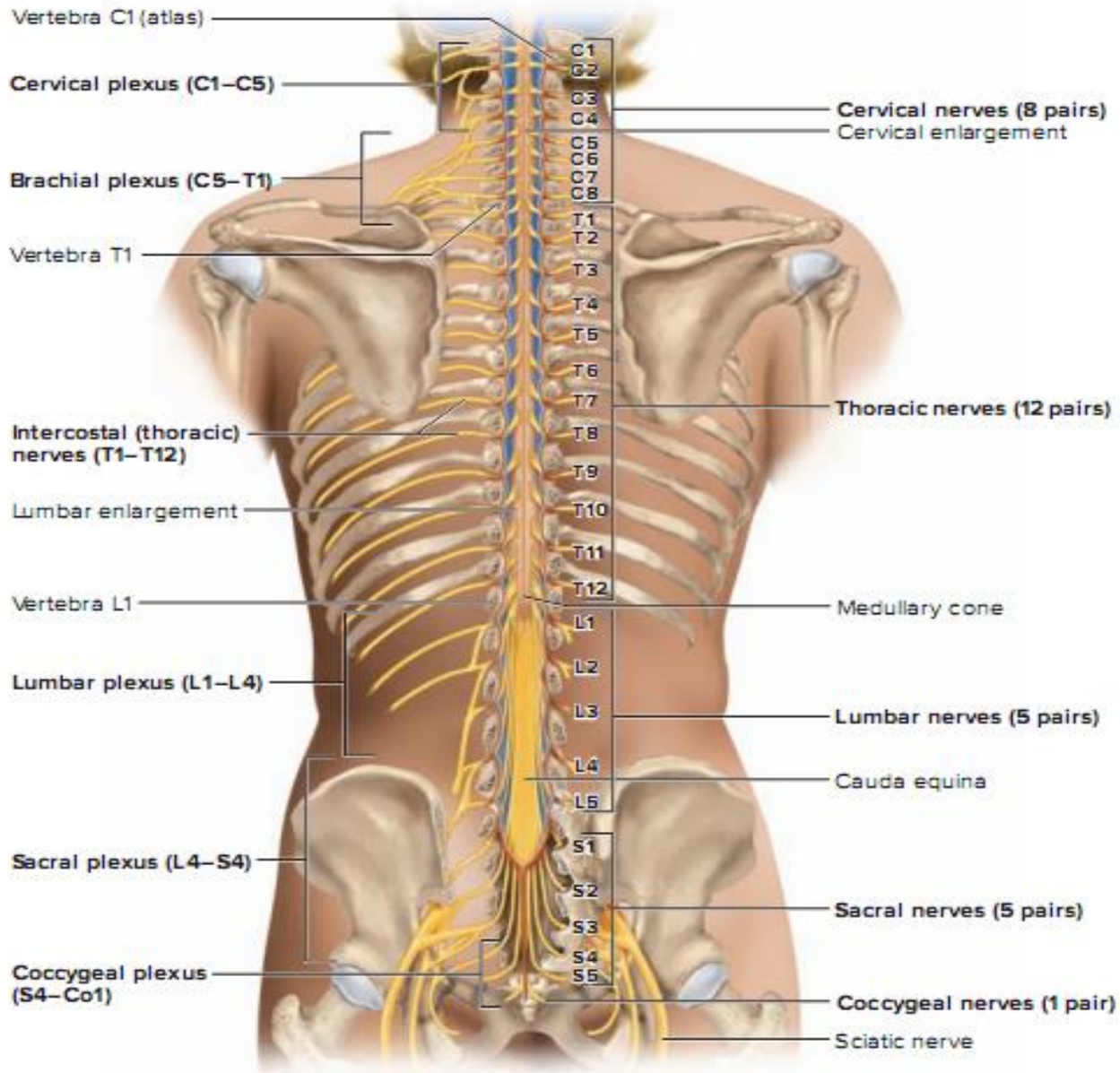


FIGURE 13.10 The Spinal Nerve Roots and Plexuses, Posterior View.

- The spinal nerve roots that give rise to each plexus are indicated in violet in each table (see below).
- Some of these roots give rise to smaller branches called *trunks, anterior divisions, posterior divisions, and cords*, which are color-coded and explained in the individual tables below.
- *Two of the nerves arising from these plexuses, the radial and sciatic, are sites of unique nerve injuries described.*

- The nerves tabulated here have *somatosensory and motor functions*.
 - *Somatosensory* means that they carry sensory signals from bones, joints, muscles, and the skin, in contrast to sensory input from the viscera or from special sense organs such as the eyes and ears.
 - *Somatosensory* signals are for touch, heat, cold, stretch, pressure, pain, and other sensations.
- One of the most important sensory roles of these nerves is *proprioception*, in which the brain receives *information about body position and movements* from nerve endings in the muscles, tendons, and joints.
 - The brain uses this information to adjust muscle actions and thereby maintain equilibrium (balance) and coordination.

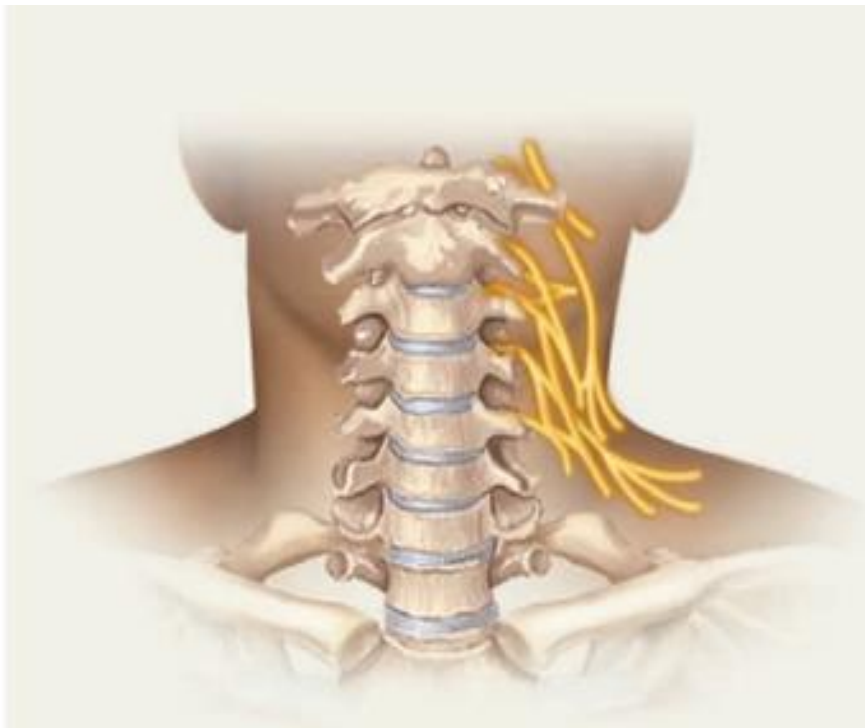
- *The motor function of these nerves is primarily to stimulate the contraction of skeletal muscles.*
 - They also innervate the bones of the corresponding regions,
 - and carry autonomic fibers to some viscera and blood vessels, thus adjusting blood flow to local needs.


5. Name the some major nerves that arise from each plexus

TABLE 13.3 The Cervical Plexus

The cervical plexus (fig. 13.14) receives fibers from the anterior rami of nerves C1 to C5 and gives rise to the nerves listed below, in order from superior to inferior. The most important of these are the *phrenic*²² nerves (FREN-ic), which travel down each side of the mediastinum, innervate the diaphragm, and play an essential role in breathing (see fig. 15.3). In addition to the major nerves listed here, there are several motor branches that innervate the geniohyoid, thyrohyoid, scalene, levator scapulae, trapezius, and sternocleidomastoid muscles.

Nerve	Composition	Cutaneous and Other Sensory Innervation	Muscular Innervation (Motor and Proprioceptive)
Lesser occipital n.	Somatosensory	Upper third of medial surface of external ear, skin posterior to ear, posterolateral neck	None
Great auricular n.	Somatosensory	Most of the external ear, mastoid region, region from parotid salivary gland (see fig. 10.6) to slightly inferior to angle of mandible	None
Transverse cervical n.	Somatosensory	Anterior and lateral neck, underside of chin	None
Ansa cervicalis	Motor	None	Omoxyoid, sternohyoid, and sternothyroid muscles
Supraclavicular nn.	Somatosensory	Lower anterior and lateral neck, shoulder, anterior chest	None
Phrenic n.	Mixed	Diaphragm, pleura, and pericardium	Diaphragm



 Roots

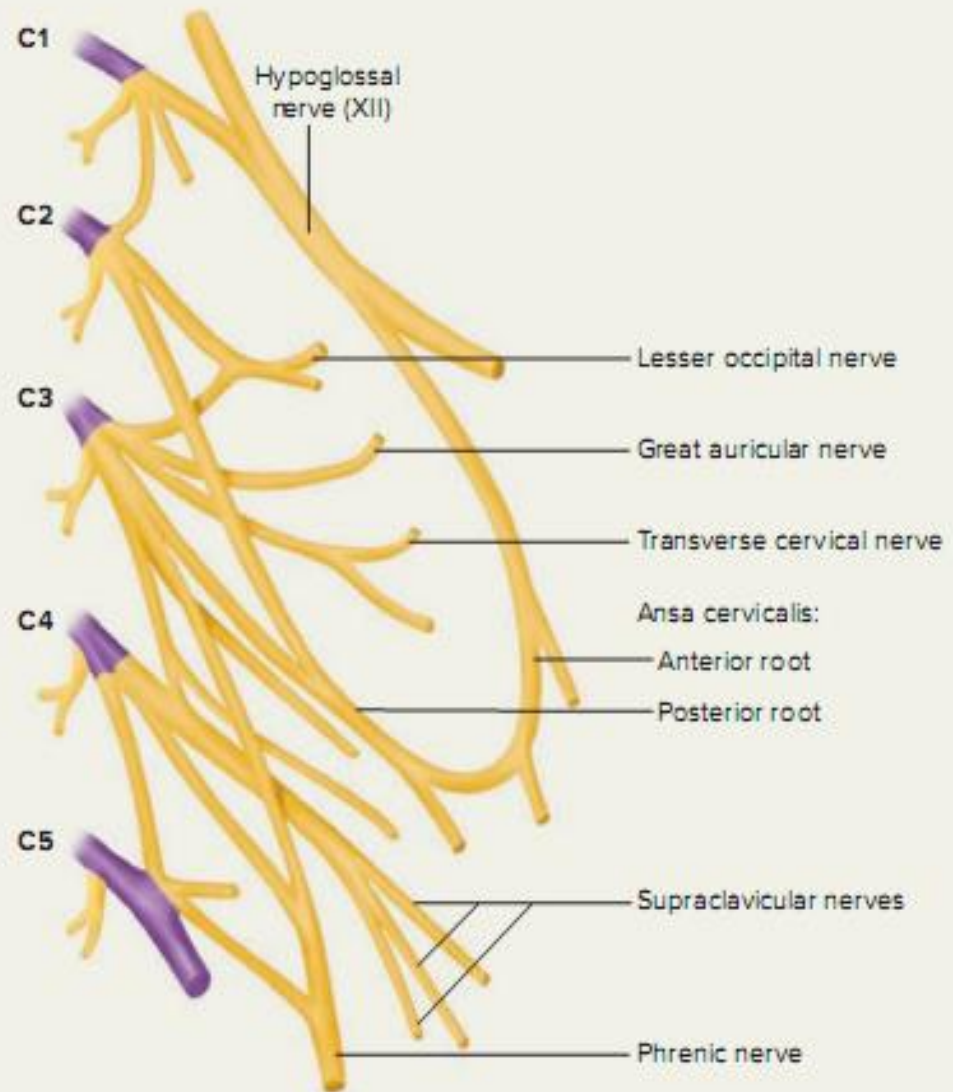


FIGURE 13.14 The Cervical Plexus. **AP|R**

TABLE 13.4**The Brachial Plexus**

The brachial plexus (figs. 13.15 and 13.16) is formed predominantly by the anterior rami of nerves C5 to T1 (C4 and T2 make small contributions). It passes over the first rib into the axilla and innervates the upper limb and some muscles of the neck and shoulder. This plexus is well known for its conspicuous M or W shape seen in cadaver dissections. The subdivisions of this plexus are called *roots*, *trunks*, *divisions*, and *cords* (color-coded in fig. 13.15). The five **roots** are the anterior rami of C5 through T1. Roots C5 and C6 converge to form the **upper trunk**; C7 continues as the **middle trunk**; and C8 and T1 converge to form the **lower trunk**. Each trunk divides into an **anterior** and **posterior division**. As the body is dissected from the anterior surface of the shoulder inward, the posterior divisions are found behind the anterior ones. Finally, the six divisions merge to form three large fiber bundles—the **lateral**, **posterior**, and **medial cords**. From these cords arise the following major nerves, listed in order of the illustration from superior to inferior.

Nerve	Composition	Cord of Origin	Cutaneous and Joint Innervation (Sensory)	Muscular Innervation (Motor and Proprioceptive)
Musculocutaneous n.	Mixed	Lateral	Skin of anterolateral forearm; elbow joint	Brachialis, biceps brachii, and coracobrachialis muscles
Axillary n.	Mixed	Posterior	Skin of lateral shoulder and arm; shoulder joint	Deltoid and teres minor muscles
Radial n.	Mixed	Posterior	Skin of posterior arm; posterior and lateral forearm and wrist; joints of elbow, wrist, and hand	Mainly extensor muscles of posterior arm and forearm (see tables 10.10 and 10.11)
Median n.	Mixed	Lateral and medial	Skin of lateral two-thirds of hand; tips of digits I–IV; joints of hand	Mainly forearm flexors; thenar group and lumbricals I–II of hand (see tables 10.10 to 10.12)
Ulnar n.	Mixed	Medial	Skin of palmar and medial hand and digits III–V; joints of elbow and hand	Some forearm flexors; adductor pollicis; hypothenar group; inter-osseous muscles; lumbricals III–IV (see tables 10.11 and 10.12)

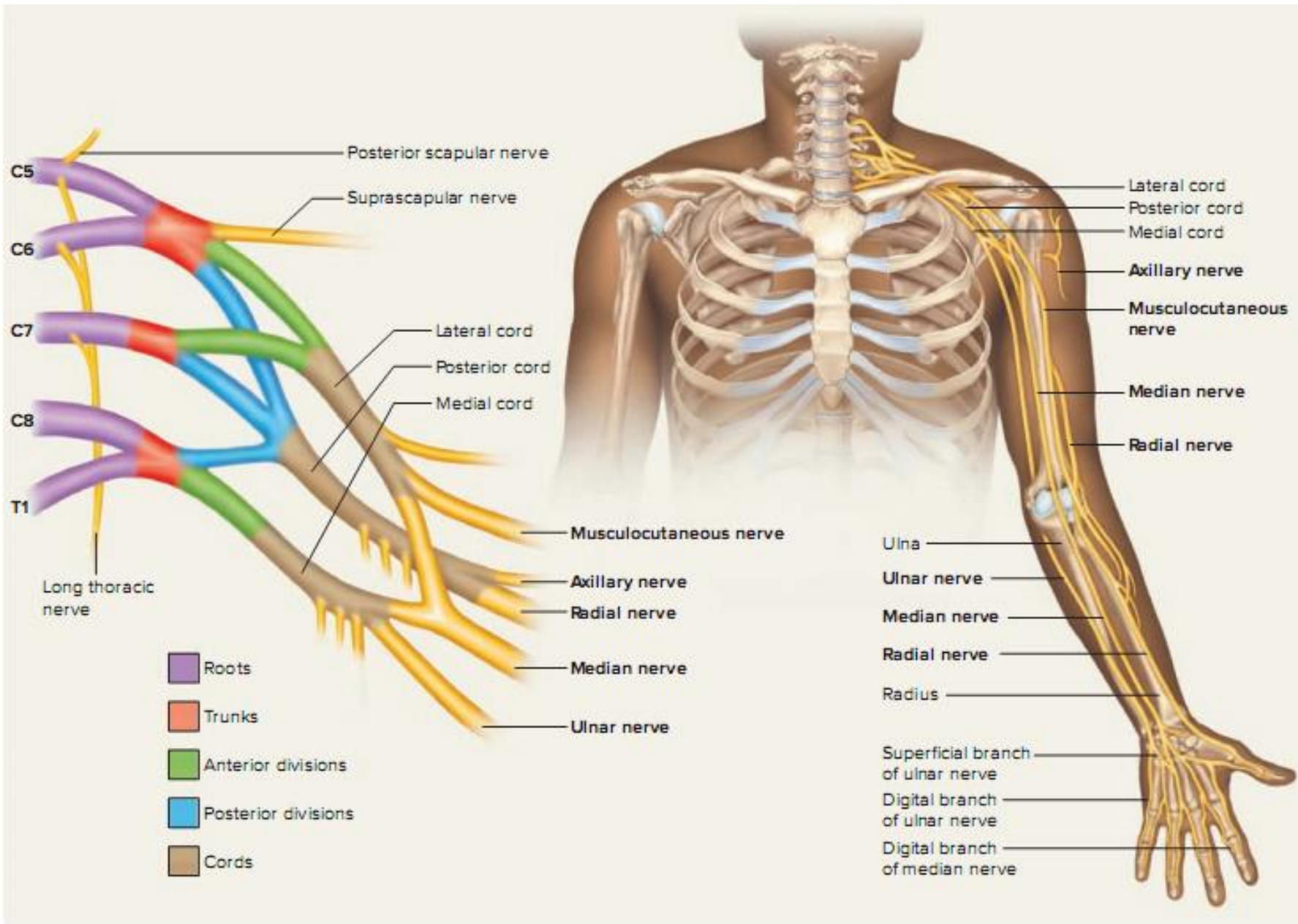


TABLE 13.4

The Brachial Plexus (continued)

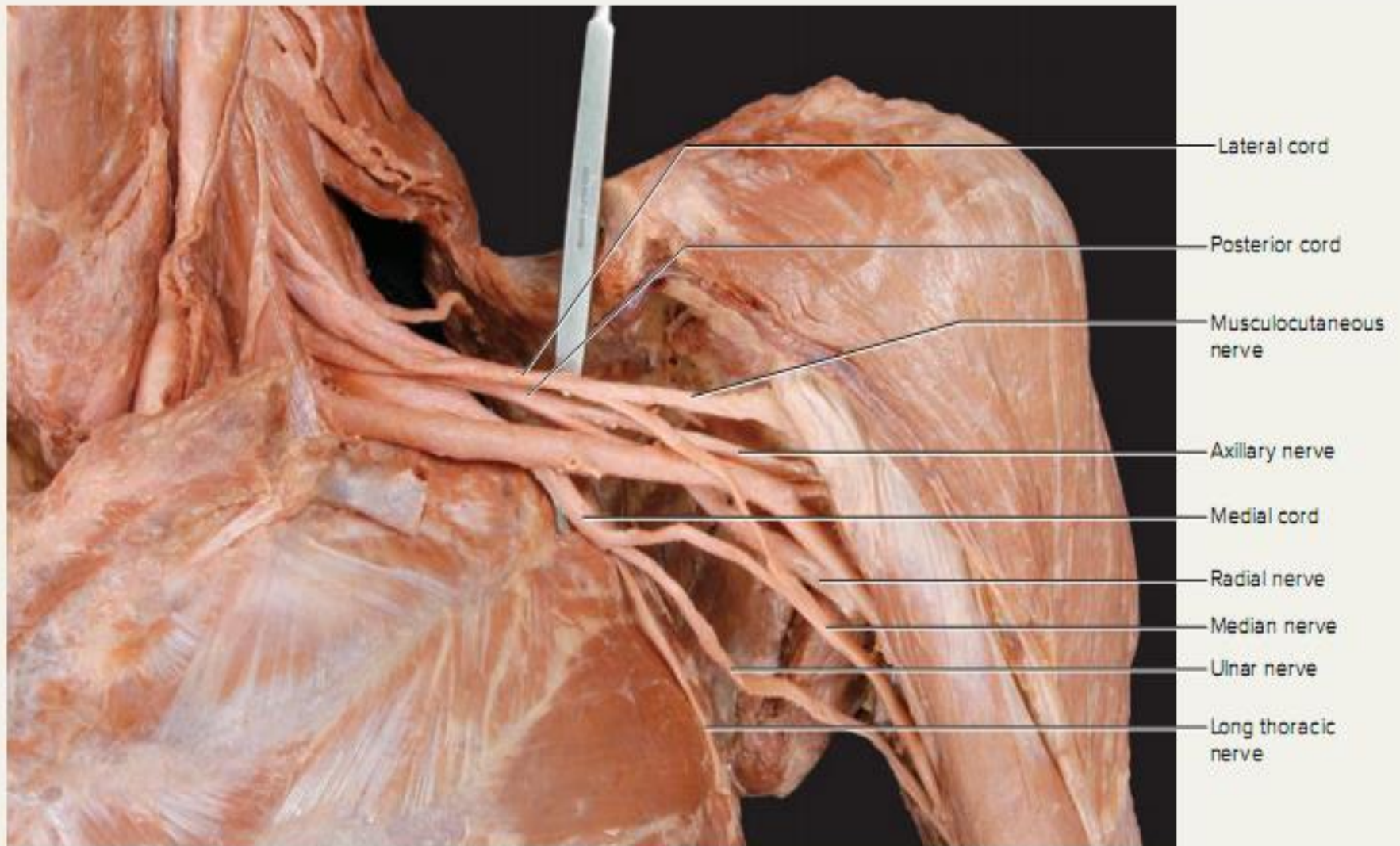
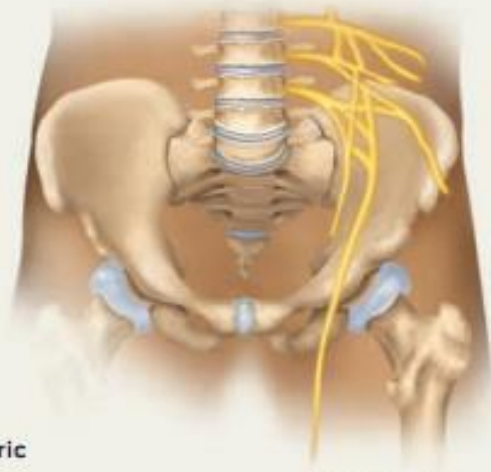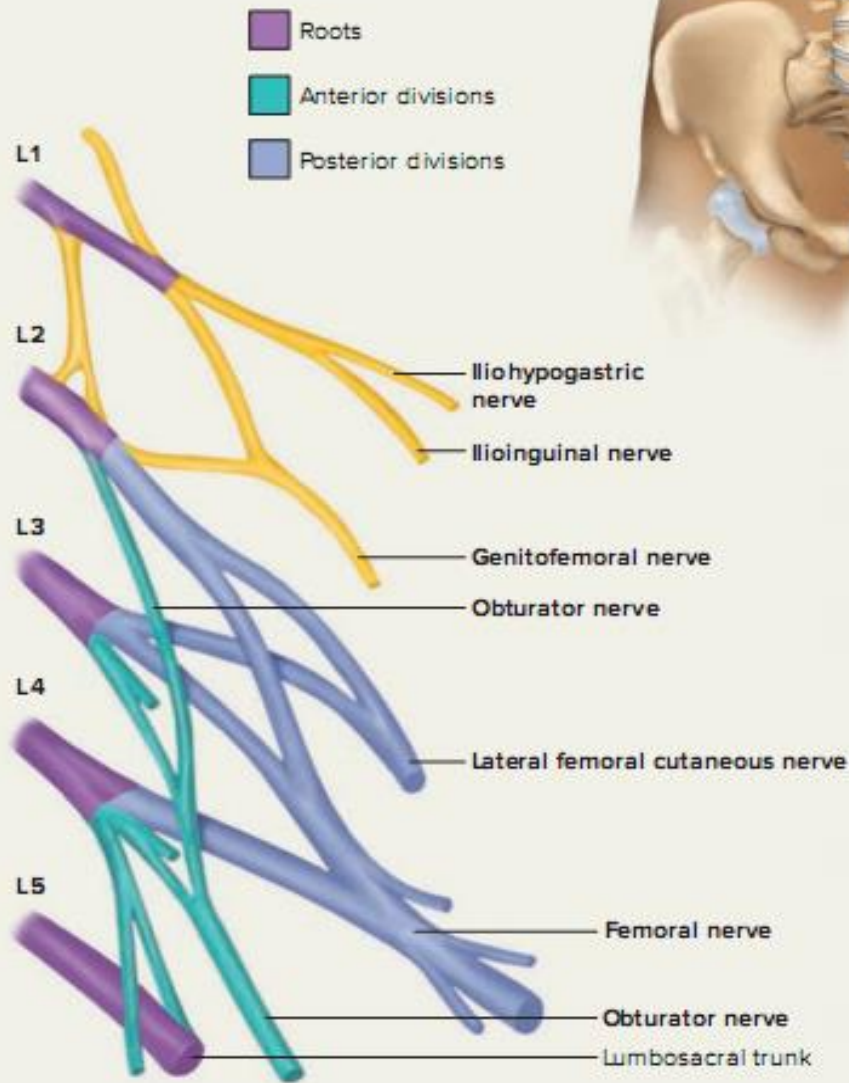


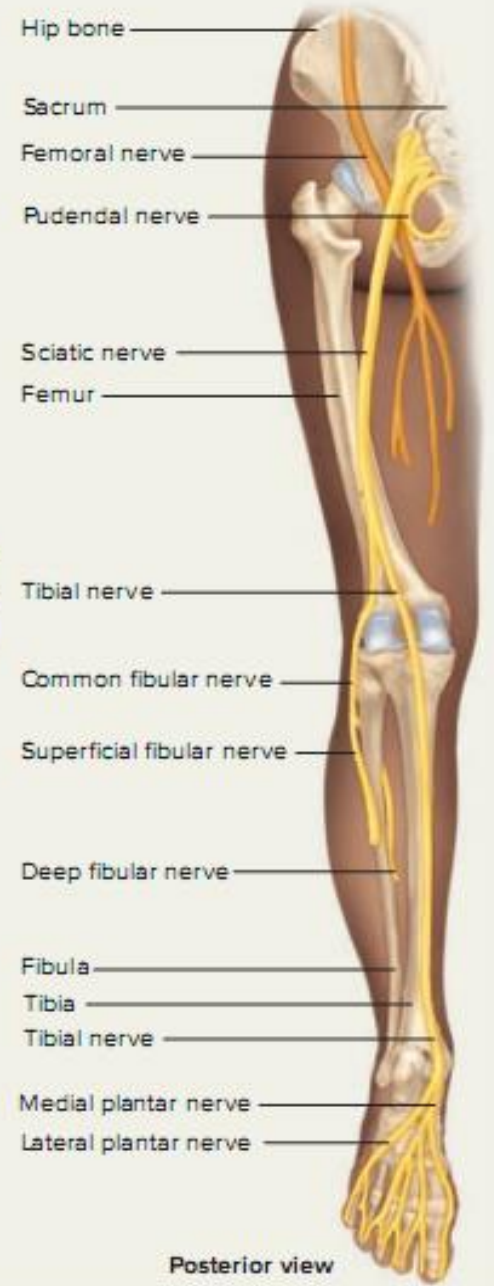
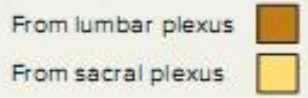
TABLE 13.5**The Lumbar Plexus**

The lumbar plexus (fig. 13.17) is formed from the anterior rami of nerves L1 to L4 and some fibers from T12. With only five roots and two divisions, it is less complex than the brachial plexus. It gives rise to the following nerves.

Nerve	Composition	Cutaneous and Joint Innervation (Sensory)	Muscular Innervation (Motor and Proprioceptive)
Iliohypogastric n.	Mixed	Skin of lower anterior abdominal and posterolateral gluteal regions	Internal and external abdominal oblique and transverse abdominal muscles
Ilioinguinal n.	Mixed	Skin of upper medial thigh; male scrotum and root of penis; female labia majora	Internal abdominal oblique
Genitofemoral n.	Mixed	Skin of middle anterior thigh; male scrotum; female labia majora	Male cremaster muscle (see fig. 27.7)
Lateral femoral cutaneous n.	Somatosensory	Skin of anterior and upper lateral thigh	None
Femoral n.	Mixed	Skin of anterior, medial, and lateral thigh and knee; skin of medial leg and foot; hip and knee joints	Iliacus, pectineus, quadriceps femoris, and sartorius muscles
Obturator n.	Mixed	Skin of medial thigh; hip and knee joints	Obturator externus; medial (adductor) thigh muscles (see table 10.13)



Anterior view



Posterior view

FIGURE 13.17 The Lumbar Plexus. **AP|R**

TABLE 13.6**The Sacral and Coccygeal Plexuses**

The sacral plexus is formed from the anterior rami of nerves L4, L5, and S1 through S4. It has six roots and anterior and posterior divisions. Since it is connected to the lumbar plexus by fibers that run through the *lumbosacral trunk*, the two plexuses are sometimes referred to collectively as the *lumbosacral plexus*. The coccygeal plexus is a tiny plexus formed from the anterior rami of S4, S5, and Co1 (fig. 13.18).

The *tibial* and *common fibular nerves* travel together through a connective tissue sheath; they are referred to collectively as the sciatic nerve (*sy-AT-ic*). The sciatic nerve passes through the greater sciatic notch of the pelvis, extends for the length of the thigh, and ends at the popliteal fossa. Here, the tibial and common fibular nerves diverge and follow their separate paths into the leg. The tibial nerve descends through the leg and then gives rise to the medial and plantar nerves in the foot. The common fibular nerve divides into deep and superficial fibular nerves. The sciatic nerve is a common focus of injury and pain (see Deeper Insight 13.4).

Nerve	Composition	Cutaneous and Joint Innervation (Sensory)	Muscular Innervation (Motor and Proprioceptive)
Superior gluteal n.	Mixed	Hip joint	Gluteus minimus, gluteus medius, and tensor fasciae latae muscles
Inferior gluteal n.	Mixed	None	Gluteus maximus muscle
Posterior cutaneous n.	Somatosensory	Skin of gluteal region, perineum, posterior and medial thigh, popliteal fossa, and upper posterior leg	None
Tibial n.	Mixed	Skin of posterior leg; plantar skin; knee and foot joints	Hamstring muscles; posterior muscles of leg (see tables 10.14 and 10.15); most intrinsic foot muscles (via plantar nerves) (see table 10.16)
Fibular (peroneal) nn. (common, deep, and superficial)	Mixed	Skin of anterior distal third of leg, dorsum of foot, and toes I–II; knee joint	Biceps femoris muscle; anterior and lateral muscles of leg; extensor digitorum brevis muscle of foot (see tables 10.14 to 10.16)
Pudendal n.	Mixed	Skin of penis and scrotum of male; clitoris, labia majora and minora, and lower vagina of female	Muscles of perineum (see table 10.7)

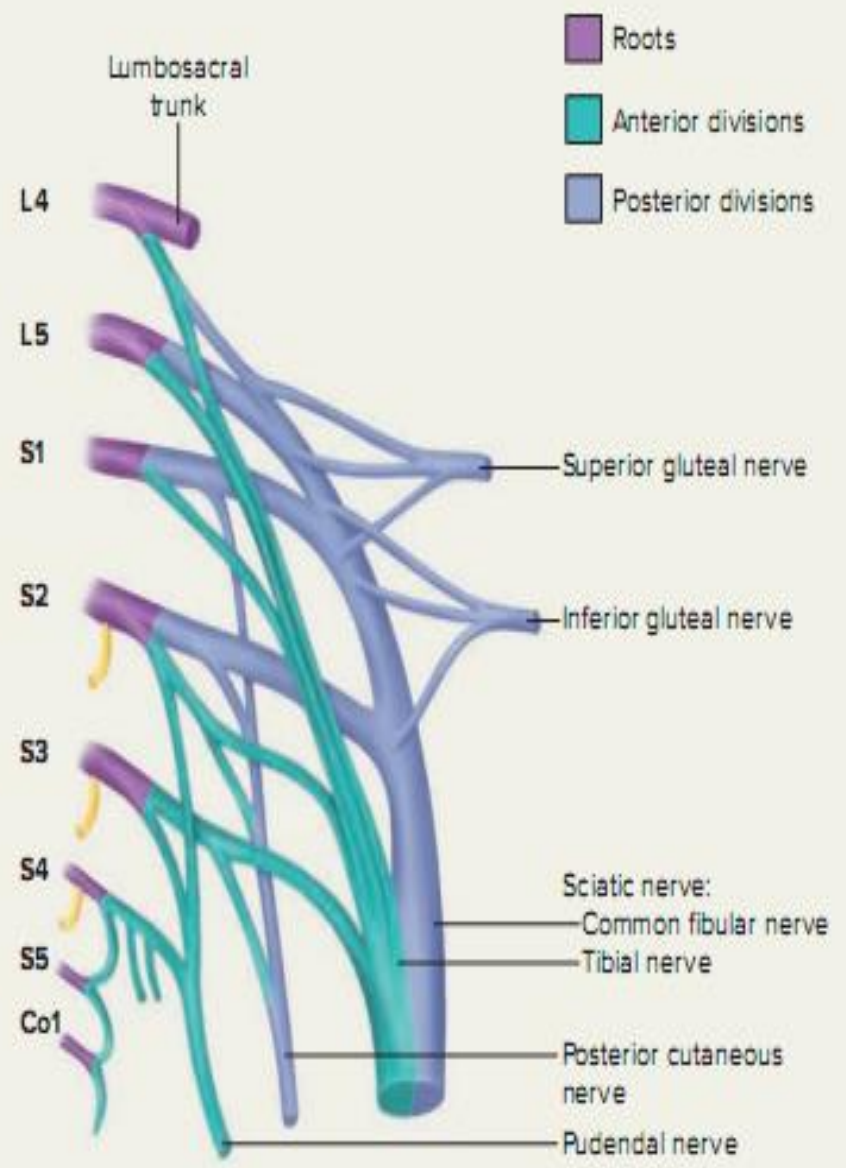
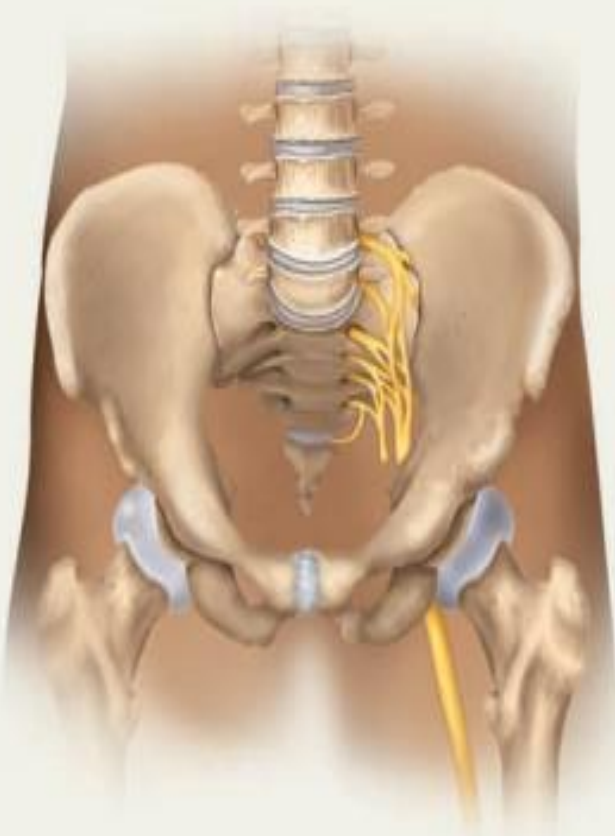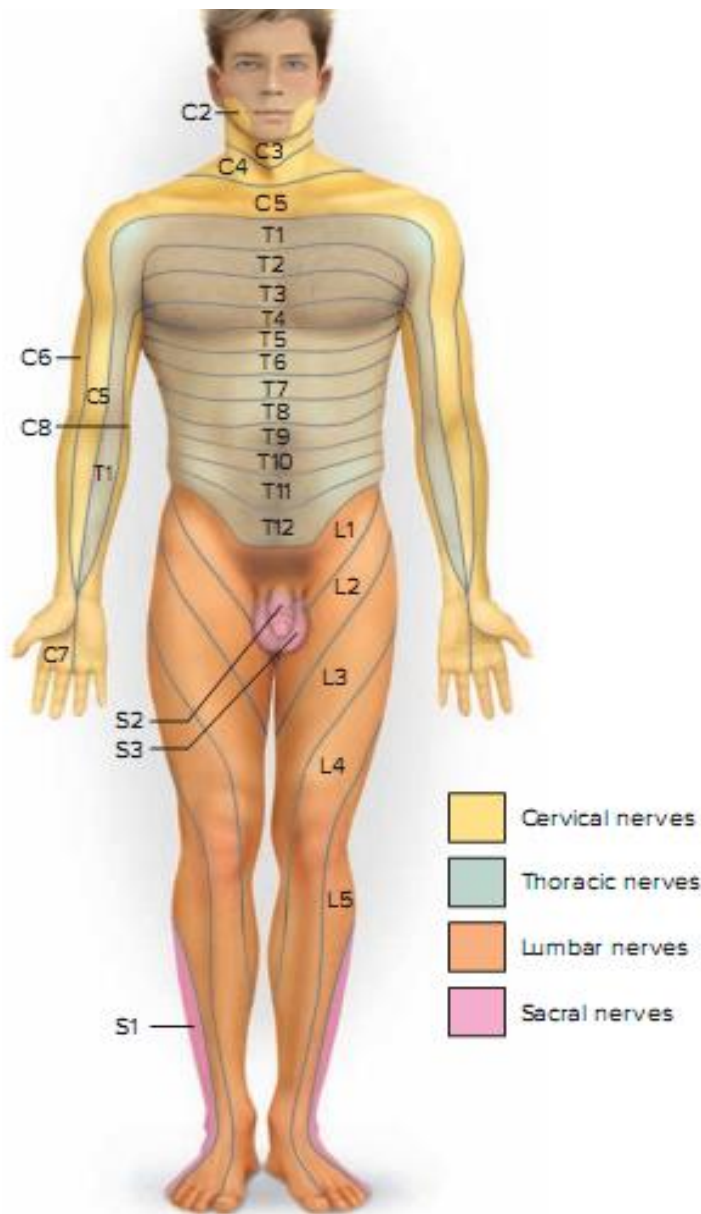


FIGURE 13.18 The Sacral and Coccygeal Plexuses. **AP|R**

6. Explain the relationship of dermatomes to the spinal nerve

- Each spinal nerve except C1 receives sensory input from a specific area of skin called a dermatome.
 - A *dermatome map* is a diagram of the cutaneous regions innervated by each spinal nerve. Such a map is oversimplified, however, because the dermatomes overlap at their edges by as much as 50%.
- Therefore, severance of one sensory nerve root does not entirely deaden sensation from a dermatome.
 - It is necessary to sever or anesthetize three sequential spinal nerves to produce a total loss of sensation from one dermatome.
- Spinal nerve damage is assessed by testing the dermatomes with pinpricks and noting areas in which the patient has no sensation.

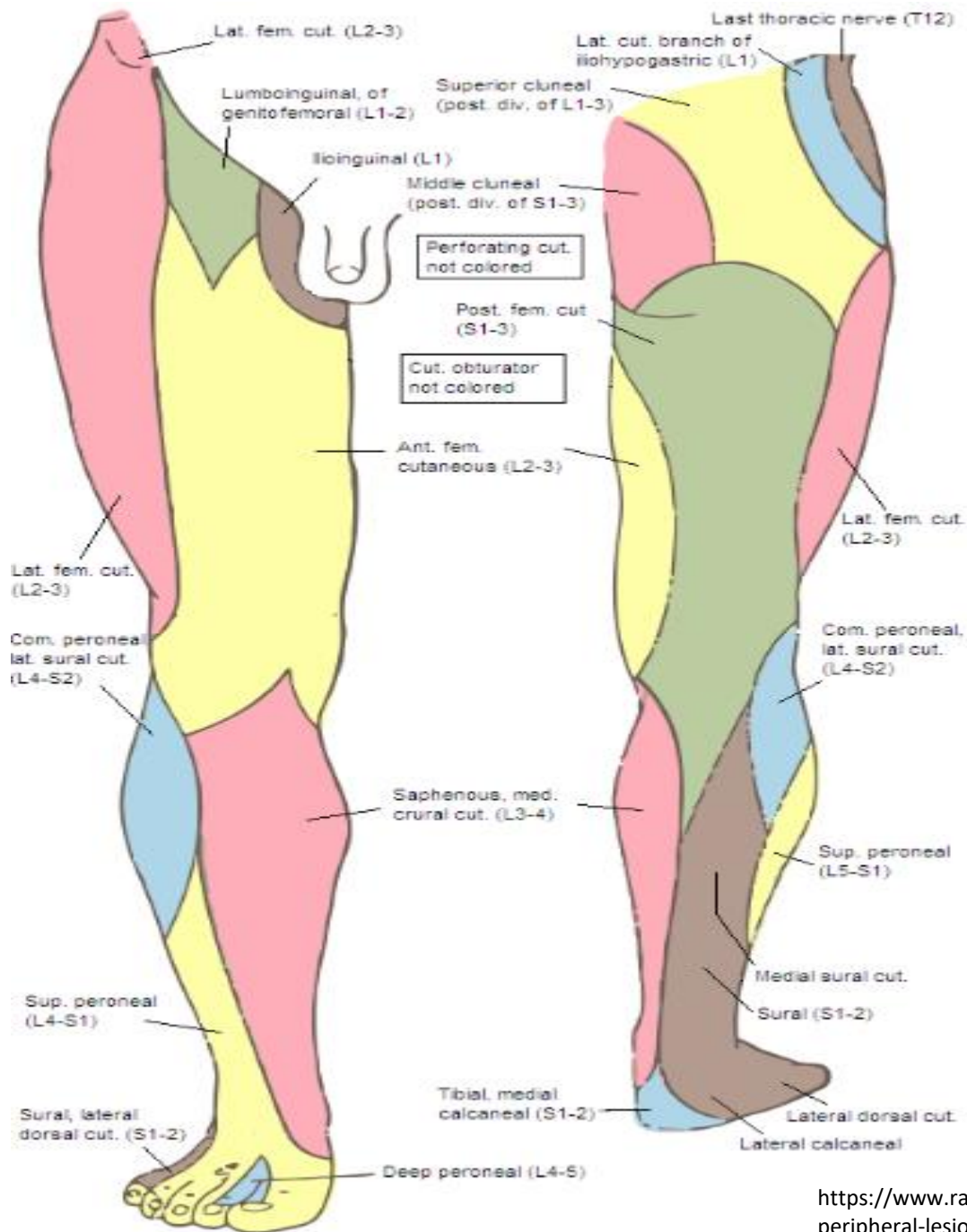


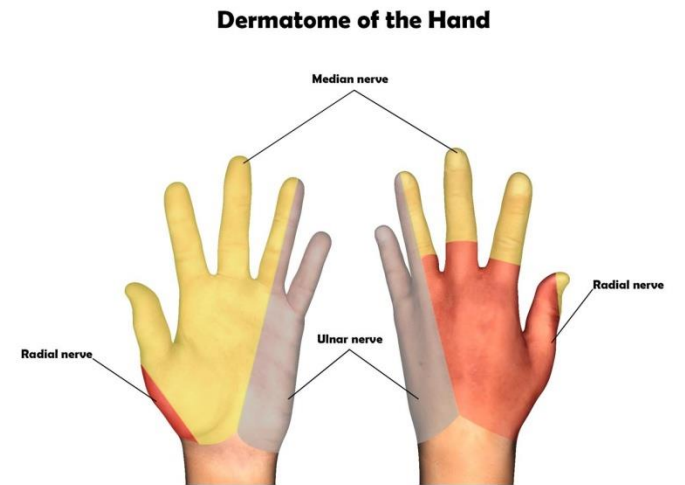
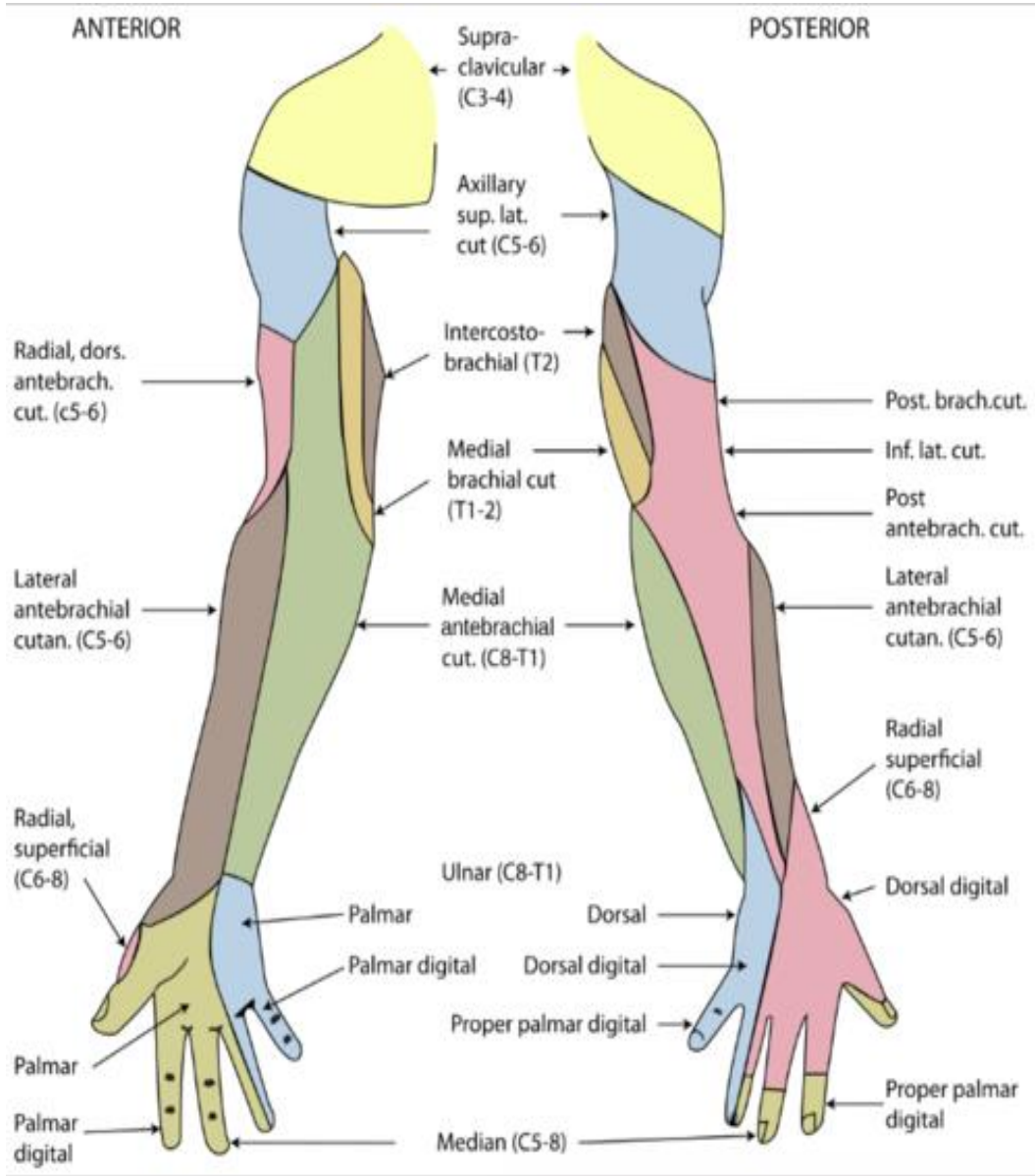
Dermatomes are a defined area of skin to which the sensory component of a spinal nerve is distributed to a specific spinal cord segment.

All dermatomes from the shoulders down relay their sensory information back to the CNS through spinal nerves.

Myotomes are similar in function to *dermatomes*, but carry motor stimuli. They are responsible for segmental innervation of skeletal muscle. For example the *diaphragm muscle*, which is innervated by the C3, C4, and C5 spinal nerves; collectively they form the phrenic nerve.

FIGURE 13.19 A Dermatome Map of the Anterior Aspect of the Body. Each zone of the skin is innervated by sensory branches of the spinal nerves indicated by the labels. Nerve C1 does not innervate the skin.

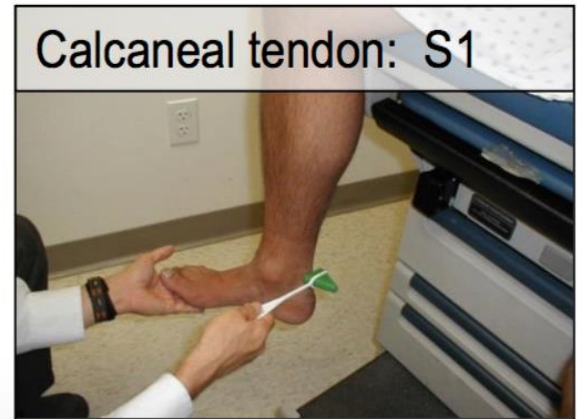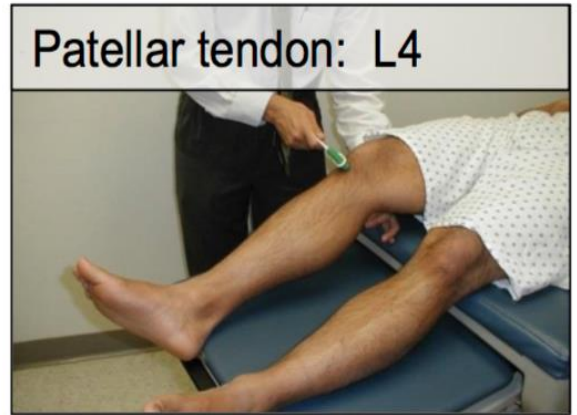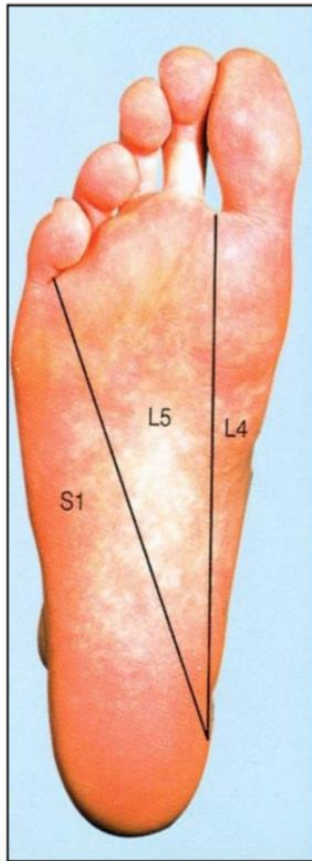
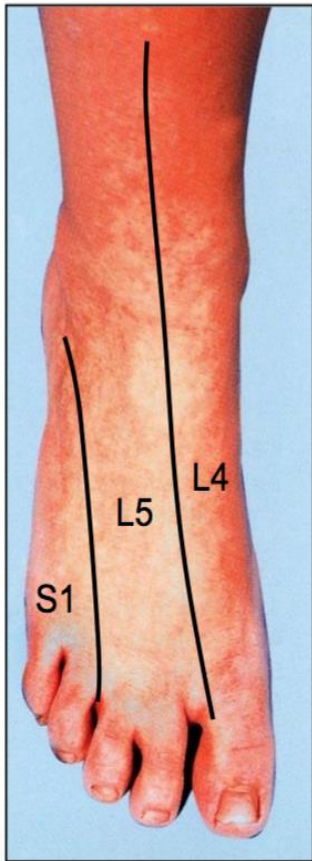
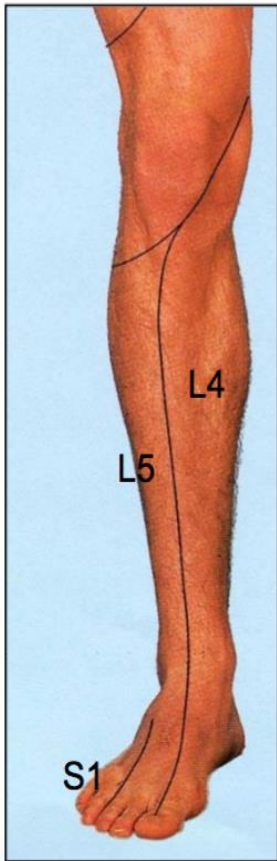




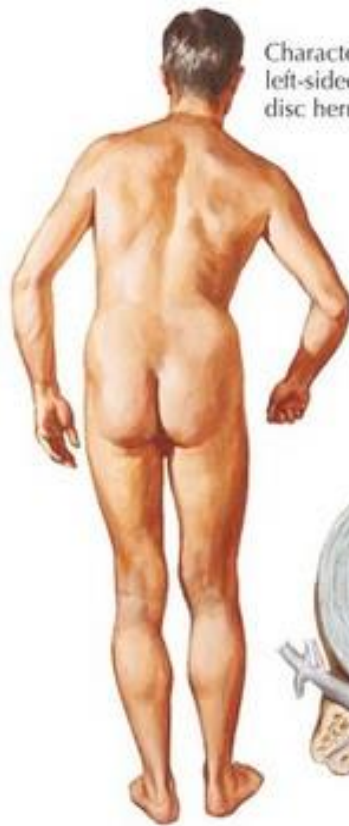© Lineage

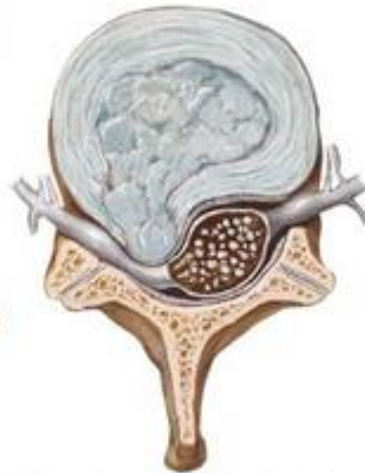3D BIO MED SPACE

IV disc	Roots affected	Dermatome Testing	Deep Tendon Reflex
L3/L4	L4	Medial leg & medial foot	Patellar tendon
L4/L5	L5	Lateral leg, dorsal foot	NONE
L5/S1	S1	Lateral foot	Calcaneal ("Achilles") tendon





Characteristic posture in left-sided lower lumbar disc herniation



Schematic cross section showing compression of nerve root

F. Netter M.D.

Clinical features of herniated lumbar nucleus pulposus					
Level of herniation	Pain	Numbness	Weakness	Atrophy	Reflexes
<p>L4-5 disc; 5th lumbar nerve root</p>	<p>Over sacroiliac joint, hip, lateral thigh and leg</p>	<p>Lateral leg, first 3 toes</p>	<p>Dorsiflexion of great toe and foot; difficulty walking on heels; foot drop may occur</p>	Minor	Changes uncommon in knee and ankle jerks, but internal hamstring reflex diminished or absent
<p>L5-S1 disc; 1st sacral nerve root</p>	<p>Over sacroiliac joint, hip, posterolateral thigh and leg to heel</p>	<p>Back of calf, lateral heel, foot to toe</p>	<p>Plantar flexion of foot and great toe may be affected; difficulty walking on toes</p>	Gastrocnemius and soleus	Ankle jerk diminished or absent

- Sportsmen often have such symptoms (herniations – rare, protrusions more often)



**Al-Farabi
Kazakh
National
University
Higher School
of Medicine**

The Forebrain

Expected Learning Outcomes

- a. name the three major components of the diencephalon and describe their locations and functions;
- b. identify the five lobes of the cerebrum and their functions;
- c. describe the three types of tracts in the cerebral white matter;
- d. describe the distinctive cell types and histological arrangement of the cerebral cortex; and
- e. describe the location and functions of the basal nuclei and limbic system.

The forebrain consists of

diencephalon

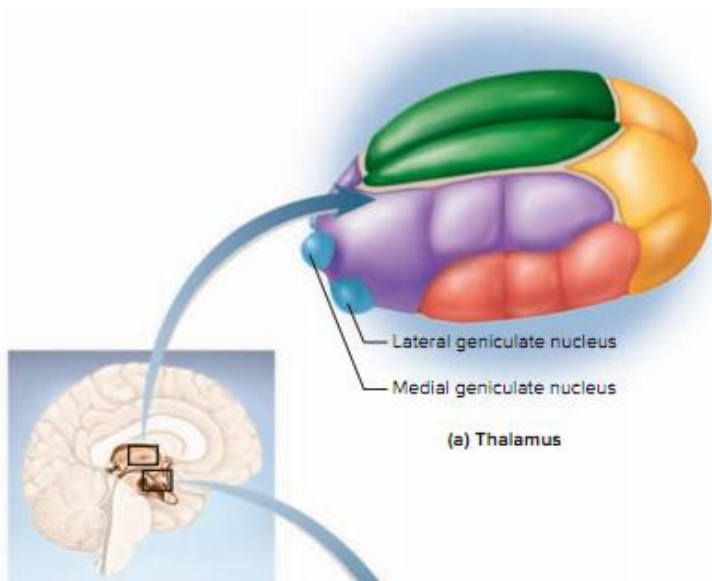
- encloses the third ventricle and is the most rostral part of the brainstem

telencephalon

- develops chiefly into the cerebrum

Three structures arise from the embryonic diencephalon: the thalamus, hypothalamus, and epithalamus.

The thalamus



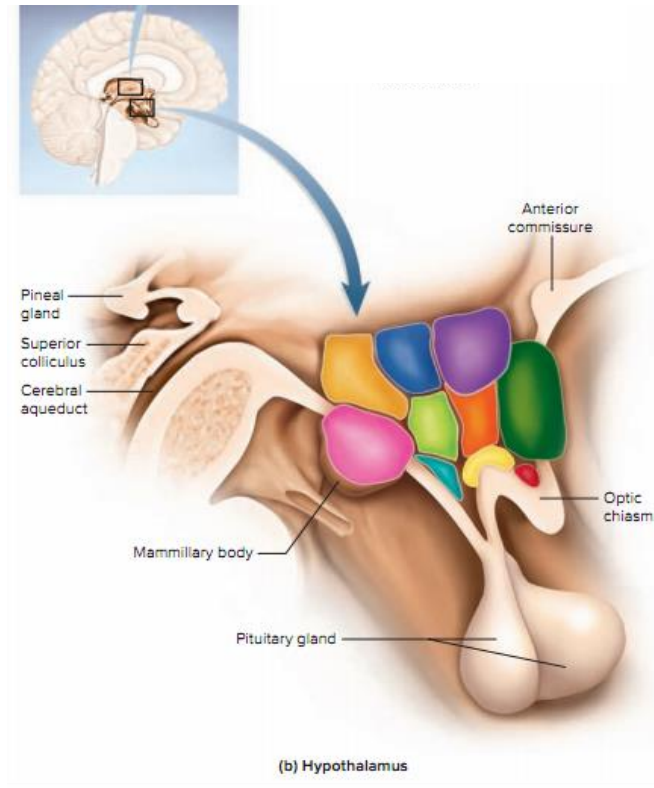
Each side of the brain has a thalamus. **Laterally**, they protrude into the lateral ventricles. **Medially**, they protrude into the third ventricle and are joined in about 70% of people.

The thalamus consists of at least 23 nuclei, most of which fall into five groups: anterior, posterior, medial, lateral, and ventral.

The thalamic nuclei process and relay a small portion of information to the cerebral cortex.

The thalamus also relays signals from the cerebellum to the cerebrum and provides feedback loops between the cerebral cortex and the basal nuclei. The thalamus is involved in the memory and emotional functions of the limbic system.

The Hypothalamus



The hypothalamus forms the floor and part of the walls of the third ventricle. It extends anteriorly to the optic chiasm, and posteriorly to the mammillary bodies. The pituitary gland is attached to the hypothalamus by a stalk (infundibulum) between the optic chiasm and mammillary bodies.

The hypothalamus is the major control center of the endocrine and autonomic nervous systems. It plays an essential role in the homeostatic regulation of nearly all organs of the body.

Hormone secretion

The hypothalamus controls the anterior pituitary gland (growth, metabolism, reproduction, and stress responses). And the posterior pituitary gland (labor contractions, lactation, and water conservation).

Autonomic effects

- It influences HR, BP, GI secretion and motility, and pupillary diameter, etc.

Thermoregulation

- The hypothalamus monitors body temperature

Food and water intake

The hypothalamus regulates sensations of hunger and satiety. Hypothalamic neurons called osmoreceptors monitor blood osmolarity and stimulate water-seeking and drinking behavior when the body is dehydrated.

circadian rhythms

It regulates the rhythm of sleep and waking, controls our 24-hour (circadian) rhythm of activity.






Memory

- The mammillary nuclei lie in the pathway of signals traveling from the hippocampus, an important memory center of the brain, to the thalamus.











.. Emotional behavior

- Hypothalamic centers are involved in a variety of emotional responses including anger, aggression, fear, pleasure, etc.

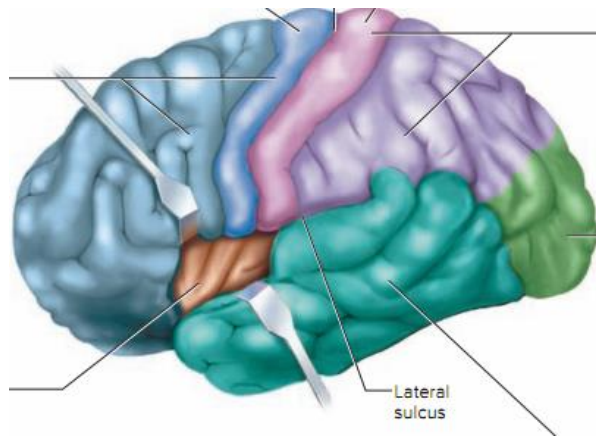
Thalamic Nuclei

	Anterior group	Part of limbic system; memory and emotion
	Medial group	Emotional output to prefrontal cortex; awareness of emotions
	Ventral group	Somesthetic output to postcentral gyrus; signals from cerebellum and basal nuclei to motor areas of cortex
	Lateral group	Somesthetic output to association areas of cortex; contributes to emotional function of limbic system
	Posterior group	Relay of visual signals to occipital lobe (via lateral geniculate nucleus) and auditory signals to temporal lobe (via medial geniculate nucleus)

Hypothalamic Nuclei

	Anterior nucleus	Thirst; thermoregulation
	Arcuate nucleus	Regulates appetite: secretes releasing hormones that regulate anterior pituitary
	Dorsomedial nucleus	Rage and other emotions
	Mammillary nuclei	Relay between limbic system and thalamus; involved in long-term memory
	Paraventricular nucleus	Produces oxytocin (involved in childbirth, lactation, orgasm); controls posterior pituitary
	Posterior nucleus	Functions with periaqueductal gray matter of midbrain in emotional, cardiovascular, and pain control
	Preoptic nucleus	Hormonal control of reproductive functions
	Suprachiasmatic nucleus	Biological clock; regulates circadian rhythms and female reproductive cycle
	Supraoptic nucleus	Produces antidiuretic hormone (involved in water balance); controls posterior pituitary
	Ventromedial nucleus	Satiety center (suppresses hunger)

The epithalamus is composed of the pineal gland, the habenula (a relay from the limbic system to the midbrain), and a thin roof over the third ventricle.



The Cerebrum

The largest and most conspicuous part of the human brain. Voluntary motor control and our most distinctly human mental processes. The cerebrum consists of two **cerebral hemispheres**, separated by the longitudinal fissure but connected by a prominent fiber tract, the **corpus callosum**; and the conspicuous wrinkles, or gyri, of each hemisphere, separated by grooves called sulci.

Certain unusually prominent sulci divide each hemisphere into five anatomically and functionally distinct lobes. It is difficult to summarize the functions of the cerebral lobes in any simple way; many functions such as vision, memory, speech, and emotion are distributed over multiple lobes, and different lobes contribute only part of the overall function.

Five lobes of the cerebrum

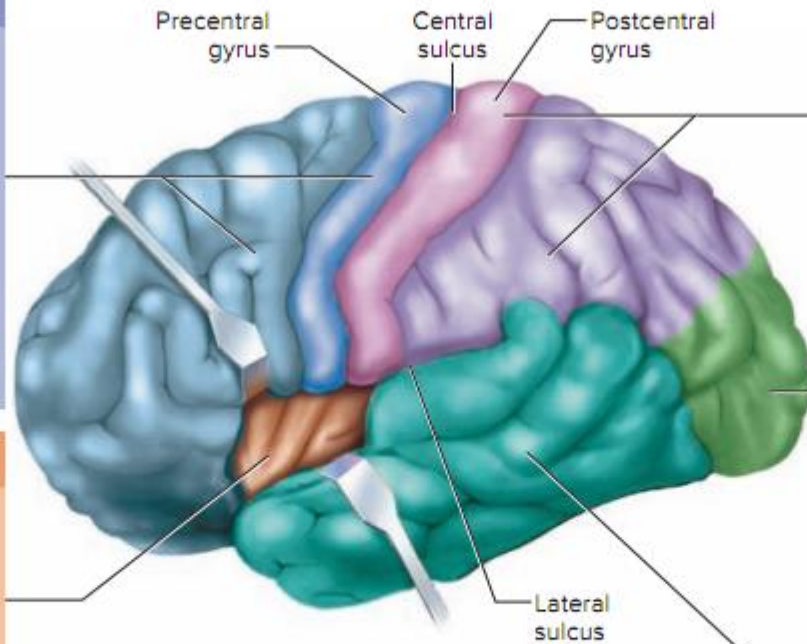
1. The **frontal** lobe lies immediately behind the frontal bone, superior to the eyes. From the forehead, it extends caudally to a wavy vertical groove, the central sulcus.
2. The **parietal** lobe forms the uppermost part of the brain and underlies the parietal bone. Starting at the central sulcus, it extends caudally to the parieto–occipital sulcus, visible on the medial surface of each hemisphere.
3. The **occipital** lobe is at the rear of the head, caudal to the parieto–occipital sulcus and underlying the occipital bone.
4. The **temporal** lobe is a lateral, horizontal lobe deep to the temporal bone, separated from the frontal and parietal lobes above it by a deep lateral sulcus.
5. The **insula** is a small mass of cortex deep to the lateral sulcus, made visible only by retracting or cutting away some of the overlying cerebrum.

Frontal lobe

- Abstract thought
- Explicit memory
- Mood
- Motivation
- Foresight and planning
- Decision making
- Emotional control
- Social judgment
- Voluntary motor control
- Speech production

Insula

- Taste
- Pain
- Visceral sensation
- Consciousness
- Emotion and empathy
- Cardiovascular homeostasis



Parietal lobe

- Taste
- Somatic sensation
- Sensory integration
- Visual processing
- Spatial perception
- Language processing
- Numerical awareness

Occipital lobe

- Visual awareness
- Visual processing

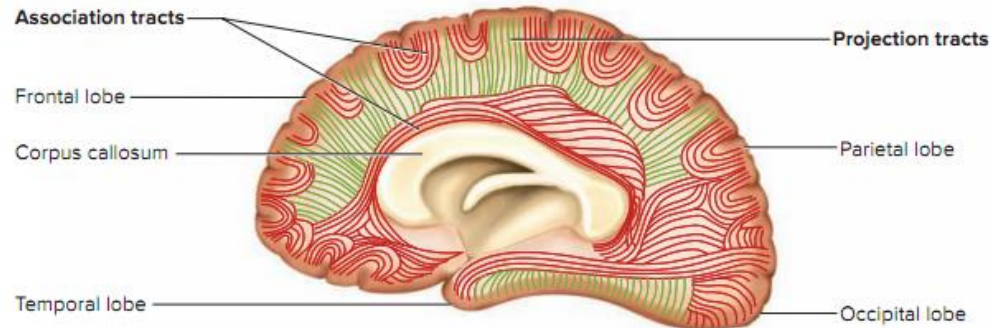
Temporal lobe

- Hearing
- Smell
- Emotion
- Learning
- Language comprehension
- Memory consolidation
- Verbal memory
- Visual and auditory memory
- Language

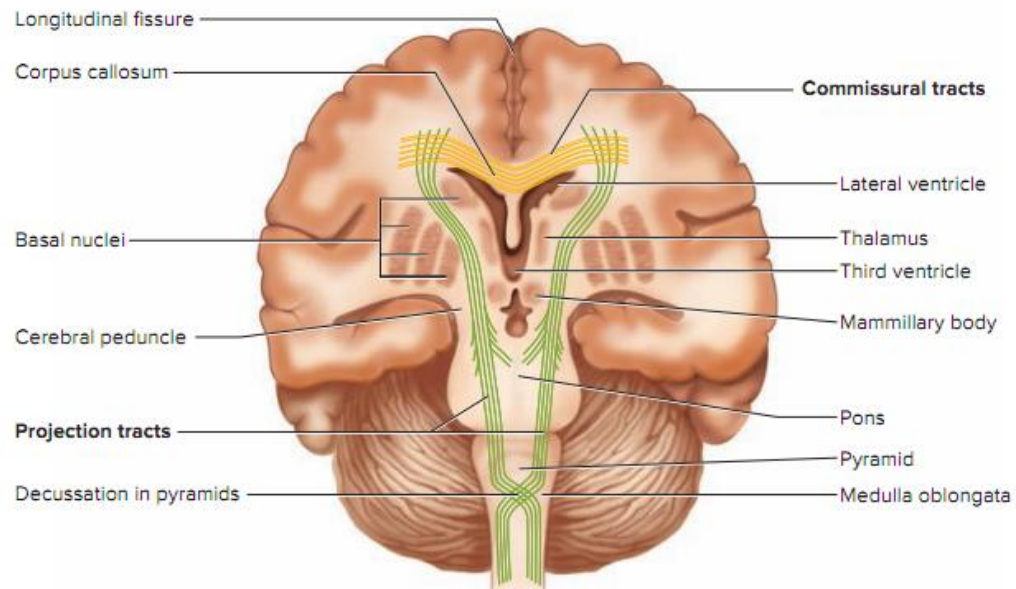
The Cerebral White Matter

Most of the volume of the cerebrum. Composed of glia and myelinated nerve fibers that transmit signals from one region of the cerebrum to another and between the cerebrum and lower brain centers. Three kinds:

1. **Projection tracts** extend vertically between higher and lower brain and spinal cord centers. For example, from the cerebrum to the brainstem and spinal cord, upward to the cerebral cortex, between the thalamus and basal nuclei then to specific areas of the cortex.
2. **Commissural tracts** cross from one cerebral hemisphere to the other through bridges called commissures. The great majority of commissural tracts pass through the large corpus callosum. Commissural tracts enable the two sides of the cerebrum to communicate with each other.
3. **Association tracts** connect different regions within the same cerebral hemisphere. Long association fibers connect different lobes of a hemisphere to each other, whereas short association fibers connect different gyri within a single lobe.



(a) Sagittal section

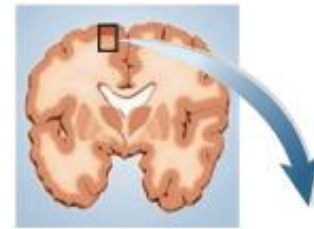


The Cerebral Cortex

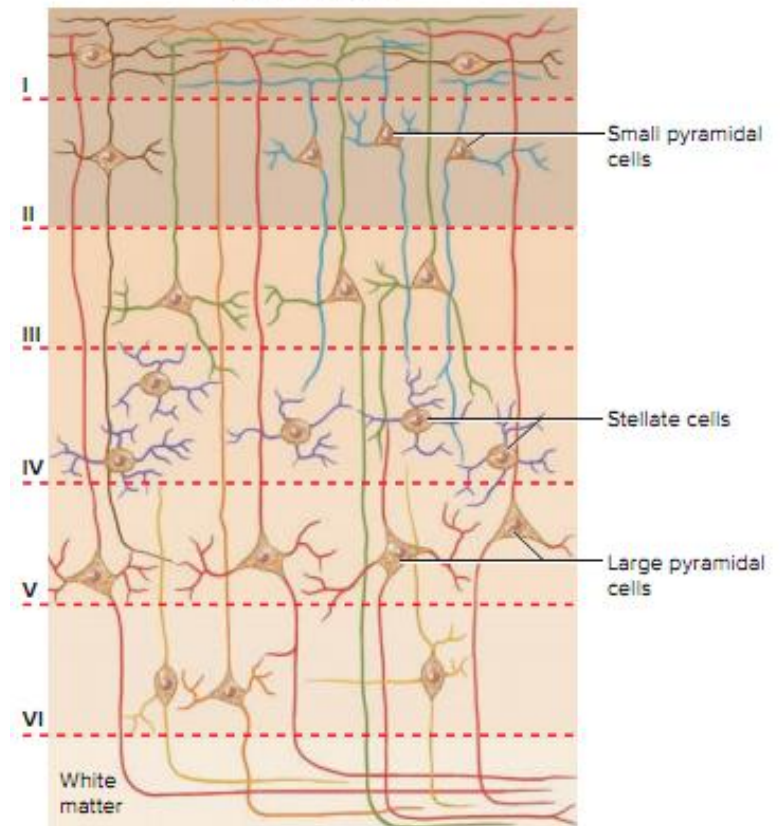
Neural integration is carried out in the gray matter of the cerebrum, which is found in three places: the cerebral cortex, basal nuclei, and limbic system. The cerebral cortex, a layer covering the surface of the hemispheres.

2 to 3 mm thick, constitutes about 40% of the mass of the brain and contains 14 to 16 billion neurons.

It possesses two principal types of neurons - **stellate** cells and **pyramidal** cells. Stellate cells have spheroidal somas with short axons and dendrites projecting in all directions. Pyramidal cells are tall and conical. Their apex points toward the brain surface and has a thick dendrite with many branches and small, knobby dendritic spines. Pyramidal cell axons have collaterals that synapse with other neurons in the cortex or in deeper regions of the brain.



Cortical surface

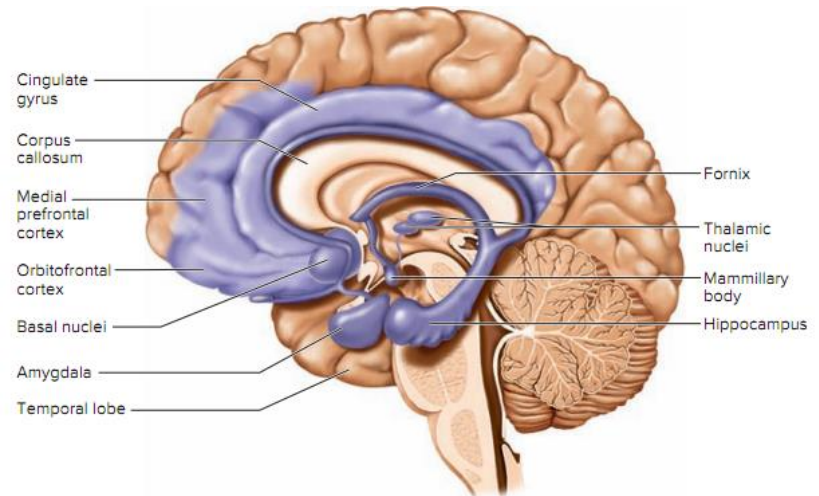


The Limbic System

Center of emotion and learning. It is a ring of cortex on the medial side of each hemisphere, encircling the corpus callosum and thalamus. Its components:

cingulate gyrus, arches over the top of the corpus callosum in the frontal and parietal lobes;

the **hippocampus** in the medial temporal lobe; the **amygdala** immediately rostral to the hippocampus, also in the temporal lobe.



Other components (bilaterally paired) - the mammillary bodies and other hypothalamic nuclei, some thalamic nuclei, parts of the basal nuclei, and parts of the frontal lobe called prefrontal and orbitofrontal cortex.

The Basal Nuclei

The basal nuclei are masses of cerebral gray matter buried deep in the white matter, lateral to the thalamus. The putamen and globus pallidus together are also called the lentiform nucleus, because they form a lens-shaped body. They are involved in motor control and are further discussed in a later section on that topic.

